

Www.Fcpsworld.com (Institute for Fcps & Md/Ms)

www.facebook.com/FcpsWorld

For Complete List of Papers Visit our website <https://fcpsworld.com/fcps-pastpapers>



www.FCPSWORLD.com

GoldStandard Papers (FCPS-1)

Gynae & Obs

16 August 2022 (Evening)

Recent Past Papers

www.facebook.com/fcpsworld

- ✓ Clear FCPS-1 in **FIRST ATTEMPT**
- ✓ Entire course will be completed in 2 months.
- ✓ Live lectures via video Portal
- ✓ Daily Test session (Test discussion will be on Via Portal)
- ✓ Follow our complete guideline for FCPS-1
- ✓ Get Hands on 20,000 CPSP question (most of them repeat)
- ✓ Free study material, [whatsapp](#) group (only for our students)
- ✓ Don't Miss the chance. (LIMITED SEATS AVAILABLE.)
- ✓ WWW.FCPSWORLD.com
- ✓ WWW.facebook.com/fcpsworld
- ✓ For Details Phone# 03129684658

(Errors and omissions excepted)



- ✓ Now you can join our Online classes for MD/MS & Fcps Preparation
- ✓ Complete course in 2months including Past paper discussion
- ✓ Join from anywhere using mobile/laptop using internet
- ✓ 100% feasible with job and 100% time adjustment for students
- ✓ www.fcpsworld.com or Contact 03129684658
- ✓ Hostel Facility is also available (for those who want to join physical classes)



FCPS-1 November-22 Revision Course

- FCPS November-22 **GUESS Papers** with quick system revision!
- MCQs From 2009 to August-2022 (12 Years past papers system wise)
- Each System covered in Each Day!
- GET **PDF** of Recent **August-22 Papers**
- Quick Review of Theory (HIGH YIELD) with Pastpaper discussion.
- Live **interactive** classes (questions can be asked during class)
- Time: 9:30pm
- Class duration: 2.5 Hrs Daily

Starting Date: 3rd November

Fee: 1200rs

Seats: 20 Only*

Topic 1	CVS SYSTEM
Topic 2	RESPIRATORY SYSTEM
Topic 3	RENAL SYSTEM
Topic 4	ENDOCRINE
Topic 5	RENAL SYSTEM
Topic 6	GIT SYSTEM
Topic 7	HEMATOLOGY
Topic 8	NEUROANATOMY

Past Papers Included

Medicine & Allied 15 th August (Night)
Medicine & Allied 16 th August (Evening)
Medicine & Allied 16 th August (Night)
Medicine & Allied 17 th August (Morning)
Medicine & Allied 17 th August (Evening)
Pathology 15 th August (Morning)
Anesthesia 15 th August (Morning)
Radiology 15 th August (Evening)
Surgery & Allied 16 th August (Evening)
Surgery & Allied 16 th August (Evening)
Surgery & Allied 15 th August (Night)
Gynae 16 th August (Morning)
Gynae 16 th August (Evening)

www.FCPSWORLD.com



- ✓ Now you can join our Online classes for MD/MS & Fcps Preparation
- ✓ Complete course in 2months including Past paper discussion
- ✓ Join from anywhere using mobile/laptop using internet
- ✓ 100% feasible with job and 100% time adjustment for students
- ✓ www.fcpsworld.com or Contact 03129684658
- ✓ Hostel Facility is also available (for those who want to join physical classes)



Join Revision Course Live interactive session starting from 2st November 2022 and clear exam in 1st Attempt in just 1200rs

Register at www.fcpsworld.com/register

Join whatsapp group <http://fcpsworld.com/revision-course/>

- thick loops and less mesentery , long vasarecta. Structure is----->Jejunum
- Nifedipine causes refractory hypotension when given with halothane due to----->synergetic effect on calcium channels
- automobile accident & suffers a fracture of left 10 & 11th ribs. organs is most likely to have been injured----->Spleen
- Pain and temperature transmitted by ?----->Lateral spinothalamic
- Patient presents with pain in lumbar region. Stone at pelvico ureteric junction. Pain arising from which segment?-----> T12-L2
- **Join Last Min Revision Live interactive session starting from 2st November 2022 and clear exam in 1st Attempt in just 1200rs**
- Register at www.fcpsworld.com/register
- Join whatsapp group <http://fcpsworld.com/revision-course/>
- Chronic bronchitis diagnostic feature histologically:----->Hypertrophy and hyperplasia of mucus- a secreting glands
- internal Urethral Sphincter's nerve supply ----->Hypogstric nerves
- Heart and uterine smooth muscles have which receptors----->Alpha 1 Beta 1
- defence against viral cells----->Natural killer cells
- At LI level on CT scan shows structure?-----> SMA origin from aorta
- not a Nonlactose fermenting bacteria----->E.coli
- Blood supply to uterus is from:-----> Ovarian -----> Uterine artery
- During hysterectomy ureter damage during ligation of which vessel?-----> Uterine artery
- ----->
- stomatitis,Angular Cheilosis. Dx defi of----->Riboflavin (B2)
- Alpha motor neuron are----->Myelinated
- Main support of uterus is:-----> Transverse cervical ligament
- Liver is attached to lesser curvature by ligament?-----> Hepatogastric



- ✓ Now you can join our Online classes for MD/MS & Fcps Preparation
- ✓ Complete course in 2months including Past paper discussion
- ✓ Join from anywhere using mobile/laptop using internet
- ✓ 100% feasible with job and 100% time adjustment for students
- ✓ www.fcpsworld.com or Contact 03129684658
- ✓ Hostel Facility is also available (for those who want to join physical classes)



- Anatomical largest zone of prostate:-----> Periheral
- **Join Last Min Revision Live interactive session starting from 2st November 2022 and clear exam in 1st Attempt in just 1200rs**
- Register at www.fcpsworld.com/register
- Join whatsapp group <http://fcpsworld.com/revision-course/>
- Partial mole karyotype?----->69 XXX
- An Old patient presents with enlarged prostate and there is marked increase in PSA upto 20ng/ml having weight loss MRI done and bony metastasis observed. What is the route of spread of prostate CA to vertebrae?-----> Vertebral venous plexus
- fascicle. of skeletal muscle are surrounded by----->Perimysium
- cause mutation of proto oncogens----->Ionizing radiations
- Chi square use to measure----->Statistical analysis
- Failure rate of Intrauterine Contraceptive Device----->< 1%
- Gestational sac is another term for?----->Amniotic Sac
- In which blood group No blood Agglutinins are present----->AB----->
- Left supra renal gland:-----> Drains in left renal vein
- **Join Last Min Revision Live interactive session starting from 2st November 2022 and clear exam in 1st Attempt in just 1200rs**
- Register at www.fcpsworld.com/register
- Join whatsapp group <http://fcpsworld.com/revision-course/>
- Best for studying cause of rare diseases----->Case control
- Purple striae on abdomen.dx----->Cushing syndrome
- most common cause of toxic shock syndrome?----->MRSA (straph aureus)
- A lady had obstructed labor for 2 days, LSCS done, folly passed for 14 days, urine started leaking after 10 days, what could be the cause?-----> Vesico vaginal fistula
- Tamoxifen MOA----->Block E2 receptor
- Explicit memory does not depend on----->Hypothalamus
- Baby prefer feeder instead of mother breast feed.----->Cleft palate
- Acute myocardial infarction changes on ECG?----->ST-segment elevation
- Vein dilated in portal hypertension:-----> Superior rectal
- Tunica vaginalis is derived from ?-----> Parietal Peritoneum
- Thorn prick lead to abcess formation would be caused by----->S. aureus



- ✓ Now you can join our Online classes for MD/MS & Fcps Preparation
- ✓ Complete course in 2months including Past paper discussion
- ✓ Join from anywhere using mobile/laptop using internet
- ✓ 100% feasible with job and 100% time adjustment for students
- ✓ www.fcpsworld.com or Contact 03129684658
- ✓ Hostel Facility is also available (for those who want to join physical classes)



- Lateral side of the foot of baby firmly stroked with sharp needle will result in----->Dorsiflexion
- Patient had RTA & fracture of ilium & sacrum. Which structure is likely to get damaged in pelvis?-----> Rectum
- Which structure has Intra pelvic extra pelvic extension?-----> Round ligament of uterus
- structure lies in the deep perineal pouch:----->Bulbourethral gland
- occur in Extreme sympathetic stimulation ?----->Bronchodilation
- Intramembranous Subendothelial deposits are seen in----->Hepatitis B
- Extensive Lesions in the cerebrum with involvement of Broca's and Wernicke's area is called?-----> Transcortical Aphasia
- A boy fell off from his cycle while riding, complain that he is unable to pass urine. Which structure has likely been damaged?----->Urethra
- **Join Last Min Revision Live interactive session starting from 2nd November 2022 and clear exam in 1st Attempt in just 1200rs**
- Register at www.fcpsworld.com/register
- Join whatsapp group <http://fcpsworld.com/revision-course/>
- The true positive is related to?----->Sensitivity
- Lateral relation of lower part of vagina----->Urogenital diaphragm
- had hysterectomy for uterine fibroids. She develops right lumbar pain within 48 hours of surgery. structure was most likely ligated----->Ureter
- hepatoma develops dependent edema with dilated abdominal wall veins. The most likely structure involved in this patient is:----->Inferior vena cava
- Injury Above sacral spinal cord will result in----->Neurogenic bladder
- Posterior relation of First part of duodenum is:----->Gastrodeodenal artery
- Aspirin should be stopped before surgery.----->7-9 days
- Which thing in salivary mucus incorporate microorganisms:----->Lysozyme
- moonfacies, hypertension and osteoporosis. Other finding would be----->Increase blood glucose
- Anterior to left suprarenal gland is:-----> Lesser sac
- Hyperexcitability of neurons due to low serum----->Ca
- Loop behind anorectal Junction----->Puborectalis



- ✓ Now you can join our Online classes for MD/MS & Fcps Preparation
- ✓ Complete course in 2 months including Past paper discussion
- ✓ Join from anywhere using mobile/laptop using internet
- ✓ 100% feasible with job and 100% time adjustment for students
- ✓ www.fcpsworld.com or Contact 03129684658
- ✓ Hostel Facility is also available (for those who want to join physical classes)



- lumbosacral swelling containing meninges without neural tissue dx----->Spina Bifida with meningocele
- shortest pre-erythrocytic phase?----->Plasmodium Falciparum
- **Join Last Min Revision Live interactive session starting from 2st November 2022 and clear exam in 1st Attempt in just 1200rs**
- Register at www.fcpsworld.com/register
- Join whatsapp group <http://fcpsworld.com/revision-course/>
- Regarding Opsonin----->Fe portion of igG and C3b
- Lymphatic spread of right testicular CA to which of following?-----> Right aortocaval nodes
- In Nephrogenic diabetes, what will occur?----->ECF osmolality increase
- ----->
- Tearing of the pelvic diaphragm during childbirth leads to the paralysis of muscles?----->Levatorani
- ----->
- Cushing syndrom will show high cortisol and ----->low ACTH level
- combination is correct:----->Ketamine causes bronchodilation
- The Blood supply of uterus is ?----->Ovarian -----> uterine artery
- **Join Last Min Revision Live interactive session starting from 2st November 2022 and clear exam in 1st Attempt in just 1200rs**
- Register at www.fcpsworld.com/register
- Join whatsapp group <http://fcpsworld.com/revision-course/>
- in looking right and left which joint is responsible----->Pivot joint
- In pregnancy iron requirement in lady?----->1200mg
- Squamous papilloma Is caused by?----->Human Papilloma Virus
- biopsy show portal vein hepatic artery and bile duct at periphery and central vein in the centre. Structure is----->Hepatic lobule
- Lipoprotein secreted by liver directly drain into?----->Space of Disse
- The uterine artery is a branch of ?----->Internal iliac artery
- Gun shot result in hemiplegia. Sensation loss will be----->Contralateral loss of pain & temperature below level
- Sentinel biopsy of axillary lymph node ina suspected breast cancer case is done to:----->Avoid the axillary dissection
- Purple striae on abdomen is characteristic of----->Cushing syndrome



- ✓ Now you can join our Online classes for MD/MS & Fcps Preparation
- ✓ Complete course in 2months including Past paper discussion
- ✓ Join from anywhere using mobile/laptop using internet
- ✓ 100% feasible with job and 100% time adjustment for students
- ✓ www.fcpsworld.com or Contact 03129684658
- ✓ Hostel Facility is also available (for those who want to join physical classes)



- Which one is largest lobe of prostate?-----> Lateral
- below hymen boil on Labia, group of lymph nodes involved:-----> Medial group
Horizontal superficial inguinal LN
- office working lady has joined a group of intellectuals and started smoking. What tests would you order to do her evaluation----->Urine screening
- Diagnostic criteria for sarcoma----->Increase vascularity AND mitotic figure
- Internal body environment is mainly maintained by?----->Negative feedback
- lymphatic obstruction can be seen in----->Infection and neoplasia
- hypertelorism with oblique palpebral fissure and ectropion on eyelid----->Crouzon syndrome
- Penile erection is caused by receptors----->Muscarinic cholinergic
- **Join Last Min Revision Live interactive session starting from 2st November 2022 and clear exam in 1st Attempt in just 1200rs**
- Register at www.fcpsworld.com/register
- Join whatsapp group <http://fcpsworld.com/revision-course/>
- Gram Negative motile rod shaped organism found that form lactose fermenting pink colony on MacConkey agar. ----->Ecoli
- arches over the root of left lung:----->Arch of aorta
- Aspirin inhibiting platelets aggregation by blocking pathway----->Thromboxain A2 Pathway
- Best route to give immediate antidote to drug----->IV
- maximum amount of blood?----->Vein
- High output cardiac failure occurs in----->Thiamine
- Adjacent spinous process of sacrum fuses to form:-----> Median sacral crest
- KF and jaundice is present. Next test----->Ceruleplasmin
- primary amenorrhea, short blind vagina scanty pubic hair, normal breasts absent uterus. karyotype will be----->46XY
- Vessel of the base of the Bladder lie in which ligament----->Dorsolateral
- Person has diarrhea for 1 week with fever and abdominal tenderness. After few days developed blood in stool. ----->Entameoba histolytica
- lobal Infectious cause of blindness is ?----->Chlamydia trachomatis



- ✓ Now you can join our Online classes for MD/MS & Fcps Preparation
- ✓ Complete course in 2months including Past paper discussion
- ✓ Join from anywhere using mobile/laptop using internet
- ✓ 100% feasible with job and 100% time adjustment for students
- ✓ www.fcpsworld.com or Contact 03129684658
- ✓ Hostel Facility is also available (for those who want to join physical classes)



- The part of the sperm containing proteolytic enzymes to digest the zona pellucida is?----->Acrosome
- NSAID most safe in lactation is----->Ibuprofen
-
- **Join Last Min Revision Live interactive session starting from 2st November 2022 and clear exam in 1st Attempt in just 1200rs**
- Register at www.fcpsworld.com/register
- Join whatsapp group <http://fcpsworld.com/revision-course/>



▪ **Almost every student who joins our Online Classes**

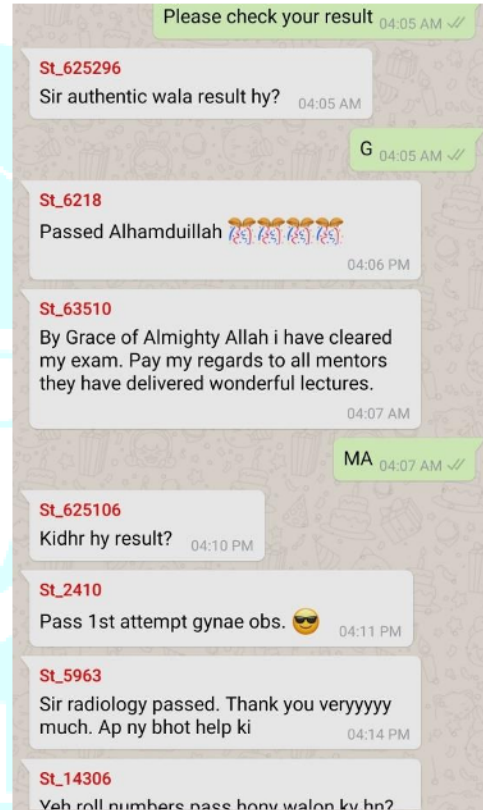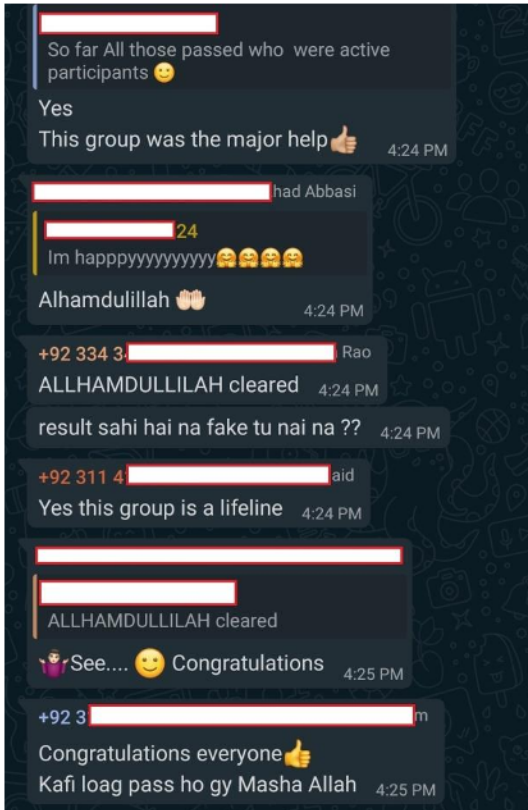
Passes exam (Alhamduillah)



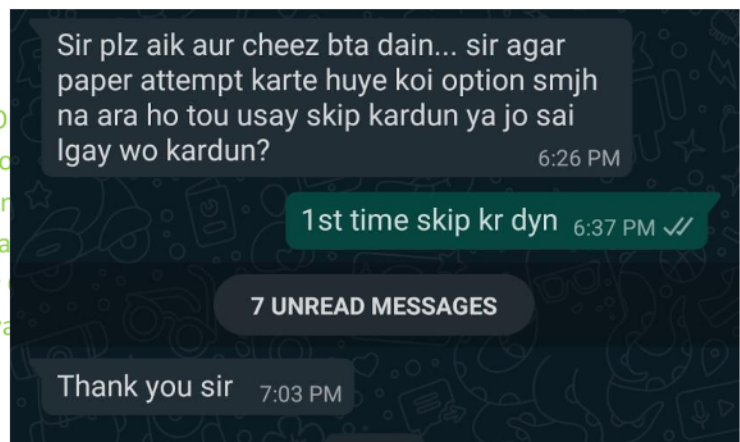
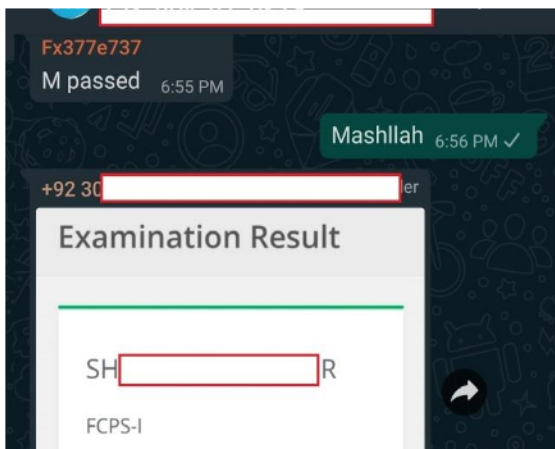
- ✓ Now you can join our Online classes for MD/MS & Fcps Preparation
- ✓ Complete course in 2months including Past paper discussion
- ✓ Join from anywhere using mobile/laptop using internet
- ✓ 100% feasible with job and 100% time adjustment for students
- ✓ www.fcpsworld.com or Contact 03129684658
- ✓ Hostel Facility is also available (for those who want to join physical classes)



- Join FCPSWORLD Online Classes and clear your 100% concepts. Our lectures presentations are extract of past papers and consist on
 - FirstAid, BRS, snell anatomy, kaplan neuroanatomy etc.



Many More Success Stories



Www.Fcpsworld.com (Institute for Fcps & Md/Ms)

www.facebook.com/FcpsWorld

For Complete List of Papers Visit our website <https://fcpsworld.com/fcps-pastpapers>

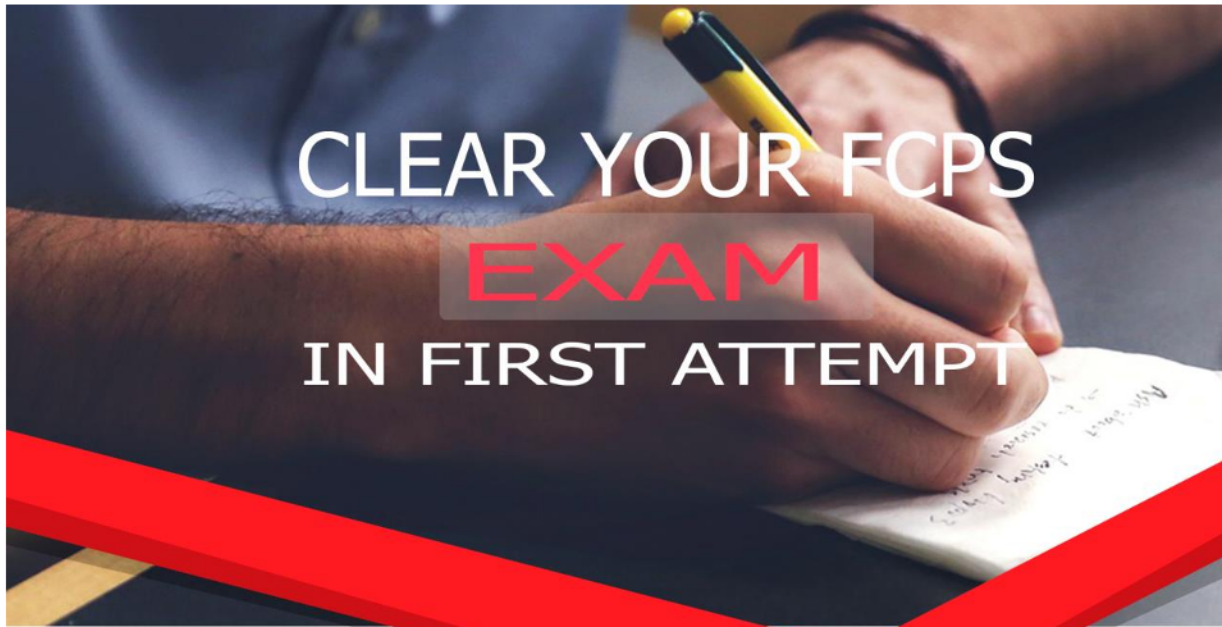

- ✓ Now you can join our Online classes for MD/MS & Fcps Preparation
- ✓ Complete course in 2months including Past paper discussion
- ✓ Join from anywhere using mobile/laptop using internet
- ✓ 100% feasible with job and 100% time adjustment for students
- ✓ www.fcpsworld.com or Contact 03129684658
- ✓ Hostel Facility is also available (for those who want to join physical classes)

Www.Fcpsworld.com (Institute for Fcps & Md/Ms)

www.facebook.com/FcpsWorld

For Complete List of Papers Visit our website <https://fcpsworld.com/fcps-pastpapers>



FCPS-1 NOVEMBER-2022

REVISION COURSE

LAST DAYS EXCLUSIVE

REGISTER NOW!

20* SEATS ONLY

FULL SYSTEM REVIEWS

Aug-22 PAST PAPERS

Nov-22 GUESS PAPERS

11 YEAR PAST-PAPER DISC.

Online Interactive Classes

STARTING: 2nd Nov-22



FEE RS 1200 ONLY

[WWW.FCPSWORLD.COM/REGISTER](https://www.fcpsworld.com/register)



CALL US NOW

+92 312 9684658



SURGERY & ALLIED | MEDICINE & ALLIED
| GYNAE OBS | ENT | PATHOLOGY | RADIOLOGY
| OPTH | ANESTHESIA | DENTISTRY | PSY

Hostel facility is also available for those who want to join physical classes

Www.Fcpsworld.com (Institute for Fcps & Md/Ms)

www.facebook.com/FcpsWorld

For Complete List of Papers Visit our website <https://fcpsworld.com/fcps-pastpapers>



& Many More Success Stories

FCPS-1 ONLINE COURSE

Join FcpsWorld Online preparation courses and clear exam in 1st Attempt.

WWW.FCPSWORLD.COM



Fcpsworld



www.fcpsworld.com



- ✓ Now you can join our Online classes for MD/MS & Fcps Preparation
- ✓ Complete course in 2months including Past paper discussion
- ✓ Join from anywhere using mobile/laptop using internet
- ✓ 100% feasible with job and 100% time adjustment for students
- ✓ www.fcpsworld.com or Contact 03129684658
- ✓ Hostel Facility is also available (for those who want to join physical classes)



Gold Standard FCPS (Buy 4rd edition only)

February 2022 papers
(recent updated)

Revise 11 years
pastpapers in just 11
days

Authentic most repeated
papers.

- ✓ Subject wise topic wise MCQS
- ✓ 1 liner for rapid revision. (Cram them)
- ✓ Clear FCPS---->1 in 1st Attempt (Dont miss chance)
- ✓ Free Cash on Delivery Order at

www.fcpsworld.com/order---->book



- ✓ Now you can join our Online classes for MD/MS & Fcps Preparation
- ✓ Complete course in 2months including Past paper discussion
- ✓ Join from anywhere using mobile/laptop using internet
- ✓ 100% feasible with job and 100% time adjustment for students
- ✓ www.fcpsworld.com or Contact 03129684658
- ✓ Hostel Facility is also available (for those who want to join physical classes)



GoldStandard FCPS 4th Edition V1 (Golden 13)

Table of Content

1. CVS SYSTEM	Page#5
2. ENDOCRINE SYSTEM	Page#33
3. RENAL SYSTEM	Page#69
4. RESPIRATORY SYSTEM	Page#89
5. GIT SYSTEM	Page#113
6. Hematology	Page#145
7.	
8. ANATOMY	
a. UPPER LIMB	Page#169
b. LOWER LIMB	Page#200
c. THORAX	Page#225
d. NEUROANATOMY	Page#233
e. HEAD AND NECK	Page#270
f. ABDOMEN PELVIS	Page#281
g. Histology	Page#292
h. General Anatomy	Page#294
9. PHARMACOLOGY	Page#298
10. MICROBIOLOGY	
a. Bacteriology	Page#301
b. Virology	Page#309
c. Fungi	Page#3011

NOTE:

1. MCQs should be covered in retrograde fashion
2. All students who have ordered book will receive November papers in PDF as well via whatsapp (Do them first)
3. All written in **tabular** form or in **points** form are pastpapers
4. Each and every word from this book is from pastpapers (Except UPPER/LOWER LIMBS that has bit of explanation)
5. Students are highly advised to take Last Minute revision course starting in last 10 days of EXAMS (All points and systems will be covered 3 hr class daily)
Register: www.fcpsworld.com/register

If you have less time first do PDF files sent by us, then open each topic just CRAM TABULAR PASTPAPERS, then open each system and cram MISC 2019-2021 papers of all systems after completing those start MISC 2009-2021 of from system one.

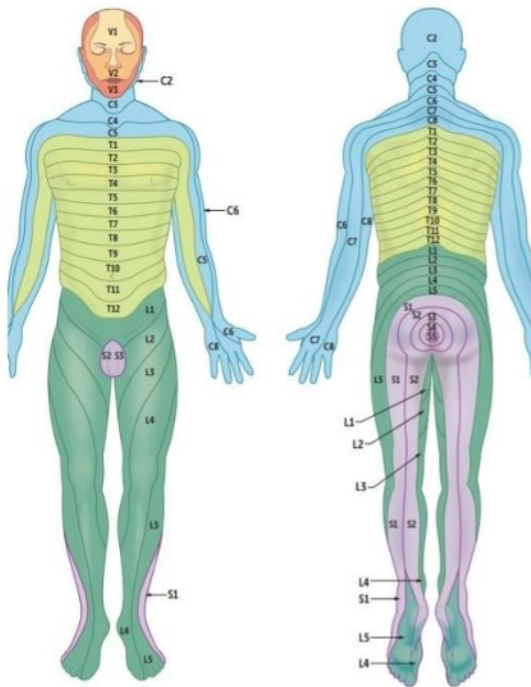




GoldStandard FCPS 4th Edition V1 (Golden 13)

- Superficial fascia of the scalp is mixture of → Loose areolar and adipose tissue
- The axillary sheath is a continuation of → Prevertebral fascia
- Thyroid gland moves with swallowing because it is enclosed in → Pretracheal fascia
- Trauma to one kidney without the perforation of Gerota fascia, the blood goes to → Inferiorly to the pelvis
- True regarding the posterior triangle of neck is → Roof formed by investing layer of deep cervical fascia

DERMATOMES



C2	Posterior half of skull
C3	High turtleneck shirt Diaphragm and gallbladder pain referred to the right shoulder via phrenic nerve ✓ C3, 4, 5 keeps the diaphragm alive
C4	Low-collar shirt
C6	Includes thumbs ✓ Thumbs up sign on left hand looks like
T4	✓ At the nipple ✓ T4 at the teat pore
T7	✓ At the xiphoid process 7 letters in xiphoid
T10	✓ At the umbilicus (belly button) Point of referred pain in early appendicitis
L1	✓ At the Inguinal Ligament
L4	✓ Includes the kneecaps Down on ALL 4's
S2, S3, S4	✓ Sensation of penile and anal zones S2, 3, 4 keep the penis off the floor

GREAT TOE	L4
LITTLE TOE	S1
KNEE	L4
NIPPLE	T4
UMBILICUS	T10
RING AND LITTLE FINGER	C8 RING, T1 LITTLE
THUMB	C6

anal area dermatome	s3-4
dermatome of lateral wrist	c6
dermatomy of thumb	c6

Join FcpsWorld Online Classes and Clear exam in 1st Attempt

GoldStandard FCPS 4th Edition V1 (Golden 13)

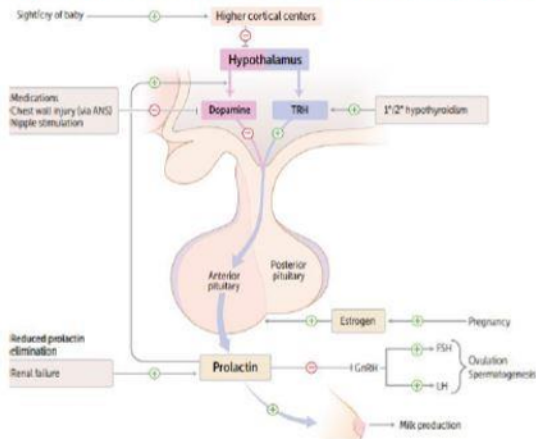
knee dermatome	l4
lower end of clavicle dermatome	c3-4
pain in calf and medial malleolus dermatome	l4





Prolactin

1. Stimulates milk production in breast; inhibits ovulation in females and spermatogenesis in males by inhibiting GnRH synthesis and release (thus LH, FSH release).
 - Hypothalamus -> Decr GnRH secretion -> Decr FSH/LH -> Decr estradiol in females, Decr testosterone in males
 - Alveolar Cells of Breast Ducts -> Milk production and release -> Lactation
 - Prolactin release dopamine which inhibits prolactin
2. Release by sucking, voice of baby
3. Prolactin secretion from anterior pituitary is tonically inhibited by dopamine Prolactin.



PAST PAPERS

Potent stimulus for prolactin release is?	Suckling reflex of baby
A 9-month pregnant presents with complaints of lactation (milky discharge). This is likely due to	Prolactin
Secretion of milk in mammary gland is due to	Prolactin
During lactation, ovulation is inhibited because of inhibition of GnRH by?	Prolactin
hormone of the anterior pituitary is under direct inhibitory control of hypothalamus?	Prolactin
During lactation, ovulation is inhibited because of inhibition of GnRH by?	Prolactin



- ✓ Now you can join our Online classes for MD/MS & Fcps Preparation
- ✓ Complete course in 2months including Past paper discussion
- ✓ Join from anywhere using mobile/laptop using internet
- ✓ 100% feasible with job and 100% time adjustment for students
- ✓ www.fcpsworld.com or Contact 03129684658
- ✓ Hostel Facility is also available (for those who want to join physical classes)



GoldStandard FCPS 4th Edition V1 (Golden 13)

ENDOCARDITIS

- Nonbacterial endocarditis is seen in → Neoplasms, hypercuaguable state
- Most common cause of death in rheumatic fever → Myocarditis
- Commonly use Tri-cuspaed valvule
- common in IV-drug users
- Libman-Sack Endocarditis occurs in → SLE
- DOC is benzethins pencilline if allergic give genta+vanco
- Correct Infective endocarditis sequence
Damage valve, Thrombus, Bacteremia, Perforation (VT-BP)

Bacterial endocarditis

Acute—*S aureus* (high virulence). Large vegetations on previously normal valves. Rapid onset.

Subacute—viridans streptococci (low virulence). Smaller vegetations on congenitally abnormal or diseased valves. Sequela of dental procedures. Gradual onset.

Tricuspid valve endocarditis is associated with IV drug use (don't "tri" drugs). Associated with *S aureus*, *Pseudomonas*, and *Candida*. *S bovis (gallolyticus)* is present in colon cancer, *S epidermidis* on prosthetic valves.

PAST PAPERS

Non thrombotic bacterial endocarditis is frequently associated with?	Terminal neoplasm
A known case of rheumatic mitrai stenosis developed fever, lassitude body ache after tooth extraction. O/E splinter haemorrhages and splenomegaly was noted Subacute endocarditis is suspected. Most likely organism on blood culture would be?	Strep viridans
Most common heart valve affected in diseases is	Tricuspid
Female pt. has valvular heart disease, such pt. are at risk of developing infective endocarditis, which organism is commonly responsible	streptococcus viridians
On Examination there are skin spots and nail bed hemorrhages on both hands & a Grade-4 Diastolic Murmur, past history is unremarkable. Patient is most likely suffering from	Infective Endocarditis
Developed fever, lassitude body ache after tooth extraction. Most likely organism on blood culture would be	Strep viridians
Infective endocarditis Patient is allergic to penicillin give medication	Vancomycin + gentamicin
School teacher who after death was diagnosed as a case of endocarditis and lymphocytic infiltration of cardiac tissues	Coxsackie virus



- ✓ Now you can join our Online classes for MD/MS & Fcps Preparation
- ✓ Complete course in 2months including Past paper discussion
- ✓ Join from anywhere using mobile/laptop using internet
- ✓ 100% feasible with job and 100% time adjustment for students
- ✓ www.fcpsworld.com or Contact 03129684658
- ✓ Hostel Facility is also available (for those who want to join physical classes)



GoldStandard FCPS 4th Edition V1 (Golden 13)

True about CSF	Slightly acidic than plasma
----------------	-----------------------------

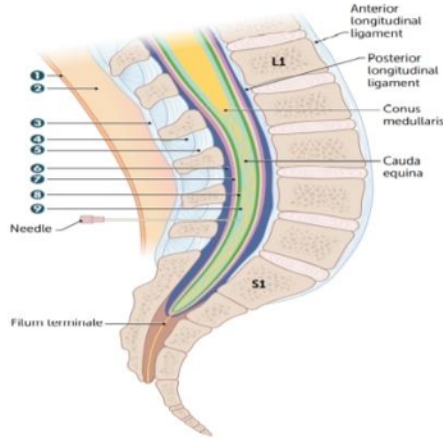
LUMBAR PUNCTURE

In adults, spinal cord ends at lower border of L1-L2 vertebrae. Subarachnoid space (which contains the CSF) extends to lower border of S2 vertebra. Lumbar puncture is usually performed between L3-L4 or L4-L5 (level of cauda equina).

Goal of lumbar puncture is to obtain sample of CSF without damaging spinal cord. To **keep** the cord **alive**, keep the spinal needle between **L3 and L5**.

Needle passes through:

- 1 skin
- 2 fascia and fat
- 3 supraspinous ligament
- 4 interspinous ligament
- 5 ligamentum flavum
- 6 epidural space (epidural anesthesia needle stops here)
- 7 dura mater
- 8 arachnoid mater
- 9 subarachnoid space (CSF collection occurs here)



Past papers

During LP after crossing flavum at L3, L4 the needle touches which structure first	Epidural space
Ideal site for lumbar puncture is	Below L4
Regarding Epidural space extension	Foramen magnum to S2
Site of Epidural anaesthesia for patient undergoing Vaginal hysterectomy is	Sacral hiatus
Spinal cord is suspended in dura by	Denticulate ligament
Structure most likely pierced by needle during lumbar puncture is	Ligamentum flavum
Which of the following structure is pierced in paramedian approach	Ligamentum flavum
The most common site of spinal anesthesia is?	Subarachnoid
Subarachnoid space ends at the level of	S2-S3
Cauda equina:	Anterior & posterior roots of spinal cord from L1 to L5

Note:

Herniation between L4-L5 affect which spinal segment?	Lumbar
Between L4 and L5 disc herniation, which spinal nerve will be affected	L5
Herniation between L4-L5 affect which spinal segment	L4

Centers of Brain

- Vomiting centre located in → Medulla
- Cough centre is present in → medulla
- Respiratory centre located in → Medulla oblongata

Past papers

Join FcpsWorld Online Classes and Clear exam in 1st Attempt

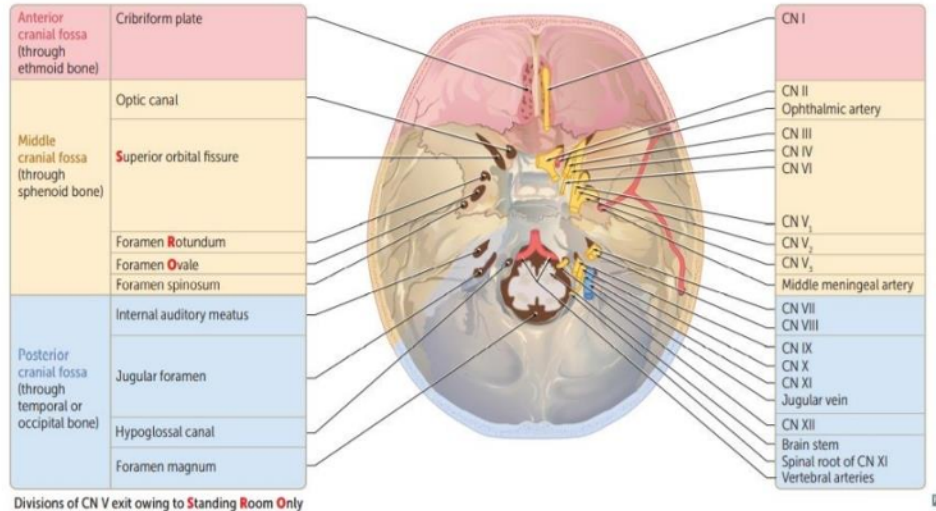




GoldStandard FCPS 4th Edition V1 (Golden 13)

HEAD AND NECK

Foramin of Skull



Anterior cranial Fossa (ethmoid bone)	Cribriform plate	CN 1
Middle Cranial Fossa (sphenoid bone)	Optic Canal	CN2 Ophthalmic artery, central retinal vein
	Superior orbital fissure	CN2,4,6 CN 5-V1
	Foramen rotundum	CN5-V2 → maxillary branch of trigeminal nerve
	Foramen ovale	CN5-V3 → mandibular branch of trigeminal nerve
	Foramen spinosum	Middle meningeal artery
Posterior Cranial Fossa (temporal or occipital bone)	Internal auditory meatus	CN7, 8
	Jugular foramen	CN 9,10,11 Jugular vein
	Hypoglossal canal	CN12
	Foramen magnum	Brain stem Spinal root of CN 12 Vertebral arteries

Pastpapers

270/314



Accessory meningeal artery enters through which foremen----->Ovale
Accessory nerve passes through which foramen----->Jugular foramen
Foramen Rotundum damaged which structure will be severed----->Maxillary branch of trigeminal nerve.
Lesion below foramen Ovale causes paralysis of----->Lower part of face/Jaw
Mandibular branch of Trigeminal nerve passes through----->Foramen ovale
Middle meningeal artery in the----->Foramen Spinosum
Nerve in foramen Ovale damaged nerve supply of which part will be affected----->Lower face
Vagus nerve passes through----->jugular foramen

Join FcpsWorld Online Classes and Clear exam in 1st Attempt

270 | Page





FSH & LH

LH

Luteinizing Hormone in males acts on = Leydig cells

1. **Luteinizing** hormone acts on = **Leydig** cells to produce **Testosterone**
2. Function of LH before ovulation is=Convert most of the granulos cells into lutein cells

Join FcpsWorld Online Classes and Clear exam in 1st Attempt

GoldStandard FCPS 4th Edition V1 (Golden 13

FSH

3. **FSH** acts on =**Sertoli** cells to do **Spermatogenesis** → Related to Azoospermia
[LighT is FaSt]

 - Development of seminiferous tubules
 - Convert testosterone into estradiol
 - Helps in maturation of follicles
 - Inhibited by **INHIBIN**

Spermatogenesis is stimulated by	FSH and testosterone
LH act through:	cAMP
Hormone causing increase release of testosterone:	Luteinizing hormone
LH act on which testicular cells mostly	Leydig cells

Function of sertoli cells	help in spermiogenesis
A tall man with normal external genitalia married but no kids. Semen analysis showed azospermia. Most likely cause may be in	Sertoli cell
Sertoli cells produce	MIF (Mullerian inhibitory factor)
Married man with azospermia. Investigation of choice is	Serum FSH + LH

Function and development of seminiferous tubule requires=FSH and androgen
 Testosterone converted to estradiol by which hormone= FSH
 Conversion of testosterone to 17-beta estradiol in granulos cells occurs by the influence of= FSH

Before Ovulation maturation of follicles occur by action of FSH

Maturation of follicles Hormone responsible is FSH mainly and LH partly.

GnRH from hypothalamus release FSH and LH by pituitary

Which hormone stimulates release of FSH and LH	GnRH
During lactation, amenorrhea occurs due to	Inhibition of GnRH

The Sertoli cells also secrete inhibin Which stop FSH secretion

- ✓ Join from anywhere using mobile/laptop using internet
- ✓ 100% feasible with job and 100% time adjustment for students
- ✓ www.fcpsworld.com or Contact 03129684658
- ✓ Hostel Facility is also available (for those who want to join physical classes)

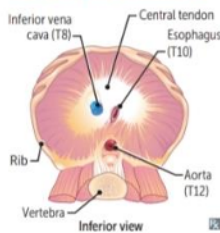




Thorax

Diaphragm

Diaphragm structures



Structures perforating diaphragm:

- At T8: IVC, right phrenic nerve
- At T10: esophagus, vagus (CN 10; 2 trunks)
- At T12: aorta (red), thoracic duct (white), azygos vein (blue) ("At T-1-2 it's the red, white, and blue")

Diaphragm is innervated by C3, 4, and 5 (phrenic nerve). Pain from diaphragm irritation (eg, air, blood, or pus in peritoneal cavity) can be referred to shoulder (C5) and trapezius ridge (C3, 4).

Number of letters = T level:

T8: vena cava (IVC)

T10: (O)esophagus

T12: aortic hiatus

I ate (8) ten eggs at twelve.

C3, 4, 5 keeps the diaphragm alive.

Other bifurcations:

- The Common Carotid bifurcates at C4.
- The Trachea bifurcates at T4.
- The abdominal aorta bifurcates at L4.

ESOPHAGUS [All are pastpapers]

Oesophagus starts at level of:	Cricoid cartilage
Esophagus narrowest at:	Cricopharyngus
Esophagus constricted at:	Where crossed by arch of aorta

Breast [All are pastpapers]

Regarding breast:	15-20 lactiferous ducts
In a female major breast duct terminate into terminal ducts from terminal ducts it forms:	Lactiferous sinus
Terminal duct in breast form:	Lobule
Breast lies on:	Pect major

LYMPHATICS OF BREAST [All are pastpapers]

Pectoral group of axillary nodes drain:	Major part of the breast
Breast CA involving lateral part of breast drain by:	Ant pectoral group
Upper lateral quadrant of breast is drained by which grp of nodes:	Anterior axillary lymph node
Lymph drainage from nipple of breast is to:	Anterior axillary nodes
Inner medial lower quadrant of breast doesnt drain into	Inf phrenic
Lymph node of inner breast drains into all except:	Inf phrenic nodes
Breast Medial / Lower compartment does not:	Inferior phrenic lymph nodes
Medial quadrant of breast drain into?	Internal thoracic nodes
Pectrol lymph nodes drain maximum:	Major part of breast
Lateral side of breast drains into:	Pectoral lymph nodes
Lateral quadrants of breast drain into which nodes?	Pectoral nodes.
Lymphatic drainage from nipple of breast is:	Ant axillary lymph node
Breast outer quadrant:	Pectoral (anterior) group



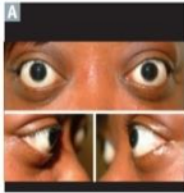

GoldStandard FCPS 4th Edition V1 (Golden 13)

Graves Disease

Hyperthyroidism

Graves disease



Most common cause of hyperthyroidism. Thyroid-stimulating immunoglobulin (IgG, can cause transient neonatal hyperthyroidism; type II hypersensitivity) stimulates TSH receptors on thyroid (hyperthyroidism, diffuse goiter), dermal fibroblasts (pretibial myxedema), and orbital fibroblasts (Graves orbitopathy). Activation of T-cells → lymphocytic infiltration of retroorbital space → ↑ cytokines (eg, TNF-α, IFN-γ) → ↑ fibroblast secretion of hydrophilic GAGs → ↑ osmotic muscle swelling, muscle inflammation, and adipocyte count → exophthalmos **A**. Often presents during stress (eg, pregnancy). Associated with HLA-DR3 and HLA-B8.

Histology: tall, crowded follicular epithelial cells; scalloped colloid.

PAST PAPERS

57/314

A pt with exophthalmos and other hyperthyroid features and positive anti-thyroid antibodies is suggestive of	Graves disease
Exophthalmus is due to:	Inc TSI
Most common cause of hyperthyroidism:	Graves disease
Hyperthyroid, goiter and exophthalmos:	Graves disease
common cause of hyperthyroidism?	Grave's disease
What will increase in graves disease	t3
Graves ophthalmopathy:	Optic nerve compression
Vitamin D deficiency is associated with Ophthalmopathy in patients with Graves' hyperthyroidism	

Key lympho, antibody

Hypothyroidism

Hashimoto thyroiditis

Also called chronic autoimmune thyroiditis. Most common cause of hypothyroidism in iodine-sufficient regions. Associated with HLA-DR3, ↑ risk of primary thyroid lymphoma (typically diffuse large B-cell lymphoma).

Findings: moderately enlarged, **nontender** thyroid. May be preceded by transient hyperthyroid state ("Hashitoxicosis") due to follicular rupture and thyroid hormone release.

Serology: ⊕ antithyroid peroxidase (antimicrosomal) and antithyroglobulin antibodies.

Histology: Hürthle cells **A**, lymphoid aggregates with germinal centers **B**.

Postpartum thyroiditis—mild, self-limited variant of Hashimoto thyroiditis arising < 1 year after delivery.

A 40-year known Hypothyroidism female was referred to endocrinologist for a mass in neck. FNAC shows increased lymphocytes and serology was advised. What is the most probable cause?	Hashimoto thyroiditis
Female with neck swelling hypothyroid dr orders some immunologic tests?	Hashimoto thyroiditis
Female swelling in front of neck. Hypothyroid Dr orders some immunological test. What is the diagnosis?	Hashimoto thyroiditis
Diagnosis for hashimotos	Antimicrosomal and anti-thyroglobulin

A 40-year known Hypothyroidism female was referred to endocrinologist for a mass in neck. FNAC shows increased lymphocytes and serology was advised. What is the most probable cause

Hashimoto

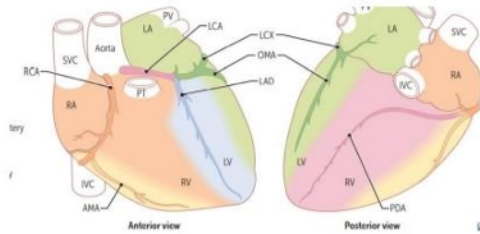


- ✓ 100% feasible with job and 100% time adjustment for students
- ✓ www.fcpsworld.com or Contact 03129684658
- ✓ Hostel Facility is also available (for those who want to join physical classes)



MI ECG LEADS

INFARCT LOCATION	LEADS WITH ST-SEGMENT ELEVATIONS OR Q WAVES
Anteroseptal (LAD)	V ₁ -V ₂
Anterolateral (distal LAD)	V ₃ -V ₄
Anterolateral (LAD or LCX)	V ₅ -V ₆
Lateral (LCX)	I, aVL
Inferior (RCA)	II, III, aVF
Posterior (PDA)	V ₇ -V ₉ , ST depression in V ₁ -V ₃ with tall R waves



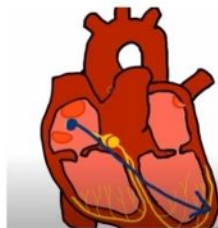
PAST PAPERS

Inferior wall MI occurs due to blockage of	Right coronary artery
Post 1/3 of interventricular septum is damaged due to MI. Artery involved is?	Right coronary artery
Inferior wall MI occurs due to blockage of which artery?	Right marginal
MI of posterolateral surface of heart. Vessel involved is	Left circumflex
ECG changes in lead V4 indicated involvement of which vessel	LAD
Infarction of apex of heart, vessel thrombosed will be	LAD
The circumflex artery supplies	Left atrium and left ventricle
Infarct in the lower segment of heart	LCX
ECG shows changes in leads II, III and avF. Diagnosis	Inferior wall MI
ST elevation in lead II, which artery involved	RCA

GoldStandard FCPS 4th Edition V1 (Golden 13)

Patient presented to ER with crushing chest pain for last 1 hour ON ECG there is ST segment elevation in lead II, III & AVF what's the diagnosis	Inferior wall MI
ST segment elevation in lead II which artery effected	right main coronary
A man presents to ER with ST depressions in II, III and avF and was advised angiography. The Most likely culprit artery is	RCA
Artery involved in inferior wall MI	Right marginal
Patient having ST elevation in Lead 2 and complete heart block vessel involved	RCA

NOTE: AXIS deviation



Left axis deviation on ECG is seen in	Rt ventricular myocardial damage
---------------------------------------	----------------------------------

- ✓ Join from anywhere using mobile/laptop using internet
- ✓ 100% feasible with job and 100% time adjustment for students
- ✓ www.fcpsworld.com or Contact 03129684658
- ✓ Hostel Facility is also available (for those who want to join physical classes)



Www.Fcpsworld.com (Institute for Fcps & Md/Ms)

www.facebook.com/FcpsWorld

For Complete List of Papers Visit our website <https://fcpsworld.com/fcps-pastpapers>



- ✓ Now you can join our Online classes for MD/MS & Fcps Preparation
- ✓ Complete course in 2months including Past paper discussion
- ✓ Join from anywhere using mobile/laptop using internet
- ✓ 100% feasible with job and 100% time adjustment for students
- ✓ www.fcpsworld.com or Contact 03129684658
- ✓ Hostel Facility is also available (for those who want to join physical classes)