

Www.Fcpsworld.com (Institute for Fcps & Md/Ms)

[www.facebook.com/FcpsWorld](https://www.facebook.com/FcpsWorld)

[www.facebook.com/GynaeObsWorld](https://www.facebook.com/GynaeObsWorld)

[www.facebook.com/Ophtworld](https://www.facebook.com/Ophtworld)



For Complete List of Papers Visit our website <https://fcpsworld.com/fcps-pastpapers>



[www.FCPSWORLD.com](http://www.FCPSWORLD.com)

## GoldStandard Papers (FCPS-1)

### Gynae & Obs

1<sup>st</sup>-December-2021 (Morning)

Recent Past Papers

[www.facebook.com/fcpsworld](https://www.facebook.com/fcpsworld)

- ✓ Clear FCPS-1 in **FIRST ATTEMPT**
- ✓ Entire course will be completed in 2 months.
- ✓ Live lectures via video Portal
- ✓ Daily Test session (Test discussion will be on Via Portal)
- ✓ Follow our complete guideline for FCPS-1
- ✓ Get Hands on 20,000 CPSP question (most of them repeat)
- ✓ Free study material, whatsapp group (only for our students)
- ✓ Don't Miss the chance. **(LIMITED SEATS AVAILABLE.)**
- ✓ [WWW.FCPSWORLD.com](http://WWW.FCPSWORLD.com)
- ✓ [WWW.facebook.com/fcpsworld](https://WWW.facebook.com/fcpsworld)
- ✓ For Details Phone# 03129684658



- ✓ Now you can join our Online classes for MD/MS & Fcps Preparation
- ✓ Complete course in 2months including Past paper discussion
- ✓ Join from anywhere using mobile/laptop using internet
- ✓ 100% feasible with job and 100% time adjustment for students
- ✓ [www.fcpsworld.com](http://www.fcpsworld.com) or Contact 03129684658
- ✓ Hostel Facility is also available (for those who want to join physical classes)

Www.Fcpsworld.com (Institute for Fcps & Md/Ms)

[www.facebook.com/FcpsWorld](http://www.facebook.com/FcpsWorld)

[www.facebook.com/GynaeObsWorld](http://www.facebook.com/GynaeObsWorld)

[www.facebook.com/Ophtworld](http://www.facebook.com/Ophtworld)



For Complete List of Papers Visit our website <https://fcpsworld.com/fcps-pastpapers>

(Errors and omissions excepted)

**FCPS-1 NOVEMBER Papers will Be uploaded on  
Our website [www.fcpsworld.com](http://www.fcpsworld.com) (keep visiting)**

Medicine & Allied 1 <sup>st</sup> December Afternoon
Medicine & Allied 1 <sup>st</sup> December Night
Medicine & Allied 2 <sup>nd</sup> December Morning
Medicine & Allied 2 <sup>nd</sup> December Afternoon
Medicine & Allied 2 <sup>nd</sup> December Night
Surgery & Allied 30 <sup>th</sup> November Afternoon
Surgery & Allied 30 <sup>th</sup> November Night
Surgery & Allied 1 <sup>st</sup> December Morning
Radiology 30 <sup>th</sup> November Morning
Radiology 30 <sup>th</sup> November Night
Anesthesia 30 <sup>th</sup> December Morning
OBG 1 <sup>st</sup> December Morning
OBG 1 <sup>st</sup> December Afternoon
OBG 2 <sup>nd</sup> December Night
Opthmology November 2022
Dentistry November 2022



- ✓ Now you can join our Online classes for MD/MS & Fcps Preparation
- ✓ Complete course in 2months including Past paper discussion
- ✓ Join from anywhere using mobile/laptop using internet
- ✓ 100% feasible with job and 100% time adjustment for students
- ✓ [www.fcpsworld.com](http://www.fcpsworld.com) or Contact 03129684658
- ✓ Hostel Facility is also available (for those who want to join physical classes)



For Complete List of Papers Visit our website <https://fcpsworld.com/fcps-pastpapers>

**Join Last Min Revision Live interactive session starting from 4<sup>th</sup> of February 2022 and clear exam in 1st Attempt in just 1200rs**

Register at [www.fcpsworld.com/register](http://www.fcpsworld.com/register) (8 day Session all systems)

**Gynae & Obs 1<sup>st</sup> december Morning [www.fcpsworld.com](http://www.fcpsworld.com)**

- cause direct vascular injury in septic shock-----> TNF
- Drug used for rapid intubation if succinylcholine is contraindicated-----> Rocuronium
- JOIN FCPSWORLD ONLINE CLASSES & CLEAR EXAM IN 1<sup>ST</sup> ATTEMPT
- pt with acute appendicitis pain and fever for last 24h on pathological examination seen-----> Neutrophil in muscular wall
- Normal physiological parameters of blood components or cells are-----> 45%Blood cells and 55%plasma
- pt came with Multiple sclerosis sign and symptoms now present with bed wetting which drug to give-----> Oxybutynin
- dr performing surgery removed the anterior part of pituitary gland accidentally what will happen-----> Absence of menses
- JOIN FCPSWORLD ONLINE CLASSES & CLEAR EXAM IN 1<sup>ST</sup> ATTEMPT
- Initiation of labor can be inhibited by giving-----> Prostaglandin E2 antagonist
- Right ventricular pressure at which pulmonary valve open is-----> 8mmHg
- Aldosterone action is-----> Displace Na from cytoplasm to cell membrane
- A man after RTA got a head injury which is to be stitched 10 inch wound/laceration which anesthetic agent w/U best for suturing the wound-----> 250 ml of 2% lignocain with adrenaline
- ----->
- JOIN FCPSWORLD ONLINE CLASSES & CLEAR EXAM IN 1<sup>ST</sup> ATTEMPT
- A Prolactinoma, Now presented with menstrual irregularities and nipple discharge, due to -----> Decrease GnRH
- What type of Cell increase in viral infection-----> Lymphocytes
- Full E tank of oxygen at rate of 6L/min will empty in-----> 10min
- pt present with Ataxia on both closing eyes and open eyes, pt sway with open eyes and eyes closed lesion in-----> Cerebellum



- ✓ Now you can join our Online classes for MD/MS & Fcps Preparation
- ✓ Complete course in 2months including Past paper discussion
- ✓ Join from anywhere using mobile/laptop using internet
- ✓ 100% feasible with job and 100% time adjustment for students
- ✓ [www.fcpsworld.com](http://www.fcpsworld.com) or Contact 03129684658
- ✓ Hostel Facility is also available (for those who want to join physical classes)



For Complete List of Papers Visit our website <https://fcpsworld.com/fcps-pastpapers>

- A CAH, will be raised-----> 17alpha progesterone
- JOIN FCPSWORLD ONLINE CLASSES & CLEAR EXAM IN 1<sup>ST</sup> ATTEMPT
- A person with Gunshot injury to the person, at c7 what will occur in below the level of lesion contralaterally-----> Contralateral Loss of pain and temperature below level of lesion
- pt of asthma having ABGs Ph.7.23. HCO<sub>2</sub>, 26 and Hypercapnea likely acid base disorder is-----> Respiratory acidosis
- Pathological deficit in malignant hyperthermia is-----> Ryanodine receptors
- A diabetic pt with gastro paresis treatment is-----> Prokinetic
- EBV associated all except-----> Hodgkin lymphoma
- Which is part of portal system-----> Superior rectal vein
- Falciparum malaria is what type of organism-----> Ameboid protozoa
- Common muscle contraction protein for smooth and skeletal muscle-----> Actin
- JOIN FCPSWORLD ONLINE CLASSES & CLEAR EXAM IN 1<sup>ST</sup> ATTEMPT
- What change will be seen first in response to stress-----> Increase CRF
- Spectrophotometer obeys law-----> Beer lambert law
- Axillary lymphatics of breast divided in into-----> Medial and Lateral
- Child birth is example of -----> Positive Feed back
- Insulin injection given in DKA, most immediate response is-----> Increase PH
- ----->
- JOIN FCPSWORLD ONLINE CLASSES & CLEAR EXAM IN 1<sup>ST</sup> ATTEMPT
- Decrease in which neurotransmitter cause anxiety-----> GABA
- Fat pad of upper eyelid is anterior to which-----> Levator aponeurosis
- Type of necrosis in kidney and heart is -----> Coagulative
- causes increase in renin level-----> Decrease stretch on cardiac receptor
- A patient with ambiguous genitalia and karyotype 46xx dx is-----> CAH
- A man presented with oral ulcer, B/L pleural effusion, vasculitis, restrictive lung disease and Sclerosis. dx is-----> Progressive systemic sclerosis
- JOIN FCPSWORLD ONLINE CLASSES & CLEAR EXAM IN 1<sup>ST</sup> ATTEMPT
- TPN is contraindicated in condition-----> Liver Disease



- ✓ Now you can join our Online classes for MD/MS & Fcps Preparation
- ✓ Complete course in 2months including Past paper discussion
- ✓ Join from anywhere using mobile/laptop using internet
- ✓ 100% feasible with job and 100% time adjustment for students
- ✓ [www.fcpsworld.com](http://www.fcpsworld.com) or Contact 03129684658
- ✓ Hostel Facility is also available (for those who want to join physical classes)



For Complete List of Papers Visit our website <https://fcpsworld.com/fcps-pastpapers>

- ----->
- boy C/O loss of appetite, vomiting & high coloured Urine, examination yellow dis coloration of sclera, Investigation of Choice is-----> Bilirubin & ALT estimation
- ----->
- Sympathetic cholinergic stimulation causes which effect-----> Vasodilation in skeletal muscle
- Tubular Structure with Small caliber-----> Ureter
- JOIN FCPSWORLD ONLINE CLASSES & CLEAR EXAM IN 1<sup>ST</sup> ATTEMPT
- Sound is best perceived at which area-----> Cochlear nucleus
- pt presented on 18 day of menstrual cycle her normal cycle is such that she ovulates on day 14 which phases will be in-----> Secretory
- A Young man had a toad side accident in which he suffered horn Spinal cord Injury. Some soft filling located in the center of the disc of spinal cord JOIN FCPSWORLD ONLINE CLASSES & CLEAR EXAM IN 1<sup>ST</sup> ATTEMPT
- known as nucleus pulposus. It is derived from which embtyological structure-----> Notochord
- lady nipple discharge Secondary amonorrhea and High prolactin cause of amonorrhea is-----> Decrease GnRH
- ----->
- Treatment of MRSA is-----> Fusidic acid
- JOIN FCPSWORLD ONLINE CLASSES & CLEAR EXAM IN 1<sup>ST</sup> ATTEMPT
- Human is an intermediate host in-----> Hydatid Disease
- Which hormone produces by corpus luteum-----> Estrogen, progesterone and inhibin
- A prolonged diarrhea and undergoes esophagogastroduodenoscopy biopsy of small intestine demonstrates Crescent shape Protozoa adjacent to JOIN FCPSWORLD ONLINE CLASSES & CLEAR EXAM IN 1<sup>ST</sup> ATTEMPT
- epithelial brush border organisms is the most likely pathogen-----> Giardia limblia
- On biopsy of ascending colon mass adenocarcinoma diagnosed risk factor for it-----> Fatty diet



- ✓ Now you can join our Online classes for MD/MS & Fcps Preparation
- ✓ Complete course in 2months including Past paper discussion
- ✓ Join from anywhere using mobile/laptop using internet
- ✓ 100% feasible with job and 100% time adjustment for students
- ✓ [www.fcpsworld.com](http://www.fcpsworld.com) or Contact 03129684658
- ✓ Hostel Facility is also available (for those who want to join physical classes)



For Complete List of Papers Visit our website <https://fcpsworld.com/fcps-pastpapers>

- In normal healthy person, sympathetic activity is increased to increase blood flow to-----> Muscle
- ----->
- JOIN FCPSWORLD ONLINE CLASSES & CLEAR EXAM IN 1<sup>ST</sup> ATTEMPT
- Common location of ureter damaged during hysterectomy is-----> Base of broad ligament
- ----->
- NK cells function is-----> Kill cancerous cells
- A student while asking a question turns red which mechanism involved-----> Active hypermia
- JOIN FCPSWORLD ONLINE CLASSES & CLEAR EXAM IN 1<sup>ST</sup> ATTEMPT
- The fastest conduction speed in cardiac conduction system is a feature of structure-----> Purkinje System
- Muscle relaxant of choice in patient with CLD going in laparotomy-----> Atracurium
- pt of chronic rheumatic fever having deterioration of heart with new onset murmur this is most likely due to-----> Mitral stenosis
- On gene study N myc gene found N myc gene related to -----> Neuroblastoma
- JOIN FCPSWORLD ONLINE CLASSES & CLEAR EXAM IN 1<sup>ST</sup> ATTEMPT
- Joints between vertebral bodies are-----> Symphysis
- What type of necrosis is seen in omentum-----> Fat necrosis
- lady is concerned about her strong family hx of Breast Cancer and IHD. Her sister died of MI She is also concerned about osteoporosis, which prophylaxis drug will you give for post.menopausal related osteoporosis-----> Raloxifene
- A man present with headache fruncle of tip of nose high fever with redness and Swelling of eye Infection from dangerous area of face goes to -----> Cavernous sinus
- Body cavity divided into ventral and dorsal. of these is the dorsal-----> JOIN FCPSWORLD ONLINE CLASSES & CLEAR EXAM IN 1<sup>ST</sup> ATTEMPT
- Cranial



- ✓ Now you can join our Online classes for MD/MS & Fcps Preparation
- ✓ Complete course in 2 months including Past paper discussion
- ✓ Join from anywhere using mobile/laptop using internet
- ✓ 100% feasible with job and 100% time adjustment for students
- ✓ [www.fcpsworld.com](http://www.fcpsworld.com) or Contact 03129684658
- ✓ Hostel Facility is also available (for those who want to join physical classes)



For Complete List of Papers Visit our website <https://fcpsworld.com/fcps-pastpapers>

- A clasp knife spasticity, Hyperreflexia and positive babinski sign due to lesion of-----> UMN
- Primary immune system organ, where T and B lymphocytes are formed and mature is -----> Bone marrow and thymus
- JOIN FCPSWORLD ONLINE CLASSES & CLEAR EXAM IN 1<sup>ST</sup> ATTEMPT
- To calculate plasma osmolality, sodium concentration is multiplied with 2 because of-----> Anions
- ----->
- Regarding parasympathetic stimulation-----> Increase PR interval
- Blood flow to heart depend on -----> Myocardial Oxygen demand
- is last to appear normal in blood after hemorrhage-----> RBCs
- girl playing outside felt pain due to cold weather having increase HR increase BP and shivering will cause-----> Contraction of erector pillae
- has swelling in front of neck thyroid mass usually moves with swallowing  
JOIN FCPSWORLD ONLINE CLASSES & CLEAR EXAM IN 1<sup>ST</sup> ATTEMPT
- because the thyroid gland is enclosed by fascia-----> Pretracheal fascia
- Post sympathetic ganglionic fibers are present in-----> All spinal nerves
- paroxysmal fever, chills and time duration for symptoms appearing was 36 to 48 hours ring and crescent shaped organism involved likely is-----> P.Falciparum
- 0.5 gram of albumin/100 ml is present in which fluid-----> Lymph
- An Old pt presents with enlarged prostate and there is marked increase in  
JOIN FCPSWORLD ONLINE CLASSES & CLEAR EXAM IN 1<sup>ST</sup> ATTEMPT
- PSA up to 20ng/ml having weight loss MRI done and bony metastasis observed. What is the route of spread of prostate CA to vertebrae-----> Vertebral venous plexus
- Person travelling by air having nausea vomiting treatment will be-----> Cyclizine
- ----->
- Decrease lymphatic flow due to-----> Hemorrhage
- ----->
- Type of necrosis in pancreatitis-----> Fatnecrosis



- ✓ Now you can join our Online classes for MD/MS & Fcps Preparation
- ✓ Complete course in 2months including Past paper discussion
- ✓ Join from anywhere using mobile/laptop using internet
- ✓ 100% feasible with job and 100% time adjustment for students
- ✓ [www.fcpsworld.com](http://www.fcpsworld.com) or Contact 03129684658
- ✓ Hostel Facility is also available (for those who want to join physical classes)



For Complete List of Papers Visit our website <https://fcpsworld.com/fcps-pastpapers>

- JOIN FCPSWORLD ONLINE CLASSES & CLEAR EXAM IN 1<sup>ST</sup> ATTEMPT
- A pregnant lady came with premature rupture of membrane she is suspected to have chorioamnionitis. To confirm intra amniotic infection which test should be done-----> IL6
- Lymphatic drainage of external nose & anterior part of nasal cavity is-----> Submandibular lymph nodes
- Necrosis in heart and kidney is-----> Coagulative
- In Ovarian CA staging lymph node affected first-----> Paraaortic lymph node
- Caesium is radioactive substance used for radiotherapy caesium 137 half.life is-----> 30Y
- JOIN FCPSWORLD ONLINE CLASSES & CLEAR EXAM IN 1<sup>ST</sup> ATTEMPT
- Premalignant intraepithelial lesion-----> Paget disease
- CSF absorbed by -----> Arachnoid Villi
- To maintain corpus luteum exogenously which substance to be given-----> Endogenous chorionic gonadotrophins
- A chronic respiratory acidosis. For every 10 rise in PCO<sub>2</sub> the compensatory rise in HCO<sub>3</sub> is-----> 3
- Most common opportunistic infection after kidney transplant is-----> Polyoma
- Transmigration of neutrophils along the smooth epithelium of blood vessels  
JOIN FCPSWORLD ONLINE CLASSES & CLEAR EXAM IN 1<sup>ST</sup> ATTEMPT
- is-----> Diapedesis
- 8 months old girl was vaccinated 2 weeks back, now presents with rash all over body, fever and CBC report showing Hb 13.5g/dl, wbc 6 x 10 and decreased platelets Peripheral smear shows large platelets. What is the dx--> ITP
- A man unable to hold a mug of coffee an image draw of movement shoulder and hand draw on which part of brain-----> Premotor
- Painful genital ulcers occur in -----> Haemophilus ducreyi
- How to differentiate IDA and thalassemia-----> HbA<sub>2</sub>



- ✓ Now you can join our Online classes for MD/MS & Fcps Preparation
- ✓ Complete course in 2months including Past paper discussion
- ✓ Join from anywhere using mobile/laptop using internet
- ✓ 100% feasible with job and 100% time adjustment for students
- ✓ [www.fcpsworld.com](http://www.fcpsworld.com) or Contact 03129684658
- ✓ Hostel Facility is also available (for those who want to join physical classes)





For Complete List of Papers Visit our website <https://fcpsworld.com/fcps-pastpapers>

- pt with 1.year hx of SOB presents With cough. examination wheeze, **JOIN FCPSWORLD ONLINE CLASSES & CLEAR EXAM IN 1<sup>ST</sup> ATTEMPT**
- hyper.resonant chest and decrease vocal fremitus. PFTs show decrease FEV/FVC and also decreased lung elastase. What is the cause of increased activity of neutrophil elastase-----> Nicotine
- Intrauterine ossification of humerus is at-----> 14 weeks
- Probability of difference in two means checked by which test-----> Significance
- A Police gunshot injury at lower back, he lost pain contralateral, temperature intact, lesion in-----> Dorsal root lesion
- man has a pulmonary embolism that completely blocks blood flow to his left lung. As a result will occur-----> Alveolar PO<sub>2</sub> in the left lung will be **JOIN FCPSWORLD ONLINE CLASSES & CLEAR EXAM IN 1<sup>ST</sup> ATTEMPT**
- approximately equal to the PO<sub>2</sub> in the inspired air
- lady pt came in cardiac OPD with cardiac defect psychiatric behavior and cleft palate likely due to-----> Kliefilter
- A diabetic lady having difficulty in going downstairs her head was tilted upwards and out which muscle is damage-----> Superior Oblique
- Regarding primary cartilage joints true is-----> Present in appendicular skeleton
- Insulin and glucagon are released when there is increase in-----> CCK
- **JOIN FCPSWORLD ONLINE CLASSES & CLEAR EXAM IN 1<sup>ST</sup> ATTEMPT**
- HLA B27 is associated with-----> Reiter's Syndrome
- What cavity is Present between splanchnic and somatic layer of extraembryonic mesoderm-----> Extraembryonic coelom
- Adrenal medulla is derived from-----> Neural Crest Cell
- pt lost 10.15% blood loss. How to replace-----> 3 times Normal saline
- Free margin of falciform ligament contains -----> Ligamentum teres
- Diaphragmatic parietal pleura nerve supply is by-----> Both Phrenic and intercostal
- lost line touch, vibration and proprioception where is the lesion-----> DCML
- **JOIN FCPSWORLD ONLINE CLASSES & CLEAR EXAM IN 1<sup>ST</sup> ATTEMPT**



- ✓ Now you can join our Online classes for MD/MS & Fcps Preparation
- ✓ Complete course in 2months including Past paper discussion
- ✓ Join from anywhere using mobile/laptop using internet
- ✓ 100% feasible with job and 100% time adjustment for students
- ✓ [www.fcpsworld.com](http://www.fcpsworld.com) or Contact 03129684658
- ✓ Hostel Facility is also available (for those who want to join physical classes)



For Complete List of Papers Visit our website <https://fcpsworld.com/fcps-pastpapers>

- *Eustachian tube epithelium is*-----> Pseudo stratified columnar ciliated
- has bronchial obstruction but alveoli are still aerated by bronchus and do not collapse this is due to -----> Alveolar pore
- ----->
- Pectoral lymph nodes enlarged on examination. Which area drained-----> Outer upper
- The amount of heat loss from body depends upon-----> Temperature of **JOIN FCPSWORLD ONLINE CLASSES & CLEAR EXAM IN 1<sup>ST</sup> ATTEMPT**
- external environment
- Percentage of oxygen in a mixture of 2% halothane and air is-----> 20.4%
- 1ml of isoflurane produces how much vapors-----> 200ml
- DNA replication occurs in which phase-----> Interphase
- Radioimmunoassay of hormone small displacement by antibody due to-----> Excessive antibody response
- Fetal brain development is caused by-----> Thyroid hormone
- Mural thrombosis is related to -----> Heart
- Free radical formation in a cell is formed by-----> Mitochondria
- **JOIN FCPSWORLD ONLINE CLASSES & CLEAR EXAM IN 1<sup>ST</sup> ATTEMPT**
- A naked person in AC room with temperature 21, humidity 80%, heat loss will be through-----> Radiation and conduction
- Vein dilated in portal hypertension-----> Superior rectal
- A person presented to you with hx of severe headache and vomiting at start of day. There was a tumor which was in cerebellar area involving granular layer what it can be-----> Medulloblastoma
- woman is admitted to a hospital because the birth of her child is several days overdue. Tearing of the pelvic diaphragm during childbirth leads to paralysis of muscles-----> Levator ani
- **JOIN FCPSWORLD ONLINE CLASSES & CLEAR EXAM IN 1<sup>ST</sup> ATTEMPT**
- A young man of 30 years having Kyphoscoliosis in which respiratory muscle weakness observed decrease respiration result due to -----> Decrease vital capacity



- ✓ Now you can join our Online classes for MD/MS & Fcps Preparation
- ✓ Complete course in 2months including Past paper discussion
- ✓ Join from anywhere using mobile/laptop using internet
- ✓ 100% feasible with job and 100% time adjustment for students
- ✓ [www.fcpsworld.com](http://www.fcpsworld.com) or Contact 03129684658
- ✓ Hostel Facility is also available (for those who want to join physical classes)



For Complete List of Papers Visit our website <https://fcpsworld.com/fcps-pastpapers>

- lady undergoes abdominal surgery 10 years ago now she is diagnose with HCC thought to cause by Hep B. It is said that DNA and RNA viruses are oncogens of the is caused by RNA virus-----> T cell leukemia causing virus
- lady who is not conceiving examination having discharge from mammary  
JOIN FCPSWORLD ONLINE CLASSES & CLEAR EXAM IN 1<sup>ST</sup> ATTEMPT
- gland due to hormone-----> Prolactin
- PaSent after thyroidectomy developed hoarseness of voice. Examination reveals tense vocal cords. is most likely damaged-----> Vocalis
- pt unable to recognize faces (prospagnosia) area injured is-----> Parieto Temporal Lobe
- In weather changes and asthmatic have cough which receptors involved-----> Irritant receptors
- lady presented with hx of fever since last 10 days now with continuous chest pain that radiates to back and left parasternal rustling sound most  
JOIN FCPSWORLD ONLINE CLASSES & CLEAR EXAM IN 1<sup>ST</sup> ATTEMPT
- likely suffers from-----> Pericarditis
- Longest pro erythrocytic stage is of-----> P. maladae
- Deep injury in radial groove, what movement will be affected-----> Loss of extension of wrist resulting in wrist drop
- Rigor mortis is due to-----> Decreased ATP
- A day hysterectomy, pt complains of severe pain in the right upper lumbar region of the back. structures was most likely damaged during the surgery-----> Ureter
- JOIN FCPSWORLD ONLINE CLASSES & CLEAR EXAM IN 1<sup>ST</sup> ATTEMPT
- Tailor had Tb infection transmitted to two of his family members mode of spread of this is-----> Aerosolated ait droplets
- ----->
- Lady heard his husband saying that the neighbor loves her but do not confess which further proves contacting the neighbour but he refused which makes her sad. She is pre occupied with this thought. Sometimes get confused diagnose is -----> Delusion disorder



- ✓ Now you can join our Online classes for MD/MS & Fcps Preparation
- ✓ Complete course in 2months including Past paper discussion
- ✓ Join from anywhere using mobile/laptop using internet
- ✓ 100% feasible with job and 100% time adjustment for students
- ✓ [www.fcpsworld.com](http://www.fcpsworld.com) or Contact 03129684658
- ✓ Hostel Facility is also available (for those who want to join physical classes)



For Complete List of Papers Visit our website <https://fcpsworld.com/fcps-pastpapers>

- Atherosclerosis plaque 3 found-----> Smooth muscle, extracellular matrix, intracellular matrix and lipids  
JOIN FCPSWORLD ONLINE CLASSES & CLEAR EXAM IN 1<sup>ST</sup> ATTEMPT
- The best diagnostic lab test for the infection by streptococcus beta haemolyticus is-----> Blood culture
- Heparin activates which of -----> Anti thrombin 3
- What would be best accurate investigation for the antepartum fetal well being with lowest rate of false positive-----> Biophysical profile
- Major plasma buffer-----> HCO<sub>3</sub>/H<sub>2</sub>CO<sub>3</sub>
- A wound left open for secondary wound healing which cell play a key role in wound contraction of secondary wound healing-----> MyoFibroblast
- Cells which cant regenerate after injury is -----> Permanent cells  
JOIN FCPSWORLD ONLINE CLASSES & CLEAR EXAM IN 1<sup>ST</sup> ATTEMPT
- End diastolic volume depends on-----> Venous return
- ----->
- A known SLE lethargy weakness jaundice hemolytic anemia having raised LDH and Retic count suitable investigation to confirm this-----> Direct and globulin antibody,
- pt contacted with hepatitis D virus on viral serology hepatitis would it require to have because it's weak in its own-----> Hep.B
- Antiestrogenic (tamoxifen) has beneficial effect on which-----> Breast
- Myxoid degeneration is mostly associated with-----> Mitral valve prolapse
- A tingling sensations in his peripheral body and lab investigation reveal raised MCV and hypersegmented Neutrophils What is the most probable pathology-----> Vitamin B12 deficiency  
JOIN FCPSWORLD ONLINE CLASSES & CLEAR EXAM IN 1<sup>ST</sup> ATTEMPT
- Primitive streak mesoderm migrate to anterior abdominal wall and around cloaca, a rupture of this mesoderm cranially will produce -----> Ectopic anal opening
- A team of cardiologists investigating the relationship between MI in 1200 men in age group 50 . 75 years and activity level 24 hrs preceding the attack



- ✓ Now you can join our Online classes for MD/MS & Fcps Preparation
- ✓ Complete course in 2months including Past paper discussion
- ✓ Join from anywhere using mobile/laptop using internet
- ✓ 100% feasible with job and 100% time adjustment for students
- ✓ [www.fcpsworld.com](http://www.fcpsworld.com) or Contact 03129684658
- ✓ Hostel Facility is also available (for those who want to join physical classes)



For Complete List of Papers Visit our website <https://fcpsworld.com/fcps-pastpapers>

Activity level was classified as exertion the results were Heavy exertion 50% Moderate exertion , 35% Mild exertion 15%-----> Pie chart

- 4rd and 6th arch derivative is-----> Cricoid cartilage
- A group of student goes to local Chinese restaurant. All were served with beans with vegetables and fried rice. All the students after six hour duration developed nausea vomiting abdominal pain diarrhea due to which  
JOIN FCPSWORLD ONLINE CLASSES & CLEAR EXAM IN 1<sup>ST</sup> ATTEMPT
- of causative organism-----> Bacillus cereus
- Drug of choice for cardiogenic shock is-----> Dopamine and Dobutamine
- Kidney activates which of the -----> Cholic acid
- Function of clomiphene citrate is-----> Stimulate ovulation
- Derivatives of third pharyngeal pouch is-----> Thymus
- Most dangerous side effect of estrogen therapy is-----> Thromboembolism
- An esophageal mass During esophagectomy stomach is mobilized to upper portion of thorax to anastomosis with pharynx which artery is mobilized for stomach supply-----> Right gastroepiploic
- A ship building worker has a hx of weight loss from 10 year malignancy is most likely to occur in this man-----> Bronchogenic carcinoma
- JOIN FCPSWORLD ONLINE CLASSES & CLEAR EXAM IN 1<sup>ST</sup> ATTEMPT
- ----->
- A baby has some cardiac abnormality, she has machinery murmur on auscultation what is the abnormality-----> PDA
- MOA of theophylline is-----> Phosphodiesterase inhibition
- What is the characteristic feature of treponema pallidum-----> Causes yaws
- Short term memory loss occurs due to lesion of-----> Hippocampus
- There was hemisection of vertebra what will be lost contralateral-----> JOIN FCPSWORLD ONLINE CLASSES & CLEAR EXAM IN 1<sup>ST</sup> ATTEMPT
- Warmth
- Left pons connection with-----> Right cerebellum left cerebrum
- ----->
- ----->



- ✓ Now you can join our Online classes for MD/MS & Fcps Preparation
- ✓ Complete course in 2months including Past paper discussion
- ✓ Join from anywhere using mobile/laptop using internet
- ✓ 100% feasible with job and 100% time adjustment for students
- ✓ [www.fcpsworld.com](http://www.fcpsworld.com) or Contact 03129684658
- ✓ Hostel Facility is also available (for those who want to join physical classes)



For Complete List of Papers Visit our website <https://fcpsworld.com/fcps-pastpapers>

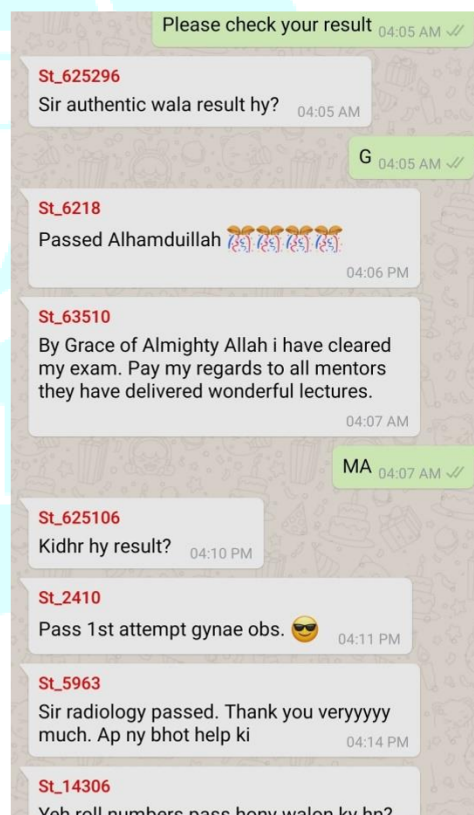
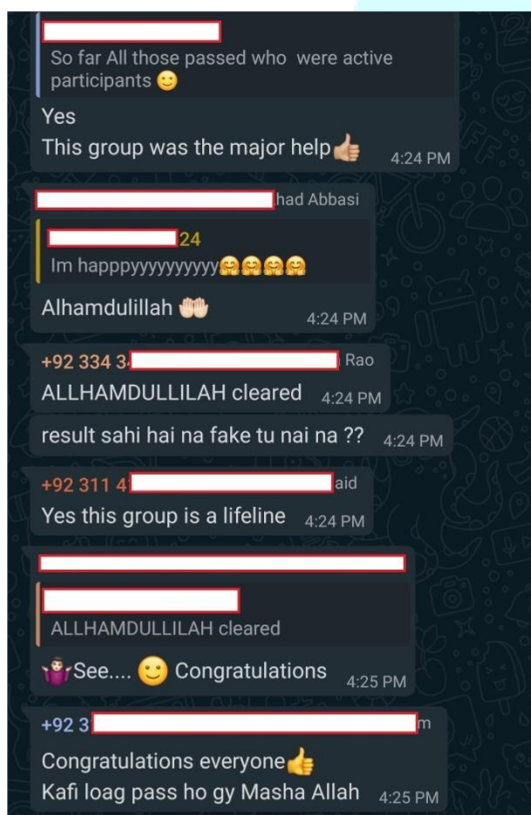- pt came with of skin rash and urticaria hx of diptheria vaccine few days back type of hypersensitivity will be-----> Type 3
- JOIN FCPSWORLD ONLINE CLASSES & CLEAR EXAM IN 1<sup>ST</sup> ATTEMPT
- A fallopian tube ligation ligature slipped result in bleeding and pt become hemodynamically unstable bleeding result from -----> Uterine artery
- Foot drop is due to damage-----> Common peroneal nerve
- After mastectomy for breast carcinoma lady developed winging of scapula, which is due to damage to-----> Long thoracic nerve damage
- T lymphocyte produce what that causes red blood cell proliferation-----> Interleukin 3
- Lady having hematological disease, admitted for two weeks, developed dyspnea, Many areas of infarction seen on X-ray after that developed pulmonary hypertension due to-----> Recurrent previous pulmonary
- JOIN FCPSWORLD ONLINE CLASSES & CLEAR EXAM IN 1<sup>ST</sup> ATTEMPT
- embolism
- Diagnostic of iron deficiency anemia is by -----> Serum ferritin
- Thirst is increased by-----> Increase Angiotensin 2
- lady urethra in lady-----> More prone to infection
- Baroreceptors maintains-----> Mean arterial pressure
- JOIN FCPSWORLD ONLINE CLASSES & CLEAR EXAM IN 1<sup>ST</sup> ATTEMPT
- In malignant melanoma pt tissue excised for biopsy which shows heterogenous cells most predominant cells will be against tumor are-----> NK cells
- Alpha value 0.001 in statistics represents what-----> Chance of correctly rejecting the null hypothesis is 1 out of 1000
- Low grade follicular lymphoma translocation is -----> T1418
- Student was sitting on stool and visualizing slide on microscope professor suddenly asked you are sitting on which bone-----> Ischia tuberosity
- JOIN FCPSWORLD ONLINE CLASSES & CLEAR EXAM IN 1<sup>ST</sup> ATTEMPT



- ✓ Now you can join our Online classes for MD/MS & Fcps Preparation
- ✓ Complete course in 2 months including Past paper discussion
- ✓ Join from anywhere using mobile/laptop using internet
- ✓ 100% feasible with job and 100% time adjustment for students
- ✓ [www.fcpsworld.com](http://www.fcpsworld.com) or Contact 03129684658
- ✓ Hostel Facility is also available (for those who want to join physical classes)

▪ **Almost every student who joins our Online Classes**  
**Passes exam (Alhamduillah)**

- Join FCPSWORLD Online Classes and clear your 100% concepts. Our lectures presentations are extract of past papers and consist on FirstAid, BRS, snell anatomy, kaplan neuroanatomy etc.



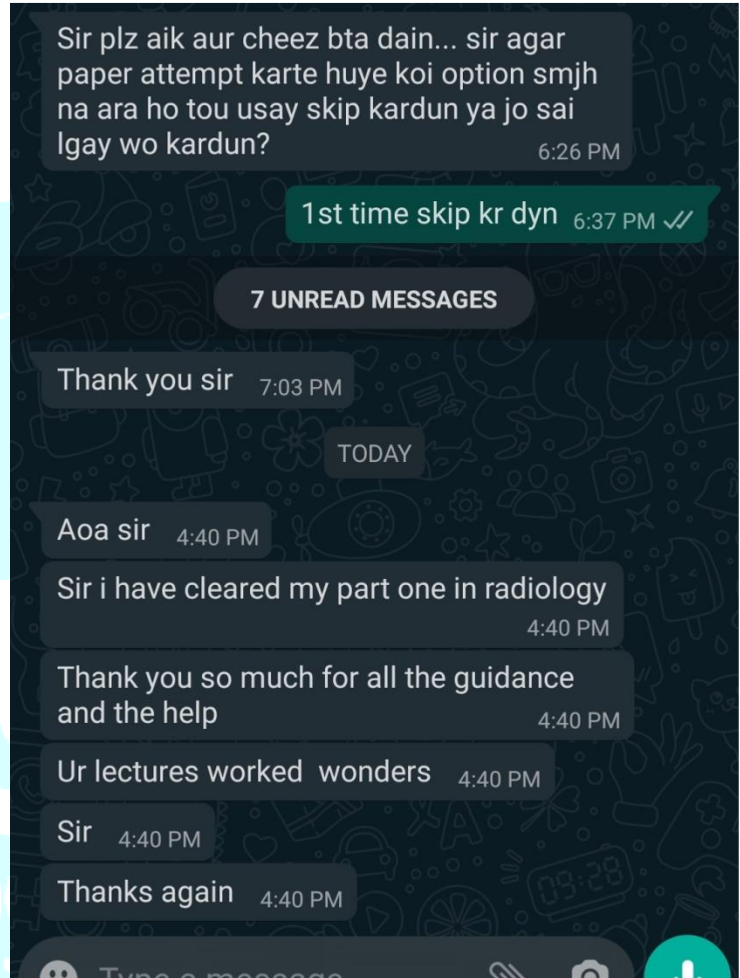
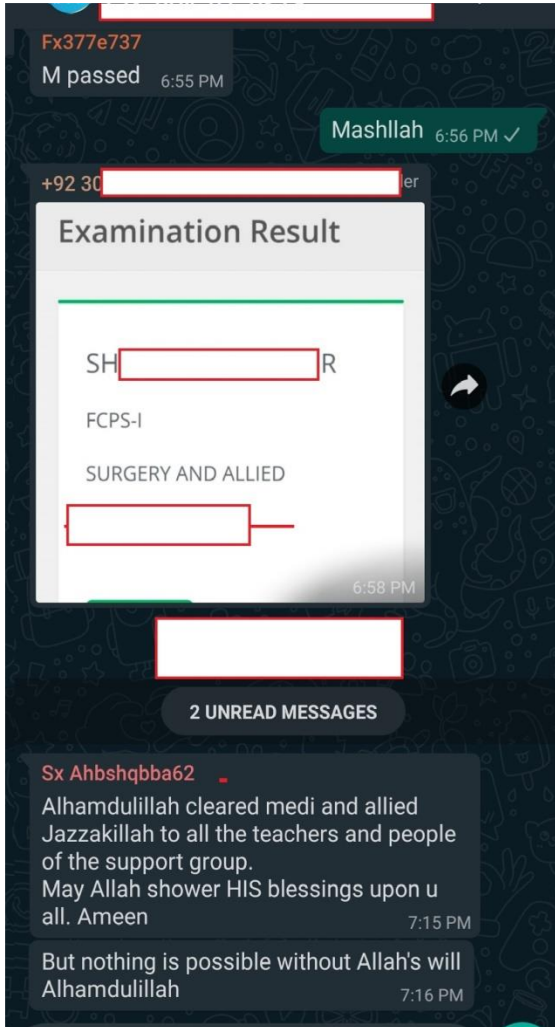
**& Many More Success Stories**



- ✓ Now you can join our Online classes for MD/MS & Fcps Preparation
- ✓ Complete course in 2months including Past paper discussion
- ✓ Join from anywhere using mobile/laptop using internet
- ✓ 100% feasible with job and 100% time adjustment for students
- ✓ [www.fcpsworld.com](http://www.fcpsworld.com) or Contact 03129684658
- ✓ Hostel Facility is also available (for those who want to join physical classes)



For Complete List of Papers Visit our website <https://fcpsworld.com/fcps-pastpapers>



## & Many More Success Stories



- ✓ Now you can join our Online classes for MD/MS & Fcps Preparation
- ✓ Complete course in 2months including Past paper discussion
- ✓ Join from anywhere using mobile/laptop using internet
- ✓ 100% feasible with job and 100% time adjustment for students
- ✓ [www.fcpsworld.com](http://www.fcpsworld.com) or Contact 03129684658
- ✓ Hostel Facility is also available (for those who want to join physical classes)



Www.Fcpsworld.com (Institute for Fcps & Md/Ms)

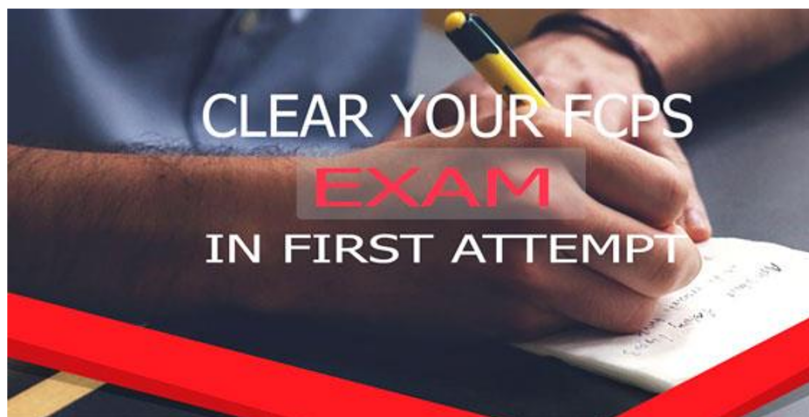[www.facebook.com/FcpsWorld](http://www.facebook.com/FcpsWorld)

[www.facebook.com/GynaeObsWorld](http://www.facebook.com/GynaeObsWorld)

[www.facebook.com/Ophtworld](http://www.facebook.com/Ophtworld)



For Complete List of Papers Visit our website <https://fcpsworld.com/fcps-pastpapers>



FCPS-1 FEBRUARY 2022

## REVISION COURSE

GOLDEN POINTS

PASTPAPERS 2009-2021

HIGH YIELD CONCEPTS

Online Interactive Classes

REGISTER NOW!

20\* SEATS ONLY



FEE RS 1200 ONLY

[WWW.FCPSWORLD.COM/REGISTER](http://WWW.FCPSWORLD.COM/REGISTER)

SURGERY & ALLIED | MEDICINE & ALLIED  
| GYNAE OBS | ENT | PATHOLOGY | RADIOLOGY  
| OPTH | ANESTHESIA | DENTISTRY | PSY |

CALL US NOW  
+92 312 9684658



- ✓ Now you can join our Online classes for MD/MS & Fcps Preparation
- ✓ Complete course in 2 months including Past paper discussion
- ✓ Join from anywhere using mobile/laptop using internet
- ✓ 100% feasible with job and 100% time adjustment for students
- ✓ [www.fcpsworld.com](http://www.fcpsworld.com) or Contact 03129684658
- ✓ Hostel Facility is also available (for those who want to join physical classes)

Www.Fcpsworld.com (Institute for Fcps & Md/Ms)

[www.facebook.com/FcpsWorld](http://www.facebook.com/FcpsWorld)

[www.facebook.com/GynaeObsWorld](http://www.facebook.com/GynaeObsWorld)

[www.facebook.com/Ophtworld](http://www.facebook.com/Ophtworld)



For Complete List of Papers Visit our website <https://fcpsworld.com/fcps-pastpapers>

# FCPS-1 ONLINE COURSE

Join FcpsWorld Online preparation courses and clear exam in 1st Attempt.


[WWW.FCPSWORLD.COM](http://WWW.FCPSWORLD.COM)



Fcpsworld



[www.fcpsworld.com](http://www.fcpsworld.com)



**BUY 3<sup>rd</sup> edition ONLY**



- ✓ Now you can join our Online classes for MD/MS & Fcps Preparation
- ✓ Complete course in 2months including Past paper discussion
- ✓ Join from anywhere using mobile/laptop using internet
- ✓ 100% feasible with job and 100% time adjustment for students
- ✓ [www.fcpsworld.com](http://www.fcpsworld.com) or Contact 03129684658
- ✓ Hostel Facility is also available (for those who want to join physical classes)

Www.Fcpsworld.com (Institute for Fcps & Md/Ms)

[www.facebook.com/FcpsWorld](https://www.facebook.com/FcpsWorld)

[www.facebook.com/GynaeObsWorld](https://www.facebook.com/GynaeObsWorld)

[www.facebook.com/Ophtworld](https://www.facebook.com/Ophtworld)



For Complete List of Papers Visit our website <https://fcpsworld.com/fcps-pastpapers>

## GoldStandard FCPS (Buy 3<sup>rd</sup> edition only)

- ✓ November 2022 papers (recent updated)
- ✓ Revise 11 years pastpapers in just 11 days

✓ Authentic most repeated papers.

✓ Subject wise topic wise MCQS

✓ 1 liner for rapid revision. (Cram them)

✓ Clear FCPS-1 in 1st Attempt (Dont miss chance)

✓ Free Cash on Delivery Order at

[www.fcpsworld.com/order-book](https://www.fcpsworld.com/order-book)



- ✓ Now you can join our Online classes for MD/MS & Fcps Preparation
- ✓ Complete course in 2months including Past paper discussion
- ✓ Join from anywhere using mobile/laptop using internet
- ✓ 100% feasible with job and 100% time adjustment for students
- ✓ [www.fcpsworld.com](https://www.fcpsworld.com) or Contact 03129684658
- ✓ Hostel Facility is also available (for those who want to join physical classes)



For Complete List of Papers Visit our website <https://fcpsworld.com/fcps-pastpapers>

GoldStandard FCPS 4<sup>th</sup> Edition V1 (Golden 13)

## Table of Content

1. CVS SYSTEM	Page#5
2. ENDOCRINE SYSTEM	Page#33
3. RENAL SYSTEM	Page#69
4. RESPIRATORY SYSTEM	Page#89
5. GIT SYSTEM	Page#113
6. Hematology	Page#145
7.	
8. ANATOMY	
a. UPPER LIMB	Page#169
b. LOWER LIMB	Page#200
c. THORAX	Page#225
d. NEUROANATOMY	Page#233
e. HEAD AND NECK	Page#270
f. ABDOMEN PELVIS	Page#281
g. Histology	Page#292
h. General Anatomy	Page#294
9. PHARMACOLOGY	Page#298
10. MICROBIOLOGY	
a. Bacteriology	Page#301
b. Virology	Page#309
c. Fungi	Page#3011

### NOTE:

1. MCQs should be covered in retrograde fashion
2. All students who have ordered book will receive November papers in PDF as well via whatsapp (Do them first)
3. All written In **tabular** form or in **points** form are pastpapers
4. Each and every word from this book is from pastpapers (Except UPPER/LOWER LIMBS that has bit of explanation)
5. Students are highly advised to take Last Minute revision course starting in last 10 days of EXAMS (All points and systems will be covered 3 hr class daily)  
Register: [www.fcpsworld.com/register](http://www.fcpsworld.com/register)

**If you have less time first do PDF files sent by us, then open each topic just CRAM TABULAR PASTPAPERS, then open each system and cram MISC 2019-2021 papers of all systems after completing those start MISC 2009-2021 of from system one.**



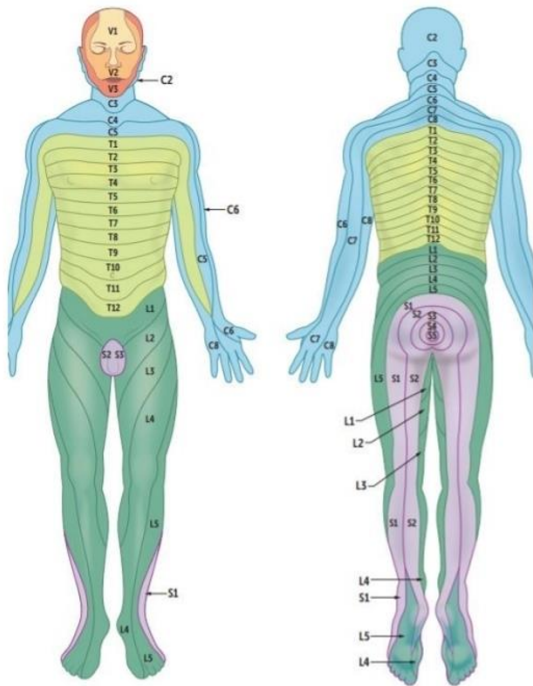


For Complete List of Papers Visit our website <https://fcpsworld.com/fcps-pastpapers>

GoldStandard FCPS 4<sup>th</sup> Edition V1 (Golden 13)

- Superficial fascia of the scalp is mixture of → Loose areolar and adipose tissue
- The axillary sheath is a continuation of → Prevertebral fascia
- Thyroid gland moves with swallowing because it is enclosed in → Pretracheal fascia
- Trauma to one kidney without the perforation of Gerota fascia, the blood goes to → Inferiorly to the pelvis
- True regarding the posterior triangle of neck is → Roof formed by investing layer of deep cervical fascia

**DERMATOMES**



C2	Posterior half of skull
C3	High turtleneck shirt Diaphragm and gallbladder pain referred to the right shoulder via phrenic nerve ✓ C3, 4, 5 keeps the diaphragm alive
C4	Low-collar shirt
C6	Includes thumbs ✓ Thumbs up sign on left hand looks like
T4	✓ At the nipple ✓ T4 at the teat pore
T7	✓ At the xiphoid process 7 letters in xiphoid
T10	✓ At the umbilicus (belly button) Point of referred pain in early appendicitis
L1	✓ At the Inguinal Ligament
L4	✓ Includes the kneecaps Down on ALL 4's
S2, S3, S4	✓ Sensation of penile and anal zones S2, 3, 4 keep the penis off the floor

GREAT TOE	L4
LITTLE TOE	S1
KNEE	L4
NIPPLE	T4
UMBILICUS	T10
RING AND LITTLE FINGER	C8 RING, T1 LITTLE
THUMB	C6

anal area dermatome	s3-4
dermatome of lateral wrist	c6
dermatomy of thumb	c6

Join FcpsWorld Online Classes and Clear exam in 1<sup>st</sup> Attempt

GoldStandard FCPS 4<sup>th</sup> Edition V1 (Golden 13)

knee dermatome	l4
lower end of clavicle dermatome	c3-4
pain in calf and medial malleolus dermatome	l4

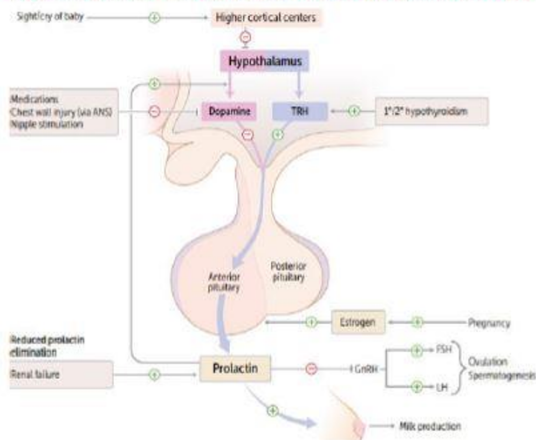




For Complete List of Papers Visit our website <https://fcpsworld.com/fcps-pastpapers>

**Prolectin**

1. Stimulates milk production in breast; inhibits ovulation in females and spermatogenesis in males by inhibiting **GnRH** synthesis and release (thus **LH, FSH release**).
  - Hypothalamus -> Decr GnRH secretion -> Decr FSH/LH -> Decr estradiol in females, Decr testosterone in males
  - Alveolar Cells of Breast Ducts -> Milk production and release -> Lactation
  - Prolectin release dopamine which inhibits prolectin
2. Release by sucking, voice of baby
3. Prolectin secretion from anterior pituitary is tonically inhibited by **dopamine** Prolectin.



**PAST PAPERS**

Potent stimulus for prolactin release is?	Suckling reflex of baby
A 9-month pregnant presents with complaints of lactation (milky discharge). This is likely due to	Prolactin
Secretion of milk in mammary gland is due to	Prolactin
During lactation, ovulation is inhibited because of inhibition of GnRH by?	Prolactin
hormone of the anterior pituitary is under direct inhibitory control of hypothalamus?	Prolactin
During lactation, ovulation is inhibited because of inhibition of GnRH hv?	Prolactin



- ✓ Now you can join our Online classes for MD/MS & Fcps Preparation
- ✓ Complete course in 2months including Past paper discussion
- ✓ Join from anywhere using mobile/laptop using internet
- ✓ 100% feasible with job and 100% time adjustment for students
- ✓ [www.fcpsworld.com](http://www.fcpsworld.com) or Contact 03129684658
- ✓ Hostel Facility is also available (for those who want to join physical classes)



For Complete List of Papers Visit our website <https://fcpsworld.com/fcps-pastpapers>

GoldStandard FCPS 4<sup>th</sup> Edition V1 (Golden 13)

## ENDOCARDITIS

- Nonbacterial endocarditis is seen in → Neoplasms, hypercuaquable state
- Most common cause of death in rheumatic fever → Myocarditis
- Commonly use Tri-cuspaed valvue
- common in IV-drug users
- Libman-Sack Endocarditis occurs in → SLE
- DOC is benzethins pencilline if allergic give genta+vanco
- Correct infective endocarditis sequence  
Damage valve, Thrombus, Bacteremia, Perforation (VT-BP)

**Bacterial endocarditis** Acute—*S aureus* (high virulence). Large vegetations on previously normal valves. Rapid onset.  
Subacute—viridans streptococci (low virulence). Smaller vegetations on congenitally abnormal or diseased valves. Sequela of dental procedures. Gradual onset.

Tricuspid valve endocarditis is associated with IV drug use (don't "tri" drugs). Associated with *S aureus*, *Pseudomonas*, and *Candida*.  
*S bovis* (*galloyticus*) is present in colon cancer, *S epidermidis* on prosthetic valves.

## PAST PAPERS

Non thrombotic bacterial endocarditis is frequently associated with?	Terminal neoplasm
A known case of rheumatic mitrai stenosis developed fever, lassitude body ache after tooth extraction. O/E splinter haemorrhages and splenomegaly was noted Subacute endocarditis is suspected. Most likely organism on blood culture would be?	Strep viridans
Most common heart valve affected in diseases is	Tricuspid
Female pt. has valvular heart disease, such pt. are at risk of developing infective endocarditis, which organism is commonly responsible	streptococcus viridians
On Examination there are skin spots and nail bed hemorrhages on both hands & a Grade-4 Diastolic Murmur, past history is unremarkable. Patient is most likely suffering from	Infective Endocarditis
Developed fever, lassitude body ache after tooth extraction. Most likely organism on blood culture would be	Strep viridians
Infective endocarditis Patient is allergic to penicillin give medication	Vancomycin + gentamicin
School teacher who after death was diagnosed as a case of endocarditis and lymphocytic infiltration of cardiac tissues	Coxsackie virus



- ✓ Now you can join our Online classes for MD/MS & Fcps Preparation
- ✓ Complete course in 2months including Past paper discussion
- ✓ Join from anywhere using mobile/laptop using internet
- ✓ 100% feasible with job and 100% time adjustment for students
- ✓ [www.fcpsworld.com](http://www.fcpsworld.com) or Contact 03129684658
- ✓ Hostel Facility is also available (for those who want to join physical classes)



For Complete List of Papers Visit our website <https://fcpsworld.com/fcps-pastpapers>

GoldStandard FCPS 4<sup>th</sup> Edition V1 (Golden 13)

True about CSF	Slightly acidic than plasma
----------------	-----------------------------

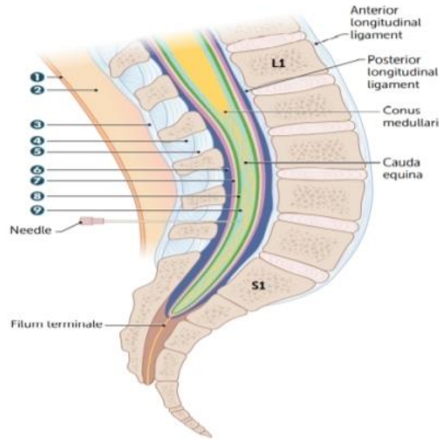
**LUMBER PUNCTURE**

In adults, spinal cord ends at lower border of L1–L2 vertebrae. Subarachnoid space (which contains the CSF) extends to lower border of S2 vertebra. Lumbar puncture is usually performed between L3–L4 or L4–L5 (level of cauda equina).

Goal of lumbar puncture is to obtain sample of CSF without damaging spinal cord. To **keep** the cord **alive**, keep the spinal needle between **L3 and L5**.

Needle passes through:

- 1 skin
- 2 fascia and fat
- 3 supraspinous ligament
- 4 interspinous ligament
- 5 ligamentum flavum
- 6 epidural space (epidural anaesthesia needle stops here)
- 7 dura mater
- 8 arachnoid mater
- 9 subarachnoid space (CSF collection occurs here)



Past papers

During LP after crossing flavum at L3, L4 the needle touches which structure first	Epidural space
Ideal site for lumbar puncture is	Below L4
Regarding Epidural space extension	Foramen magnum to S2
Site of Epidural anaesthesia for patient undergoing Vaginal hysterectomy is	Sacral hiatus
Spinal cord is suspended in dura by	Denticulate ligament
Structure most likely pierced by needle during lumbar puncture is	Ligamentum flavum
Which of the following structure is pierced in paramedian approach	Ligamentum flavum
The most common site of spinal anaesthesia is?	Subarachnoid
Subarachnoid space ends at the level of	S2-S3
Cauda equina:	Anterior & posterior roots of spinal cord from L1 to L5

Note:

Herniation between L4-L5 affect which spinal segment?	Lumbar
Between L4 and L5 disc herniation, which spinal nerve will be affected	L5
Herniation between L4-L5 affect which spinal segment	L4

**Centers of Brain**

- Vomiting centre located in → Medulla
- Cough centre is present in → medulla
- Respiratory centre located in → Medulla oblongata

Past papers



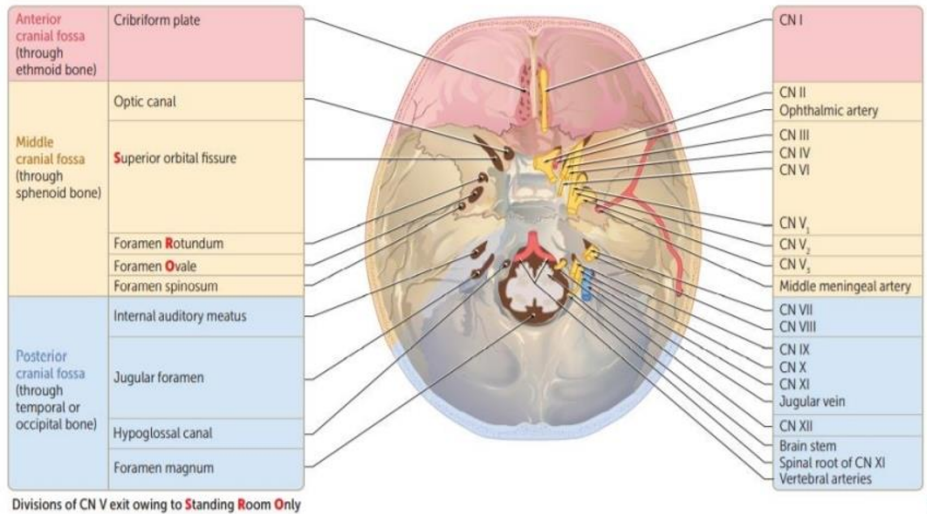


For Complete List of Papers Visit our website <https://fcpsworld.com/fcps-pastpapers>

GoldStandard FCPS 4<sup>th</sup> Edition V1 (Golden 13)

## HEAD AND NECK

### Foramin of Skull



Anterior cranial Fossa (ethmoid bone)	Cribriform plate	CN 1
Middle Cranial Fossa (sphenoid bone)	Optic Canal	CN2 Ophthalmic artery, central retinal vein
	Superior orbital fissure	CN2,4,6 CN 5-V1
	Foramen rotundum	CN5-V2 → maxillary branch of trigeminal nerve
	Foramen ovale	CN5-V3 → mandibular branch of trigeminal nerve
Posterior Cranial Fossa (temporal or occipital bone)	Foramen spinosum	Middle meningeal artery
	Internal auditory meatus	CN7, 8
	Jugular foramen	CN 9,10,11 Jugular vein
	Hypoglossal canal	CN12
	Foramen magnum	Brain stem Spinal root of CN 12 Vertebral arteries

Pastpapers

270/314

Accessory meningeal artery enters through which foremen----->Ovale
Accessory nerve passes through which foramen----->Jugular foramen
Foramen Rotundum damaged which structure will be severed----->Maxillary branch of trigeminal nerve.
Lesion below foramen Ovale causes paralysis of----->Lower part of face/Jaw
Mandibular branch of Trigeminal nerve passes through----->Foramen ovale
Middle meningeal artery in the----->Foramen Spinosum
Nerve in foramen Ovale damaged nerve supply of which part will be affected----->Lower face
Vagus nerve passes through----->jugular foramen



For Complete List of Papers Visit our website <https://fcpsworld.com/fcps-pastpapers>

**FSH & LH**

**LH**

**Luteinizing Hormone in males acts on = Leydig cells**

1. **Luteinizing** hormone acts on = **Leydig** cells to produce **Testosterone**
2. Function of LH before ovulation is=Convert most of the **granulosa** cells into **lutein** cells

Join FcpsWorld Online Classes and Clear exam in 1<sup>st</sup> Attempt

GoldStandard FCPS 4<sup>th</sup> Edition V1 (Golden 13)

**FSH**

3. **FSH** acts on =**Sertoli** cells to do **Spermatogenesis** → Related to **Azoospermia**

[**LighT** is **FaSt**]

- Development of seminiferous tubules
- Convert testosterone into estradiol
- Helps in maturation of follicles
- Inhibited by **INHIBIN**

Spermatogenesis is stimulated by	FSH and testosterone
LH act through:	cAMP
Hormone causing increase release of testosterone:	Luteinizing hormone
LH act on which testicular cells mostly	Leydig cells

Function of sertoli cells	help in spermiogenesis
A tall man with normal external genitalia married but no kids. Semen analysis showed azospermia. Most likely cause may be in	Sertoli cell
Sertoli cells produce	MIF (Mullerian inhibitory factor)
Married man with azospermia. Investigation of choice is	Serum FSH + LH

Function and development of seminiferous tubule requires=FSH and androgen  
 Testosterone converted to estradiol by which hormone= FSH  
 Conversion of testosterone to 17-beta estradiol in granulosa cells occurs by the influence of= FSH

**Before Ovulation maturation of follicles occur by action of FSH**

Maturation of follicles

Hormone responsible is FSH mainly and LH partly.

**GnRH from hypothalamus release FSH and LH by pituitary**

Which hormone stimulates release of FSH and LH	GnRH
During lactation, amenorrhea occurs due to	Inhibition of GnRH

**The Sertoli cells also secrete inhibin Which stop FSH secretion**

- ✓ [www.fcpsworld.com](http://www.fcpsworld.com) or Contact 03129684658
- ✓ Hostel Facility is also available (for those who want to join physical classes)





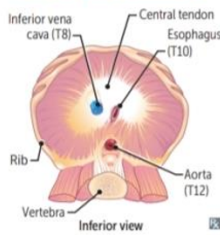
For Complete List of Papers Visit our website <https://fcpsworld.com/fcps-pastpapers>

GoldStandard FCPS 4<sup>th</sup> Edition V1 (Golk

# Thorax

## Diaphragm

### Diaphragm structures



Structures perforating diaphragm:

- At T8: IVC, right phrenic nerve
- At T10: esophagus, vagus (CN 10; 2 trunks)
- At T12: aorta (red), thoracic duct (white), azygos vein (blue) ("At T-1-2 it's the red, white, and blue")

Diaphragm is innervated by C3, 4, and 5 (phrenic nerve). Pain from diaphragm irritation (eg, air, blood, or pus in peritoneal cavity) can be referred to shoulder (C5) and trapezius ridge (C3, 4).

Number of letters = T level:

T8: vena cava (IVC)

T10: (O)esophagus

T12: aortic hiatus

I ate (8) ten eggs at twelve.

C3, 4, 5 keeps the diaphragm alive.

Other bifurcations:

- The Common Carotid bifurcates at C4.
- The Trachea bifurcates at T4.
- The abdominal aorta bifurcates at L4.

## ESOPHAGUS [All are pastpapers]

Oesophagus starts at level of:	Cricoid cartilage
Esophagus narrowest at:	Cricopharyngus
Esophagus constricted at:	Where crossed by arch of aorta

## Breast [All are pastpapers]

Regarding breast:	15-20 lactiferous ducts
In a female major breast duct terminate into terminal ducts from terminal ducts it forms:	Lactiferous sinus
Terminal duct in breast form:	Lobule
Breast lies on:	Pect major

## LYMPHATICS OF BREAST [All are pastpapers]

Pectoral group of axillary nodes drain:	Major part of the breast
Breast CA involving lateral part of breast drain by:	Ant pectoral group
Upper lateral quadrant of breast is drained by which grp of nodes:	Anterior axillary lymph node
Lymph drainage from nipple of breast is to:	Anterior axillary nodes
Inner medial lower quadrant of breast doesnt drain into	Inf phrenic
Lymph node of inner breast drains into all except:	Inf phrenic nodes
Breast Medial / Lower compartment does not:	Inferior phrenic lymph nodes
Medial quadrant of breast drain into?	Internal thoracic nodes
Pectrol lymph nodes drain maximum:	Major part of breast
Lateral side of breast drains into:	Pectoral lymph nodes
Lateral quadrants of breast drain into which nodes?	Pectoral nodes.
Lymphatic drainage from nipple of breast is:	Ant axillary lymph node
Breast outer quadrant:	Pectoral (anterior) group





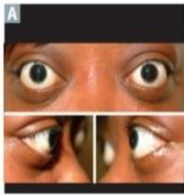For Complete List of Papers Visit our website <https://fcpsworld.com/fcps-pastpapers>

GoldStandard FCPS 4<sup>th</sup> Edition V1 (Golden 13)

**Graves Disease**

**Hyperthyroidism**

**Graves disease**



Most common cause of hyperthyroidism. Thyroid-stimulating immunoglobulin (IgG, can cause transient neonatal hyperthyroidism; type II hypersensitivity) stimulates TSH receptors on thyroid (hyperthyroidism, diffuse goiter), dermal fibroblasts (pretibial myxedema), and orbital fibroblasts (Graves orbitopathy). Activation of T-cells → lymphocytic infiltration of retroorbital space → ↑ cytokines (eg, TNF-α, IFN-γ) → ↑ fibroblast secretion of hydrophilic GAGs → ↑ osmotic muscle swelling, muscle inflammation, and adipocyte count → exophthalmos. Often presents during stress (eg, pregnancy). Associated with HLA-DR3 and HLA-B8.  
Histology: tall, crowded follicular epithelial cells; scalloped colloid.

**PAST PAPERS**

57/314

A pt with exophthalmos and other hyperthyroid features and positive anti-thyroid antibodies is suggestive of	Graves disease
Exophthalmos is due to:	Inc TSI
Most common cause of hyperthyroidism:	Graves disease
Hyperthyroid, goiter and exophthalmos:	Graves disease
common cause of hyperthyroidism?	Grave's disease
What will increase in graves disease	t3
Graves ophthalmopathy:	Optic nerve compression

Vitamin D deficiency is associated with Ophthalmopathy in patients with Graves' hyperthyroidism

Key lympho, antibody

**Hypothyroidism**

**Hashimoto thyroiditis**

Also called chronic autoimmune thyroiditis. Most common cause of hypothyroidism in iodine-sufficient regions. Associated with HLA-DR3, ↑ risk of primary thyroid lymphoma (typically diffuse large B-cell lymphoma).  
Findings: moderately enlarged, **nontender** thyroid. May be preceded by transient hyperthyroid state ("Hashitoxicosis") due to follicular rupture and thyroid hormone release.  
Serology: ⊕ antithyroid peroxidase (antimicrosomal) and antithyroglobulin antibodies.  
Histology: Hürthle cells, lymphoid aggregates with germinal centers.  
Postpartum thyroiditis—mild, self-limited variant of Hashimoto thyroiditis arising < 1 year after delivery.

A 40-year known Hypothyroidism female was referred to endocrinologist for a mass in neck. FNAC shows increased lymphocytes and serology was adviseD.What is the most probable cause?	Hashimoto thyroiditis
Female with neck swelling hypothyroid dr orders some immunologic tests?	Hashimoto thyroiditis
Female swelling infront of neck. Hypothyroid Dr orders some immunological test. What is the diagnosis?	Hashimoto thyroiditis
Diagnosis for hashimotos	Antimicrosomal and anti-thyroglobulin

A 40-year known Hypothyroidism female was referred to endocrinologist for a mass in neck. FNAC shows increased lymphocytes and serology was advised. What is the most probable cause  
Hashimoto

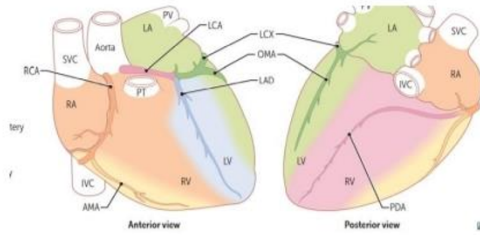




For Complete List of Papers Visit our website <https://fcpsworld.com/fcps-pastpapers>

**MI ECG LEADS**

INFARCT LOCATION	LEADS WITH ST-SEGMENT ELEVATIONS OR Q WAVES
Anteroseptal (LAD)	V <sub>1</sub> -V <sub>2</sub>
Anteroapical (distal LAD)	V <sub>3</sub> -V <sub>4</sub>
Anterolateral (LAD or LCX)	V <sub>5</sub> -V <sub>6</sub>
Lateral (LCX)	I, aVL
Inferior (RCA)	II, III, aVF
Posterior (PDA)	V <sub>7</sub> -V <sub>9</sub> , ST depression in V <sub>1</sub> -V <sub>3</sub> with tall R waves



**PAST PAPERS**

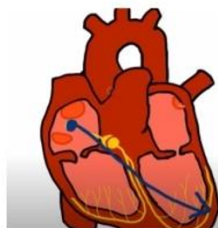
Inferior wall MI occurs due to blockage of	Right coronary artery
Post 1/3 of interventricular septum is damaged due to MI. Artery involved is?	Right coronary artery
Inferior wall MI occurs due to blockage of which artery?	Right marginal
MI of posterolateral surface of heart. Vessel involved is	Left circumflex
ECG changes in lead V4 indicated involvement of which vessel	LAD
Infarction of apex of heart, vessel thrombosed will be	LAD
The circumflex artery supplies	Left atrium and left ventricle
Infarct in the lower segment of heart	LCX
ECG shows changes in leads II, III and avF. Diagnosis	Inferior wall MI
ST elevation in lead II, which artery involved	RCA

Join FcpsWorld Online Classes and Clear exam in 1<sup>st</sup> Attempt

GoldStandard FCPS 4<sup>th</sup> Edition V1 (Golden 13)

Patient presented to ER with crushing chest pain for last 1 hour ON ECG there is ST segment elevation in lead II, III & avF what's the diagnosis	Inferior wall MI
ST segment elevation in lead II which artery effected	right main coronary
A man presents to ER with ST depressions in II, III and avF and was advised angiography. The Most likely culprit artery is	RCA
Artery involved in inferior wall MI	Right marginal
Patient having ST elevation in Lead 2 and complete heart block vessel involved	RCA

NOTE: AXIS deviation



Left axis deviation on ECG is seen in	Rt ventricular myocardial damage
---------------------------------------	----------------------------------

- ✓ [www.fcpsworld.com](http://www.fcpsworld.com) or Contact 03129684658
- ✓ Hostel Facility is also available (for those who want to join physical classes)



Www.Fcpsworld.com (Institute for Fcps & Md/Ms)

[www.facebook.com/FcpsWorld](https://www.facebook.com/FcpsWorld)

[www.facebook.com/GynaeObsWorld](https://www.facebook.com/GynaeObsWorld)

[www.facebook.com/Ophtworld](https://www.facebook.com/Ophtworld)



For Complete List of Papers Visit our website <https://fcpsworld.com/fcps-pastpapers>



- ✓ Now you can join our Online classes for MD/MS & Fcps Preparation
- ✓ Complete course in 2months including Past paper discussion
- ✓ Join from anywhere using mobile/laptop using internet
- ✓ 100% feasible with job and 100% time adjustment for students
- ✓ [www.fcpsworld.com](http://www.fcpsworld.com) or Contact 03129684658
- ✓ Hostel Facility is also available (for those who want to join physical classes)