

Www.Fcpsworld.com (Institute for Fcps & Md/Ms)

[www.facebook.com/FcpsWorld](https://www.facebook.com/FcpsWorld)

[www.facebook.com/GynaeObsWorld](https://www.facebook.com/GynaeObsWorld)

[www.facebook.com/Ophtworld](https://www.facebook.com/Ophtworld)

[www.t.me/fcps1byfcpsworld](https://www.t.me/fcps1byfcpsworld)

**FILE IS ONLY FOR CLASS STUDENTS (DO NOT SHARE)**



[www.FCPSWORLD.com](http://www.FCPSWORLD.com)

**GoldStandard FCPS (FCPS-1)**

**Surgery & Allied**

**16-June-2021 (Afternoon)**

**Recent Past Papers**

[www.facebook.com/fcpsworld](https://www.facebook.com/fcpsworld)

<https://fcpsworld.com/fcps-pastpapers>

- ✓ Clear FCPS-1 in **FIRST ATTEMPT**
- ✓ Entire course will be completed in 2 months.
- ✓ Live lectures via video Portal
- ✓ Daily Test session (Test discussion will be on Via Portal)
- ✓ Follow our complete guideline for FCPS-1
- ✓ Get Hands on 20,000 CPSP question (most of them repeat)
- ✓ Free study material, whatsapp group (only for our students)
- ✓ Don't Miss the chance. **(LIMITED SEATS AVAILABLE.)**
- ✓ **WWW.FCPSWORLD.com**
- ✓ **WWW.facebook.com/fcpsworld**
- ✓ For Details Phone# 03129684658



- ✓ Now you can join us Online for MD/MS & Fcps Preparation
- ✓ Complete course in 2months including Past paper discussion
- ✓ Join from anywhere using mobile/laptop using internet
- ✓ 100% feasible with job and 100% time adjustment for students
- ✓ [www.fcpsworld.com](http://www.fcpsworld.com) or Contact 03129684658
- ✓ Hostel Facility is also available (for those who want to join physical classes)

**FILE IS ONLY FOR CLASS STUDENTS (DO NOT SHARE)**

**(Errors and omissions excepted)**

**Cram Statements Inshallah 40 % to 60% paper will come from this file. DO not skip any file**

patient 40 weeks gestation In labor for last 25 hrs, presented with Acute Respiratory Distress syndrome having dyspnea & tachypnea, she died due to	Amniotic embolism
get all papers see link <a href="https://fcpsworld.com/fcps-pastpapers">https://fcpsworld.com/fcps-pastpapers</a>	
Drugs with short plasma half life are	Achieve steady plasma concentration quickly
55 years old person is a chronic alcoholic for 20 years. His lab shows megaloblastic anemia, treatment is	Give IV Cobalamine
Join FcpsWorld Online Classes and Clear exam in 1st Attempt (94% Passing ratio).	
Diabetic patient presents with cough productive of thick mucoid jelly like sputum has	Klebsiella
A Fisherman is presented with gingival bleeding and ecchymosis. He is suffering from:	Vit C deficiency
A boy had extraction of deciduous teeth and now profusely bleeding, missing classic hemophilia factor is	Factor 8 Minor component
Get all papers follow our fb page <a href="https://www.facebook.com/fcpsworld">www.facebook.com/fcpsworld</a>	
get all papers see link <a href="https://fcpsworld.com/fcps-pastpapers">https://fcpsworld.com/fcps-pastpapers</a>	
get all papers see link <a href="https://fcpsworld.com/fcps-pastpapers">https://fcpsworld.com/fcps-pastpapers</a>	
get all papers see link <a href="https://fcpsworld.com/fcps-pastpapers">https://fcpsworld.com/fcps-pastpapers</a>	
Intrinsic factor is secreted from part of stomach	Gastric fundus
The Slow growing thyroid tumor is	Papillary CA
Councilman bodies are characteristic of	Apoptosis
Left gastroepiploic artery arises from	Splenic
patient complains of swelling in the parotid region with pain and redness. nerve causing pain is	CN VII
anti -TB drugs are given together to	To decrease the resistance
Regarding Wilson disease, KF and jaundice is present what diagnostic test is	Ceruloplasmin
A boy falls down and fractures his Medial Epicondyle. Sensations are lost in	Loss of sensation at medial 1 /3 of



- ✓ Now you can join us Online for MD/MS & Fcps Preparation
- ✓ Complete course in 2months including Past paper discussion
- ✓ Join from anywhere using mobile/laptop using internet
- ✓ 100% feasible with job and 100% time adjustment for students
- ✓ [www.fcpsworld.com](https://www.fcpsworld.com) or Contact 03129684658
- ✓ Hostel Facility is also available (for those who want to join physical classes)

**FILE IS ONLY FOR CLASS STUDENTS (DO NOT SHARE)**

	dorsum and palmer aspect of hand
k female has ulcer on lower 1 /3rd of labia majora and labia minora, involved glands are	Greater vestibular glands
Biopsy of endocervical region of 30 year old lady using longer term IUDs shows partial stratified squamous epithelium due to phenomenon of	Metaplasia
aldosterone antagonist is	Spironolactone
Join FcpsWorld Online Classes and Clear exam in 1st Attempt (94% Passing ratio).	
The internal jugular vein is covered by	carotid sheath
A female with primary amenorrhea, webbed neck and short height has	Turner syndrome
Get all papers follow our fb page <a href="http://www.facebook.com/fcpsworld">www.facebook.com/fcpsworld</a>	
A patient presented with lymph node swelling in neck. Diagnosis of TB is confirmed by	Caseous Necrosis
Join FcpsWorld Online Classes and Clear exam in 1st Attempt (94% Passing ratio).	
abdominal tenderness in Right hypogastric region occult blood in stool. ulceration of ascending colon organism seen on histology or stool is	Entamoeba histolytica
Lymphogranuloma venereum is caused by	Chlamydia
pregnant woman used some medications for Acne & developed congenital anomaly in baby due to	Vitamin A
In a patient of Chronic Renal failure with Anemia having pallor, Edema in feet and deranged values of serum Urea, Creatinin and MCV value 86 fl. Due to reduced	Erythropoietin
Umbilical dermatome is	T10
Join FcpsWorld Online Classes and Clear exam in 1st Attempt (94% Passing ratio).	
get all papers see link <a href="https://fcpsworld.com/fcps-pastpapers">https://fcpsworld.com/fcps-pastpapers</a>	
get all papers see link <a href="https://fcpsworld.com/fcps-pastpapers">https://fcpsworld.com/fcps-pastpapers</a>	
Patient IVC is blocked just above the emergence of azygous vein. blood will divert to	Azygos vein
1st response after Vessel or Tissue injury is	Vasoconstriction
major blood vessels in brain is	Subarachnoid
A child is born with cataract. dx	Rubella
Mantoux test skin induration after 24 hrs is due to	Delayed T Cell mediated
Buy our book 'Gold Standard FCPS' (All papers arranged chapterwise, unitwise, topic wise, 1-liner) and revise 11 yrs past papers in 7 days Order at 03129684658.	
Lateral thenar muscles spared but other short muscles of hand are paralysed. it	Ulnar nerve



- ✓ Now you can join us Online for MD/MS & Fcps Preparation
- ✓ Complete course in 2 months including Past paper discussion
- ✓ Join from anywhere using mobile/laptop using internet
- ✓ 100% feasible with job and 100% time adjustment for students
- ✓ [www.fcpsworld.com](http://www.fcpsworld.com) or Contact 03129684658
- ✓ Hostel Facility is also available (for those who want to join physical classes)

**FILE IS ONLY FOR CLASS STUDENTS (DO NOT SHARE)**

is likely due to Injury of	
Mean Arterial pressure is	Diastolic+1/3pulse pressure
The most common cause of pernicious anemia is	Autoimmune Atrophic Gastritis
Get all papers follow our fb page <a href="http://www.facebook.com/fcpsworld">www.facebook.com/fcpsworld</a>	
Polycythemia Vera and splenomegaly has	Increased red cell mass
During standing from supine, which compensatory change occurs via	Inc. HR
child had a bout of flu developed widespread pinpoint skin hemorrhages. Labs show platelet count of $20 \times 10^3/u.l$ with increase megakerocytes, which appeared mononuclear and had smooth cytoplasmic contours. The symptoms disappeared spontaneously. Diagnosis is of	Acute ITP
A 50 yr male was operated for abdominal surgery. A few days after he developed pain and swelling in his right leg due to	Stasis and hypercoagulable state
Patient has myocardial infarction with an inferior infarct. he was advised angiography, on angiography most likely infarcted artery is	Right marginal artery
Buy our book 'GoldStandard FCPS'(All papers arranged chapterwise, unitwise,topic wise,1-liner) and revise 11yrs past papers in 7 days Order at 03129684658.	
Join FcpsWorld Online Classes and Clear exam in 1st Attempt (94% Passing ratio).	
Prevalance of O blood group in Caucasian population is	47%
A person has dysurea.enlarged prostate with suspected prostatic carcinoma and he has lytic lesions in the skull, route of spread is	Vertebral plexus
Get all papers follow our fb page <a href="http://www.facebook.com/fcpsworld">www.facebook.com/fcpsworld</a>	
Injury to the posterior cord of brachial plexus will damage	Deltoid
female taking analgesics presented with bleeding gums, epistaxis. fever of 101 jaundice and hepatosplenomegaly. HB 9.0, TLC 7000 , Neutropenia, Thrombocytopenia. On peripheral smear immature cells. Diagnosis is of	Acute leukemia
Valves of Great saphenous vein are	10.-12
A patient presented with lymph node swelling in neck . Diagnosis of TB will be confirmed by characteristic Microscopic finding of	Caseous Necrosis
Get all papers follow our fb page <a href="http://www.facebook.com/fcpsworld">www.facebook.com/fcpsworld</a>	
Protein synthesis occur in	RER with Ribosomes
Absence of mutation in P53 will cause	Apoptosis
patient's risk for breast cancer is increased due to	BRCA1/ BRCA 2



- ✓ Now you can join us Online for MD/MS & Fcps Preparation
- ✓ Complete course in 2months including Past paper discussion
- ✓ Join from anywhere using mobile/laptop using internet
- ✓ 100% feasible with job and 100% time adjustment for students
- ✓ [www.fcpsworld.com](http://www.fcpsworld.com) or Contact 03129684658
- ✓ Hostel Facility is also available (for those who want to join physical classes)

**FILE IS ONLY FOR CLASS STUDENTS (DO NOT SHARE)**

	Mutation
After pelvic fracture patient went into shock due to	Hemorrhage
Get all papers follow our fb page <a href="http://www.facebook.com/fcpsworld">www.facebook.com/fcpsworld</a>	
Buy our book 'GoldStandard FCPS'(All papers arranged chapterwise, unitwise,topic wise,1-liner) and revise 11yrs past papers in 7 days Order at 03129684658.	
Buy our book 'GoldStandard FCPS'(All papers arranged chapterwise, unitwise,topic wise,1-liner) and revise 11yrs past papers in 7 days Order at 03129684658.	
Join FcpsWorld Online Classes and Clear exam in 1st Attempt (94% Passing ratio).	
if whole brain stem is damaged ,remains intact	Withdrawl reflex
Get all papers follow our fb page <a href="http://www.facebook.com/fcpsworld">www.facebook.com/fcpsworld</a>	
GFR increases due to which of the following conditions?	Decresed oncotic pressure
The attachmentofliver with anterior abdominal(ventrl mesentry) wall is through	Falciform ligament
Ulnar nerve damageat medial epicondyle will result in	Hypo thenar wasting
Hypocellular bone marrow with fatty changes with severe anemia and decreased platelets counts. Patient also had Hepatitis in past. This is due to	Aplastic anemia
1 st rib fracture is associated with injury of	Subclavian artery
Get all papers follow our fb page <a href="http://www.facebook.com/fcpsworld">www.facebook.com/fcpsworld</a>	
9 month old girl vaccinated 2 weeks back now develops rash, fever. hb 13 wbc 6x10 & decreased platelet.smear shows large platelets. Diagnosis is of	ITP
The Behind sternum vertically seen structure is	Int. thoracic artery
Difference between skeletal and smooth muscle is	Ca calmodulin present in smooth muscle
Fast and sharp pain from mechanical origin is mediated by fibers	A delta
lymph from breast tissue directly goes to	Internal mammary
19 yr old boy sitting in a well ventilated room profusely sweating His pulse 120beats/min BD 150/90.would have	Mental Stress
Get all papers follow our fb page <a href="http://www.facebook.com/fcpsworld">www.facebook.com/fcpsworld</a>	
Patient with massive blood loss, B.P. 50 mm Hg. r most active and Potent response below 60 mm hg is	CNS ischemic response
Person with diarrhea, fever and abdominal tenderness in Right hypogastric region. occult blood in stool.On colonoscopy there is ulceration of ascending colon organism seen on histology or stool is	Entameoba histolytica
Reticuloendothelial system is damaged in	Histoplasmosis



- ✓ Now you can join us Online for MD/MS & Fcps Preparation
- ✓ Complete course in 2months including Past paper discussion
- ✓ Join from anywhere using mobile/laptop using internet
- ✓ 100% feasible with job and 100% time adjustment for students
- ✓ [www.fcpsworld.com](http://www.fcpsworld.com) or Contact 03129684658
- ✓ Hostel Facility is also available (for those who want to join physical classes)

**FILE IS ONLY FOR CLASS STUDENTS (DO NOT SHARE)**

most common Cause of UTI in community is	Ecoli
Parotid duct is also known as	Stenson's duct
In a rock crusher Upperlobelesion was noted in right lung with birefringent particles due to	Silicosis
get all papers see link <a href="https://fcpsworld.com/fcps-pastpapers">https://fcpsworld.com/fcps-pastpapers</a>	
posterior column tract doesn't carry	Crude touch
The reticuloendothelial system is affected by	Histoplasmosis
A 50 yr male with Macrocytic anemia is pale and lethargic. He has H/O Gastrectomy for Zollinger-Ellison Syndrome . Treatment of chice is	IV vitamin B12
posterior auricular area is supplied by	Lesser occipital nerve
A 30 year old male was brought to emergency in state of shock with failing heart. neurotransmitter that relievev pain is	Dopamine
Get all papers follow our fb page <a href="http://www.facebook.com/fcpsworld">www.facebook.com/fcpsworld</a>	
get all papers see link <a href="https://fcpsworld.com/fcps-pastpapers">https://fcpsworld.com/fcps-pastpapers</a>	
Actin is boundto Z line by	Actinin
The Slow growing thyroid tumor is	Papillary CA
After partial hepatectomyliver tissues regenerate in	15-25 days
renal clearance of Ca ions is due to	Chlorothiazide therapy
get all papers see link <a href="https://fcpsworld.com/fcps-pastpapers">https://fcpsworld.com/fcps-pastpapers</a>	
After a road traffic accident the patient got his fibular neck fractured and now unable to dorsiflex and evert foot. Damage occurred to	Common peroneal nerve
In fasting during summerurine osmolarity is increased due to	ADH
Buy our book 'GoldStandard FCPS'(All papers arranged chapterwise, unitwise,topic wise,1-liner) and revise 11yrs past papers in 7 days Order at 03129684658.	
In adductor canal structure most likely affected by pus is	Femoral vein
structures in the kidneyis responsible for sensing inadequate perfusion and secreting renin is	JG cells
Old man with tremors lesion must be in	Substance nigra
Epithelium modification in small intestine is	Microvilli
After a road traffic accident the patient got his fibular neck fractured and now unable to dorsiflex and evert foot. Damage occurred to	Common peroneal nerve
Teacher could not differentiate between colors Is caused by	Absent cones
Join FcpsWorld Online Classes and Clear exam in 1st Attempt (94% Passing ratio).	
Join FcpsWorld Online Classes and Clear exam in 1st Attempt (94% Passing ratio).	



- ✓ Now you can join us Online for MD/MS & Fcps Preparation
- ✓ Complete course in 2months including Past paper discussion
- ✓ Join from anywhere using mobile/laptop using internet
- ✓ 100% feasible with job and 100% time adjustment for students
- ✓ [www.fcpsworld.com](http://www.fcpsworld.com) or Contact 03129684658
- ✓ Hostel Facility is also available (for those who want to join physical classes)

**FILE IS ONLY FOR CLASS STUDENTS (DO NOT SHARE)**

get all papers see link <a href="https://fcpsworld.com/fcps-pastpapers">https://fcpsworld.com/fcps-pastpapers</a>	
The lymph veins of prostate drains into	Internal iliac nodes
Free radicals formed by radiation will damage the cell's	DNA
Pancreaticosplenic lymph nodes receive lymphatics from the part of the stomach supplied by the vessels	Short gastric arteries and left gastroepiploic artery
TMJ joint dislocated the position of condyloid of mandible is	Anteriorly to anterior tubercle
Join FcpsWorld Online Classes and Clear exam in 1st Attempt (94% Passing ratio).	
get all papers see link <a href="https://fcpsworld.com/fcps-pastpapers">https://fcpsworld.com/fcps-pastpapers</a>	
get all papers see link <a href="https://fcpsworld.com/fcps-pastpapers">https://fcpsworld.com/fcps-pastpapers</a>	
Treatment of cryptococcus neoformans meningitis is	Amphotericin B
Distribution of blood flow is mainly regulated by	Arterioles
Patient presented with severe diarrhea. What infusion will be given to increase his ECF and decrease ICF and causing plasma expansion after osmotic equilibrium:	1 litre of 3% NaCl solution
In liver & Kidneys necrosis is of	Coagulative necrosis
unable to dorsiflex and evert foot. Damage occurred to	Common peroneal nerve
Get all papers follow our fb page <a href="https://www.facebook.com/fcpsworld">www.facebook.com/fcpsworld</a>	
Personis lying naked in a room temp.heatloss occurs via	Radiation & conduction
A person can't scratch his back due to muscle involvement of	Latismus Dorsi
get all papers see link <a href="https://fcpsworld.com/fcps-pastpapers">https://fcpsworld.com/fcps-pastpapers</a>	
A patient presentedwith bilateral massesin lungs, his serum AFP wasraised and he has pale skin due to	HCC
get all papers see link <a href="https://fcpsworld.com/fcps-pastpapers">https://fcpsworld.com/fcps-pastpapers</a>	
Join FcpsWorld Online Classes and Clear exam in 1st Attempt (94% Passing ratio).	
taking thyroxin tablets for losing weight. The parameter which shows an increase is	Serum free T4
The Lymph from Appendix is drained into	Sup. Mesenteric
Normal MCV MCHC MCHOccurs in	Blood loss 2 days before
Nerve involved in cremastaric reflex is	Ilioinguinalnerve
Thyroglossal duct cyst is invested in	Pretracheal fascia



- ✓ Now you can join us Online for MD/MS & Fcps Preparation
- ✓ Complete course in 2months including Past paper discussion
- ✓ Join from anywhere using mobile/laptop using internet
- ✓ 100% feasible with job and 100% time adjustment for students
- ✓ [www.fcpsworld.com](https://www.fcpsworld.com) or Contact 03129684658
- ✓ Hostel Facility is also available (for those who want to join physical classes)

Www.Fcpsworld.com (Institute for Fcps & Md/Ms)

[www.facebook.com/FcpsWorld](https://www.facebook.com/FcpsWorld)

[www.facebook.com/GynaeObsWorld](https://www.facebook.com/GynaeObsWorld)

[www.facebook.com/Ophtworld](https://www.facebook.com/Ophtworld)

[www.t.me/fcps1byfcpsworld](http://www.t.me/fcps1byfcpsworld)



**FILE IS ONLY FOR CLASS STUDENTS (DO NOT SHARE)**

A female presented with history of vaginal bleeding histology show cystic hyperplasia of endometrium due to	Prolong estrogen stimulation
Virulence of bacteria depends upon	Type of toxin
Join FcpsWorld Online Classes and Clear exam in 1st Attempt (94% Passing ratio).	
A person has dysurea. He has enlarged prostate with suspected prostatic carcinoma and he has lytic lesions in the skull, route of spread is	Vertebral plexus
Corticospinal fibers decussate at the level of	Medulla oblongata
Join FcpsWorld Online Classes and Clear exam in 1st Attempt (94% Passing ratio).	
If circumflex branch of left coronary artery is blocked affected area is	Posterior surface of left ventricle
Adductor muscles are supplied by	Obturator
Pyramidal tract is related to	Motor function
A labourer due to excessive sweating has lost 2L water developed severe dehydration and replaced by 2L pure water. Fluids will	Inc. ICF volume



- ✓ Now you can join us Online for MD/MS & Fcps Preparation
- ✓ Complete course in 2 months including Past paper discussion
- ✓ Join from anywhere using mobile/laptop using internet
- ✓ 100% feasible with job and 100% time adjustment for students
- ✓ [www.fcpsworld.com](http://www.fcpsworld.com) or Contact 03129684658
- ✓ Hostel Facility is also available (for those who want to join physical classes)



Www.Fcpsworld.com (Institute for Fcps & Md/Ms)



[www.facebook.com/FcpsWorld](http://www.facebook.com/FcpsWorld)

[www.facebook.com/GynaeObsWorld](http://www.facebook.com/GynaeObsWorld)

[www.facebook.com/Ophtworld](http://www.facebook.com/Ophtworld)

[www.t.me/fcps1byfcpsworld](http://www.t.me/fcps1byfcpsworld)

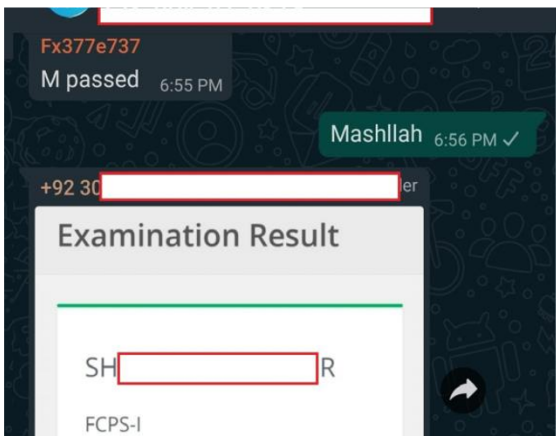
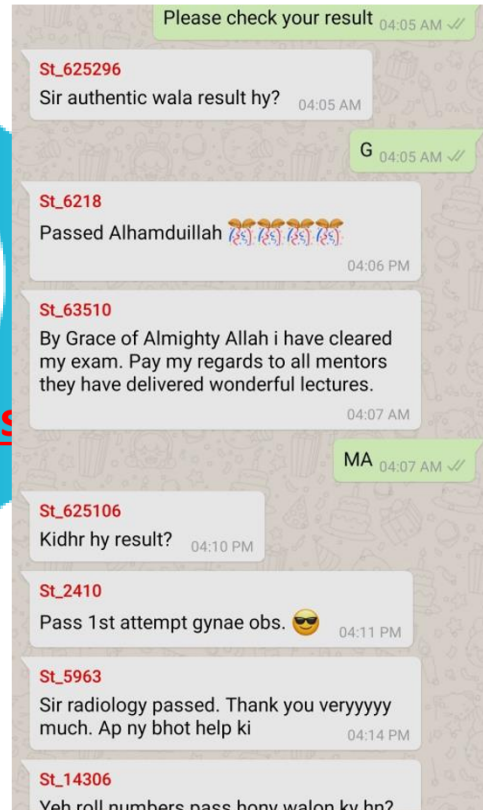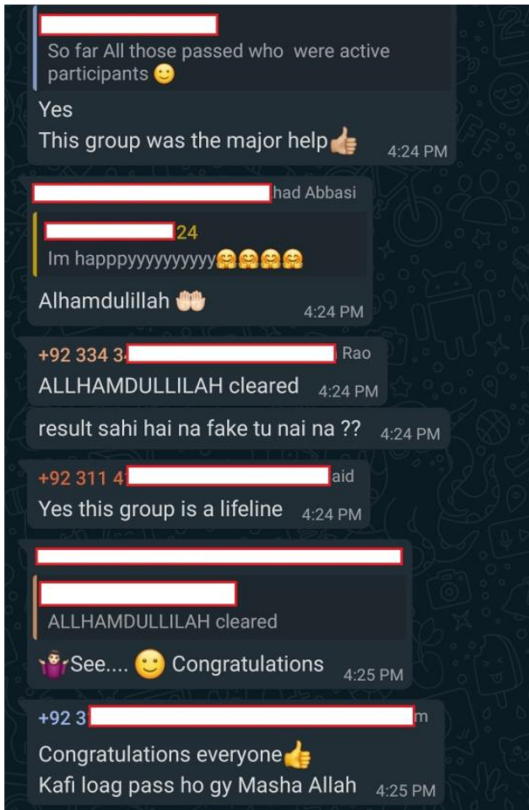
**FILE IS ONLY FOR CLASS STUDENTS (DO NOT SHARE)**

[Join FcpsWorld Telegram group](#)

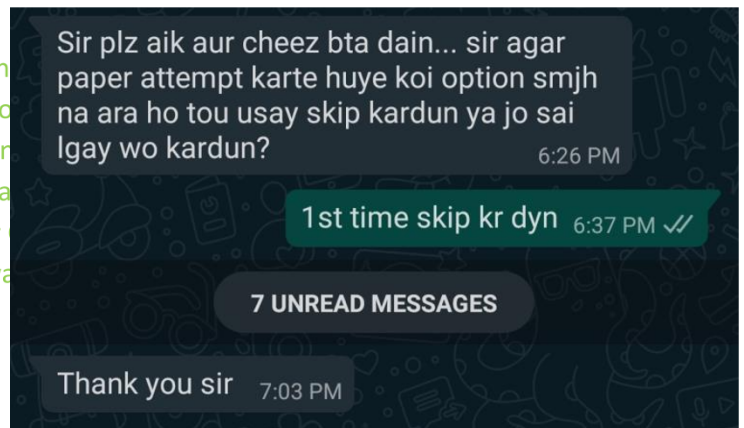
[www.t.me/fcps1byfcpsworld](http://www.t.me/fcps1byfcpsworld)

**AND**

**❖ Whatsapp 03129684658 to join whatsapp group of your speciality**



an join us On  
course in 2mo  
anywhere usin  
ible with job a  
world.com or  
ility is also av



Www.Fcpsworld.com (Institute for Fcps & Md/Ms)

[www.facebook.com/FcpsWorld](https://www.facebook.com/FcpsWorld)

[www.facebook.com/GynaeObsWorld](https://www.facebook.com/GynaeObsWorld)

[www.facebook.com/Ophtworld](https://www.facebook.com/Ophtworld)

[www.t.me/fcps1byfcpsworld](https://www.t.me/fcps1byfcpsworld)

**FILE IS ONLY FOR CLASS STUDENTS (DO NOT SHARE)**



**& Many More Success Stories**



- ✓ Now you can join us Online for MD/MS & Fcps Preparation
- ✓ Complete course in 2months including Past paper discussion
- ✓ Join from anywhere using mobile/laptop using internet
- ✓ 100% feasible with job and 100% time adjustment for students
- ✓ [www.fcpsworld.com](http://www.fcpsworld.com) or Contact 03129684658
- ✓ Hostel Facility is also available (for those who want to join physical classes)

Www.Fcpsworld.com (Institute for Fcps & Md/Ms)

[www.facebook.com/FcpsWorld](https://www.facebook.com/FcpsWorld)

[www.facebook.com/GynaeObsWorld](https://www.facebook.com/GynaeObsWorld)

[www.facebook.com/Ophtworld](https://www.facebook.com/Ophtworld)

[www.t.me/fcps1byfcpsworld](https://www.t.me/fcps1byfcpsworld)



**FILE IS ONLY FOR CLASS STUDENTS (DO NOT SHARE)**

# FCPS-1 ONLINE COURSE

Join FcpsWorld Online preparation courses and clear exam in 1st Attempt.

[WWW.FCPSWORLD.COM](http://WWW.FCPSWORLD.COM)



Fcpsworld



[www.fcpsworld.com](http://www.fcpsworld.com)



- ✓ Now you can join us Online for MD/MS & Fcps Preparation
- ✓ Complete course in 2months including Past paper discussion
- ✓ Join from anywhere using mobile/laptop using internet
- ✓ 100% feasible with job and 100% time adjustment for students
- ✓ [www.fcpsworld.com](http://www.fcpsworld.com) or Contact 03129684658
- ✓ Hostel Facility is also available (for those who want to join physical classes)

Www.Fcpsworld.com (Institute for Fcps & Md/Ms)

[www.facebook.com/FcpsWorld](http://www.facebook.com/FcpsWorld)

[www.facebook.com/GynaeObsWorld](http://www.facebook.com/GynaeObsWorld)

[www.facebook.com/Ophtworld](http://www.facebook.com/Ophtworld)

[www.t.me/fcps1byfcpsworld](http://www.t.me/fcps1byfcpsworld)



**FILE IS ONLY FOR CLASS STUDENTS (DO NOT SHARE)**



## GoldStandard FCPS



- ✓ Now you can join us Online for MD/MS & Fcps Preparation
- ✓ Complete course in 2months including Past paper discussion
- ✓ Join from anywhere using mobile/laptop using internet
- ✓ 100% feasible with job and 100% time adjustment for students
- ✓ [www.fcpsworld.com](http://www.fcpsworld.com) or Contact 03129684658
- ✓ Hostel Facility is also available (for those who want to join physical classes)

Www.Fcpsworld.com (Institute for Fcps & Md/Ms)

[www.facebook.com/FcpsWorld](https://www.facebook.com/FcpsWorld)

[www.facebook.com/GynaeObsWorld](https://www.facebook.com/GynaeObsWorld)

[www.facebook.com/Ophtworld](https://www.facebook.com/Ophtworld)

[www.t.me/fcps1byfcpsworld](https://www.t.me/fcps1byfcpsworld)



**FILE IS ONLY FOR CLASS STUDENTS (DO NOT SHARE)**

- ✓ Feb 2021 papers (recent updated)
- ✓ Authentic most repeated papers.
- ✓ MCQs with explanation and reference.
- ✓ 1 liner for rapid revision. (Cram them)
- ✓ Clear FCPS-1 in 1st Attempt (Dont miss chance)
- ✓ Free Cash on Delivery **Order at 03129684658**



- ✓ Now you can join us Online for MD/MS & Fcps Preparation
- ✓ Complete course in 2months including Past paper discussion
- ✓ Join from anywhere using mobile/laptop using internet
- ✓ 100% feasible with job and 100% time adjustment for students
- ✓ [www.fcpsworld.com](http://www.fcpsworld.com) or Contact 03129684658
- ✓ Hostel Facility is also available (for those who want to join physical classes)