

Www.Fcpsworld.com (Institute for Fcps & Md/Ms)

[www.facebook.com/FcpsWorld](https://www.facebook.com/FcpsWorld)

[www.facebook.com/GynaeObsWorld](https://www.facebook.com/GynaeObsWorld)

[www.facebook.com/Ophtworld](https://www.facebook.com/Ophtworld)

[www.t.me/fcps1byfcpsworld](https://www.t.me/fcps1byfcpsworld)

**FILE IS ONLY FOR CLASS STUDENTS (DO NOT SHARE)**



[www.FCPSWORLD.com](http://www.FCPSWORLD.com)

**GoldStandard FCPS (FCPS-1)**

**Surgery & Allied**

**15-June-2021 (Afternoon)**

**Recent Past Papers**

[www.facebook.com/fcpsworld](https://www.facebook.com/fcpsworld)

<https://fcpsworld.com/fcps-pastpapers>

- ✓ Clear FCPS-1 in **FIRST ATTEMPT**
- ✓ Entire course will be completed in 2 months.
- ✓ Live lectures via video Portal
- ✓ Daily Test session (Test discussion will be on Via Portal)
- ✓ Follow our complete guideline for FCPS-1
- ✓ Get Hands on 20,000 CPSP question (most of them repeat)
- ✓ Free study material, whatsapp group (only for our students)
- ✓ Don't Miss the chance. **(LIMITED SEATS AVAILABLE.)**
- ✓ **WWW.FCPSWORLD.com**
- ✓ **WWW.facebook.com/fcpsworld**
- ✓ For Details Phone# 03129684658




- ✓ Now you can join us Online for MD/MS & Fcps Preparation
- ✓ Complete course in 2months including Past paper discussion
- ✓ Join from anywhere using mobile/laptop using internet
- ✓ 100% feasible with job and 100% time adjustment for students
- ✓ [www.fcpsworld.com](http://www.fcpsworld.com) or Contact 03129684658
- ✓ Hostel Facility is also available (for those who want to join physical classes)

**FILE IS ONLY FOR CLASS STUDENTS (DO NOT SHARE)**

**(Errors and omissions excepted)**

**Cram Statements Inshallah 40 % to 60% paper will come from this file. DO not skip any file**

Loss of pain and temp sensation but intact touch sensation occurred in	Syringomyelia
In surgical neck of humerus fracture, there is loss of abduction(arm hanging) and proximal upper arm lateral side sensations are lost. Nerve damaged is	Axillary nerve
A young boy having vomiting fever and abdominal pain due to	Enterotoxins
The arterial pulse which is palpable on radial artery is due to	Pulse pressure which pushes the arterial wall
Injury to hippocampus will cause	New memory formation loss
hormone remain Normalin pregnancy is	Growth Hormone
Causative organism of new born with meningitis is	Strep agalatace
Alpha feto protein are associated with	HCC
Buy our book 'GoldStandard FCPS'(All papers arranged chapterwise, unitwise,topic wise,1-liner) and revise 11yrs past papers in 7 days Order at 03129684658.	
Kidney doesn't reabsorb	Inulin
MCV would remain normal in	Acute blood loss after 2 days
Pain and temperature transmitted by	Lateral spinothalamic
get all papers see link <a href="https://fcpsworld.com/fcps-pastpapers">https://fcpsworld.com/fcps-pastpapers</a>	
	
The muscle increases the transverse and antero-posterior diameter of the thorax during quiet respiration is	External intercostal muscles
A boy falls down and fractures his Medial Epicondyle. Sensations are lost in	Loss of sensation at medial 1/3 of dorum and palmer aspect of hand
Get all papers follow our fb page <a href="http://www.facebook.com/fcpsworld">www.facebook.com/fcpsworld</a>	
In Scleroderma cyanosis of nail and fingers is due to	Raynaud's phenomenon
A chronic smoker developed Dysphagia for solids and Wt. Loss due to	Nerve Injured
asked to stand on his right foot, his left hip drops, nerves most likely damaged is	Right superior gluteal
Most radio sensitive tumor is	Seminoma
The Growth of lobules and Alveoli in breast is caused by	Progesterone



- ✓ Now you can join us Online for MD/MS & Fcps Preparation
- ✓ Complete course in 2months including Past paper discussion
- ✓ Join from anywhere using mobile/laptop using internet
- ✓ 100% feasible with job and 100% time adjustment for students
- ✓ [www.fcpsworld.com](http://www.fcpsworld.com) or Contact 03129684658
- ✓ Hostel Facility is also available (for those who want to join physical classes)

**FILE IS ONLY FOR CLASS STUDENTS (DO NOT SHARE)**


Cyanide poisoning leads to inhibition of	Inhibition of cytochrome oxidation
Parasitic infection raises	Eosinophils
The Common bile duct is related to pancreas at	Posterior
In VWD disease effective treatment is	Cryoprecipitate
Bleeding per vagina discharge. On histology squamous metaplasia and koilocytosis was Present cause is	HPV
Buy our book 'GoldStandard FCPS'(All papers arranged chapterwise, unitwise,topic wise,1-liner) and revise 11yrs past papers in 7 days Order at 03129684658.	
Join FcpsWorld Online Classes and Clear exam in 1st Attempt (94% Passing ratio).	
get all papers see link <a href="https://fcpsworld.com/fcps-pastpapers">https://fcpsworld.com/fcps-pastpapers</a>	
Join FcpsWorld Online Classes and Clear exam in 1st Attempt (94% Passing ratio).	
asthma in 20 yr. old male has	FEV1/FVC less than 65%
Aflatoxin are associated with	HCC
innate immunity contains	NK cells
Type of defect in Hereditary spherocytosis is	Structural defect due to Spectrin
Buy our book 'GoldStandard FCPS'(All papers arranged chapterwise, unitwise,topic wise,1-liner) and revise 11yrs past papers in 7 days Order at 03129684658.	
An isolated complete rupture of anterior cruciate ligament will result in instability of tibia over femur. The direction of instability will be	Anterior
Get all papers follow our fb page <a href="http://www.facebook.com/fcpsworld">www.facebook.com/fcpsworld</a>	
Young sexually active male with yellowish penile discharge, painful micturition having suprapubic & testicular pain, urine showed 20 to 30 WBC . N gonorrhoea negative most likely organism is	Chlamydia
Organism which produces fluorescent pigments and resistant to antibiotic & antiseptic is	Pseudomonas
Earliest sign of vitamin A deficiency is	Conjunctiva, Xerosis
Get all papers follow our fb page <a href="http://www.facebook.com/fcpsworld">www.facebook.com/fcpsworld</a>	
Buy our book 'GoldStandard FCPS'(All papers arranged chapterwise, unitwise,topic wise,1-liner) and revise 11yrs past papers in 7 days Order at 03129684658.	
The lesser omentum free margin contains	Portal vein, bile duct & hepatic artery
Liquefactive necrosis involves	Brain
dwarfism due to short limbs & normal height of the trunk, no signs or symptoms suggestive of mental retardation. Pattern of development of	Autosomal dominant inheritance



- ✓ Now you can join us Online for MD/MS & Fcps Preparation
- ✓ Complete course in 2 months including Past paper discussion
- ✓ Join from anywhere using mobile/laptop using internet
- ✓ 100% feasible with job and 100% time adjustment for students
- ✓ [www.fcpsworld.com](http://www.fcpsworld.com) or Contact 03129684658
- ✓ Hostel Facility is also available (for those who want to join physical classes)

**FILE IS ONLY FOR CLASS STUDENTS (DO NOT SHARE)**

dwarfism is	
Buy our book 'GoldStandard FCPS'(All papers arranged chapterwise, unitwise,topic wise,1-liner) and revise 11yrs past papers in 7 days Order at 03129684658.	
Major blood vessels are in layer of brain coverings at	Subarachnoid space
get all papers see link <a href="https://fcpsworld.com/fcps-pastpapers">https://fcpsworld.com/fcps-pastpapers</a>	
least distensible/dilatable part of urethra is	Membranouspart
Get all papers follow our fb page <a href="http://www.facebook.com/fcpsworld">www.facebook.com/fcpsworld</a>	
The muscle unlocking of knee joint is.	Popliteus
.Best way to monitor recurrence of colon cancer after colonoscopy is	CEA levels
Stress Hormone that cause Vasoconstriction is	Adrenaline
parasite having small anterior end and invades the out mucosa that is	Trichuris trichiura
Most important source of vitamin K is	Green vegetabless
get all papers see link <a href="https://fcpsworld.com/fcps-pastpapers">https://fcpsworld.com/fcps-pastpapers</a>	
The Deep inguinal ring is located in	Transversalis fascia
Difference between PCT & DCT is	Brush border
Primary oocyte surrounding noncellular layer is	Zona pellucida
Muscle arise from 3rd pharyngeal arch is	Stylopharyngeus
Rregarding epithelium	Male urethra pseudostratified columnar
Outer lateral quadrant of breast drains to	Anterior (pectoral) lymph nodes
Buy our book 'GoldStandard FCPS'(All papers arranged chapterwise, unitwise,topic wise,1-liner) and revise 11yrs past papers in 7 days Order at 03129684658.	
Apoenurosis of transversus abdominis form	Conjoint tendon
Patient with hsv keratoconjunctivitis.treatment should be	Trifluridine
Child engulfed peanut,became suddenly cynosedandstarted coughing the most commonregion .foreign body gets stuck in	Right inferior lobe
ST elevation in chest lead 4 affects	LAD
During moderate level of exercise.blood flow to brain	Remain unchanged
Buy our book 'GoldStandard FCPS'(All papers arranged chapterwise, unitwise,topic wise,1-liner) and revise 11yrs past papers in 7 days Order at 03129684658.	
Ulnar nerve damage Result in	Loss of 2 medial



- ✓ Now you can join us Online for MD/MS & Fcps Preparation
- ✓ Complete course in 2months including Past paper discussion
- ✓ Join from anywhere using mobile/laptop using internet
- ✓ 100% feasible with job and 100% time adjustment for students
- ✓ [www.fcpsworld.com](http://www.fcpsworld.com) or Contact 03129684658
- ✓ Hostel Facility is also available (for those who want to join physical classes)



**FILE IS ONLY FOR CLASS STUDENTS (DO NOT SHARE)**

	lumbricals
Female having non cancerous solid mobile mass in breast is	Fibroadenoma
Primary objective of Screening in cancer is	Detect disease at early stage
The internal spermatic fascia is derived from	Rascia transversalis
Across the cell membrane diffusion increases due to	Lipid solubility
A patient after bone marrow transplant, develops chest infection. Pneumonia is suspected. In sputum, there are cells with large oval inclusion bodies due to	CMV
Vitamin D resistant Rickets is	Malabsorption syndrome
Submucosal Brunner's glands are presented in	Duodenum
Max Two point discrimination is present on	Finger tips
wrist joint movement doesn't occur due to	Brachioradialis muscle
Join FcpsWorld Online Classes and Clear exam in 1st Attempt (94% Passing ratio).	
parasite with associated respiratory symptoms is	Ascariasis
In postural hypotension raising patient from supine position leads to	Inc. HR
Buy our book 'Gold Standard FCPS' (All papers arranged chapterwise, unitwise, topic wise, 1-liner) and revise 11 yrs past papers in 7 days Order at 03129684658.	
Join FcpsWorld Online Classes and Clear exam in 1st Attempt (94% Passing ratio).	
Get all papers follow our fb page <a href="http://www.facebook.com/fcpsworld">www.facebook.com/fcpsworld</a>	
Pulmonary infarction is due to	Small artery emboli
Decrease colour vision is due to loss of	Cones
Epithelioid cells are characteristics of inflammation/necrosis that is	Granulomatous
Which of the following is benign tumor?	Warthin tumor
Most common cause of physiological hypoxemia is	V/Q mismatch
Join FcpsWorld Online Classes and Clear exam in 1st Attempt (94% Passing ratio).	
Cranial nerve VII, IX, X taking taste sensation converge into	Solitary tract
Farmer with linear pigmentation of foot	Cutaneous larva migrans
The most common cause of pernicious anemia is	Autoimmune Atrophic Gastritis
get all papers see link <a href="https://fcpsworld.com/fcps-pastpapers">https://fcpsworld.com/fcps-pastpapers</a>	
Pseudomonas	Alpha 1 antitrypsin deficiency
Most radio sensitive is which of the following	Lymph Node



- ✓ Now you can join us Online for MD/MS & Fcps Preparation
- ✓ Complete course in 2 months including Past paper discussion
- ✓ Join from anywhere using mobile/laptop using internet
- ✓ 100% feasible with job and 100% time adjustment for students
- ✓ [www.fcpsworld.com](http://www.fcpsworld.com) or Contact 03129684658
- ✓ Hostel Facility is also available (for those who want to join physical classes)

**FILE IS ONLY FOR CLASS STUDENTS (DO NOT SHARE)**

In thyroid disease antibodies are directed against	Thyroglobulin.
Buy our book 'GoldStandard FCPS'(All papers arranged chapterwise, unitwise,topic wise,1-liner) and revise 11yrs past papers in 7 days Order at 03129684658.	
A baby came with intestinal obstruction and diagnosed to have Hirschsprung disease involved segment is	S2,3
First Pass effect is avoided and Bioavailibility is improved when drug is given	Sublingual
The Spermogenesis is stimulated by	FSH and testosterone
SA node acts as pacemaker due to	Located in Right Artrium
Weight of prostate in adult is nearly	20 gram
The lumen of uterine cavity is obliterated by fusion of	_Decidua capsularis and decidua parietalis
Increase in both PT and APTT is seen in	CLD
Buy our book 'GoldStandard FCPS'(All papers arranged chapterwise, unitwise,topic wise,1-liner) and revise 11yrs past papers in 7 days Order at 03129684658.	
get all papers see link <a href="https://fcpsworld.com/fcps-pastpapers">https://fcpsworld.com/fcps-pastpapers</a>	
Therapeutic and adverseeffect of loop diuretics is	Low blood volume
Get all papers follow our fb page <a href="http://www.facebook.com/fcpsworld">www.facebook.com/fcpsworld</a>	
Get all papers follow our fb page <a href="http://www.facebook.com/fcpsworld">www.facebook.com/fcpsworld</a>	
Buy our book 'GoldStandard FCPS'(All papers arranged chapterwise, unitwise,topic wise,1-liner) and revise 11yrs past papers in 7 days Order at 03129684658.	
get all papers see link <a href="https://fcpsworld.com/fcps-pastpapers">https://fcpsworld.com/fcps-pastpapers</a>	
during toracotomy the first damage muscles are	Intercostal muscles
Natural antithrombotic in blood is	Heparin
Young patient presented with jaundice.His Total bilirubin is 1.1 mg/dl and conjugated bilirubin is 1.2 mg/dl. The jaundice is due to	Unconjugated hyperbilirubinemia due to hemolysis
Most lethal Pre-malignant lesion of the oral cavity is	Erythroplakia
Get all papers follow our fb page <a href="http://www.facebook.com/fcpsworld">www.facebook.com/fcpsworld</a>	
Lumbertriangle anteriorly bound by posterior border of	Pot borderof External oblique
Result of positive screening test came positive and negative screening test came negative after the confirmatory test shows quality of screening test that is	Specificity



- ✓ Now you can join us Online for MD/MS & Fcps Preparation
- ✓ Complete course in 2months including Past paper discussion
- ✓ Join from anywhere using mobile/laptop using internet
- ✓ 100% feasible with job and 100% time adjustment for students
- ✓ [www.fcpsworld.com](http://www.fcpsworld.com) or Contact 03129684658
- ✓ Hostel Facility is also available (for those who want to join physical classes)

**FILE IS ONLY FOR CLASS STUDENTS (DO NOT SHARE)**

Join FcpsWorld Online Classes and Clear exam in 1st Attempt (94% Passing ratio).	
Buy our book 'GoldStandard FCPS'(All papers arranged chapterwise, unitwise,topic wise,1-liner) and revise 11yrs past papers in 7 days Order at 03129684658.	
Lady with loss of blood about 1500ml. after few days her serum ACTH level was low and later it was found that her adrenal gland size was reduced, what is the cause	Atrophy of cortex
C wave shows	Closure of mitral and tricuspid valve
it might be difficult to perform surgery on right adrenal due to relation of right adrenal with	IVC
due to pituitary tumor type of vision loss is	Bilateral temporal hemianopia
Join FcpsWorld Online Classes and Clear exam in 1st Attempt (94% Passing ratio).	
Clara cells present in	Terminal bronchioles
Buy our book 'GoldStandard FCPS'(All papers arranged chapterwise, unitwise,topic wise,1-liner) and revise 11yrs past papers in 7 days Order at 03129684658.	
Female hand cut with knife, doesn't heal properly since last two weeks, presented with fever, Hb 8gm/dl, RBS 130 mg/dl cause is	Infection
A chronic smoker & Alcoholic is having Ulcer on inner lip margin which is indurated and pale. oral ulcer can leads to	Squamous cell carcinoma
Heavy smoker complains Reveals fungating mass obstructing medium sized bronchus.	Squamous cell carcinoma
Infusion 140 meq Na in 1000 ml water will cause	Dec osmolarity of ICF
Buy our book 'GoldStandard FCPS'(All papers arranged chapterwise, unitwise,topic wise,1-liner) and revise 11yrs past papers in 7 days Order at 03129684658.	
Long thoracic got cut resulting in loss of over head abduction and winging of scapula due too damage oof	Serratus anterior
Rapid ventricular filling when Contraction of atria over incompetentvalve is accompanied by	3rd Heart Sound
Buy our book 'GoldStandard FCPS'(All papers arranged chapterwise, unitwise,topic wise,1-liner) and revise 11yrs past papers in 7 days Order at 03129684658.	
complications regarding the procedure on patient are prevented by	Informed consent
A man with presented stroke, with affectedACA area of brain DAMAGE IS	Primary Motor area
A patient has calf muscle pain relieved on rest artery involved is	Popliteal
get all papers see link <a href="https://fcpsworld.com/fcps-pastpapers">https://fcpsworld.com/fcps-pastpapers</a>	
Cut at anatomical snuff box with profuse bleeding is seen in damageof	Radial artery



- ✓ Now you can join us Online for MD/MS & Fcps Preparation
- ✓ Complete course in 2months including Past paper discussion
- ✓ Join from anywhere using mobile/laptop using internet
- ✓ 100% feasible with job and 100% time adjustment for students
- ✓ [www.fcpsworld.com](http://www.fcpsworld.com) or Contact 03129684658
- ✓ Hostel Facility is also available (for those who want to join physical classes)



[www.facebook.com/FcpsWorld](http://www.facebook.com/FcpsWorld)

[www.facebook.com/GynaeObsWorld](http://www.facebook.com/GynaeObsWorld)

[www.facebook.com/Ophtworld](http://www.facebook.com/Ophtworld)

[www.t.me/fcps1byfcpsworld](http://www.t.me/fcps1byfcpsworld)

**FILE IS ONLY FOR CLASS STUDENTS (DO NOT SHARE)**

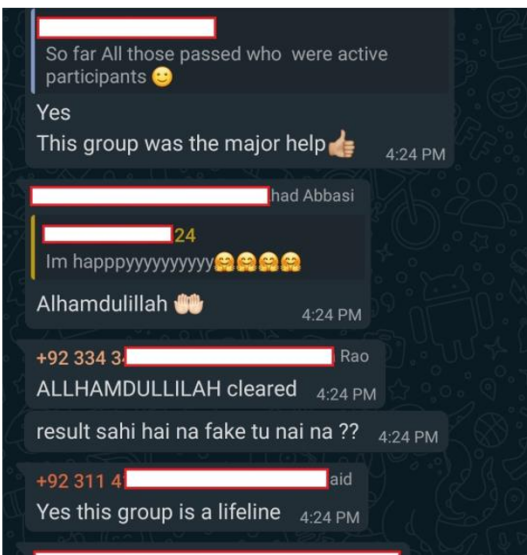
Join FcpsWorld Online Classes and Clear exam in 1st Attempt (94% Passing ratio).	
Bleeding per vagina discharge., squamous metaplasia and koilocytosis was Present-Most likely cause is	HPV
Hepatoduodenal ligament doesn't transmits	Hepatic plexus
Mean Arterial pressure depends upon function of the lung is	CO and TPR Conversion of angiotensin to angiotensin II
Deep cervical artery is branch of	Costocervical trunk
Chi-squaretest is used to measure the degree of	Association between two variables.
Get all papers follow our fb page <a href="http://www.facebook.com/fcpsworld">www.facebook.com/fcpsworld</a>	
A patient is chronic alcoholic and has developed CLD with cirrhosis, his PT & APTT are prolonged with developing bruises, beneficial drug is	Vitamin K
Join FcpsWorld Online Classes and Clear exam in 1st Attempt (94% Passing ratio).	
get all papers see link <a href="https://fcpsworld.com/fcps-pastpapers">https://fcpsworld.com/fcps-pastpapers</a>	
Buy our book 'GoldStandard FCPS'(All papers arranged chapterwise, unitwise,topic wise,1-liner) and revise 11yrs past papers in 7 days Order at 03129684658.	
Most serious effect of Estrogen in women on prolonged HRT or using Oral Contraceptives is	Thromboembolism

[Join FcpsWorld Telegram group](https://t.me/fcps1byfcpsworld)

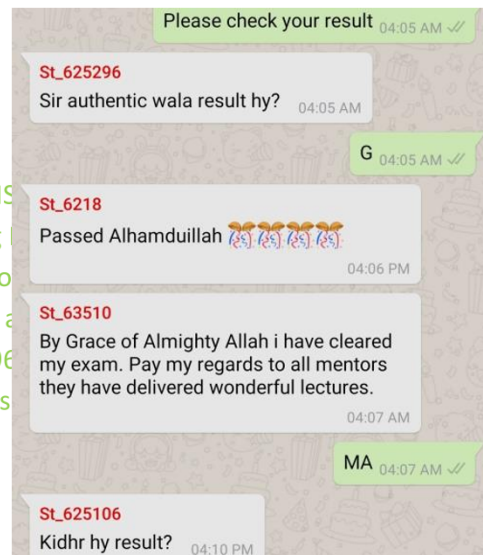[www.t.me/fcps1byfcpsworld](http://www.t.me/fcps1byfcpsworld)

**AND**

**❖ Whatsapp 03129684658 to join whatsapp group of your specialty**



can join us Online for MD/MS  
the course in 2months including  
anywhere using mobile/lapto  
asible with job and 100% time a  
psworld.com or Contact 031296  
acility is also available (for thos





Www.Fcpsworld.com (Institute for Fcps & Md/Ms)

[www.facebook.com/FcpsWorld](http://www.facebook.com/FcpsWorld)

[www.facebook.com/GynaeObsWorld](http://www.facebook.com/GynaeObsWorld)

[www.facebook.com/Ophtworld](http://www.facebook.com/Ophtworld)

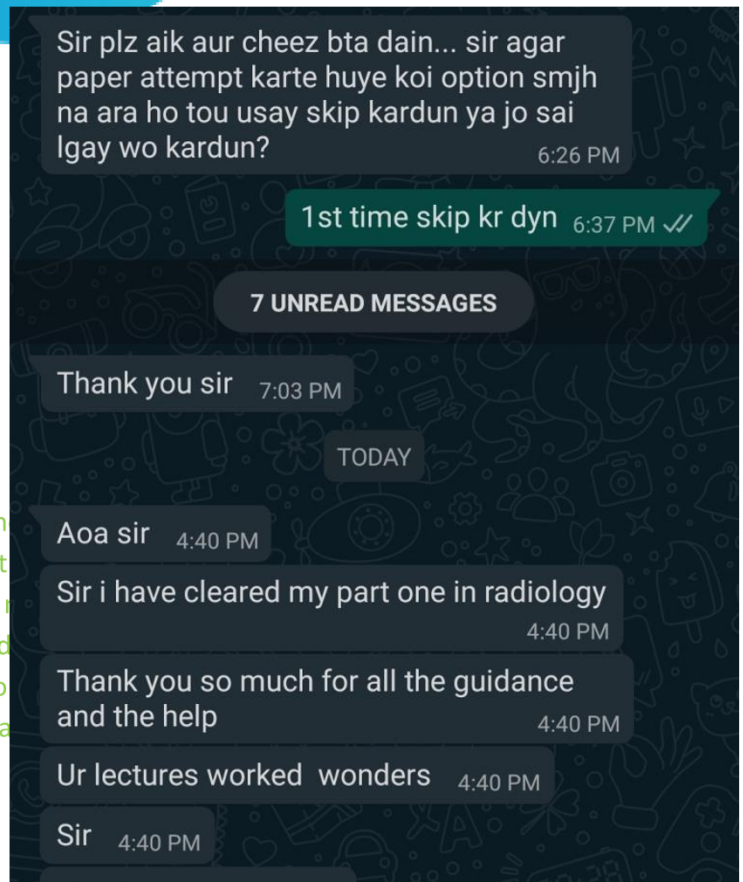
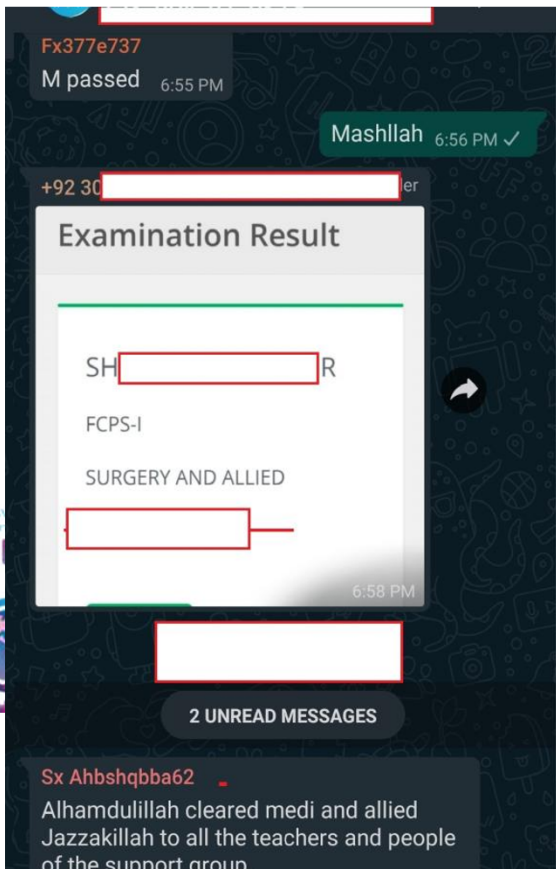
[www.t.me/fcps1byfcpsworld](http://www.t.me/fcps1byfcpsworld)

**FILE IS ONLY FOR CLASS STUDENTS (DO NOT SHARE)**



**& Many More Success Stories**

FCPS WORLD



Www.Fcpsworld.com (Institute for Fcps & Md/Ms)

[www.facebook.com/FcpsWorld](http://www.facebook.com/FcpsWorld)

[www.facebook.com/GynaeObsWorld](http://www.facebook.com/GynaeObsWorld)

[www.facebook.com/Ophtworld](http://www.facebook.com/Ophtworld)

[www.t.me/fcps1byfcpsworld](http://www.t.me/fcps1byfcpsworld)

**FILE IS ONLY FOR CLASS STUDENTS (DO NOT SHARE)**



**& Many More Success Stories**



- ✓ Now you can join us Online for MD/MS & Fcps Preparation
- ✓ Complete course in 2 months including Past paper discussion
- ✓ Join from anywhere using mobile/laptop using internet
- ✓ 100% feasible with job and 100% time adjustment for students
- ✓ [www.fcpsworld.com](http://www.fcpsworld.com) or Contact 03129684658
- ✓ Hostel Facility is also available (for those who want to join physical classes)

Www.Fcpsworld.com (Institute for Fcps & Md/Ms)

[www.facebook.com/FcpsWorld](http://www.facebook.com/FcpsWorld)

[www.facebook.com/GynaeObsWorld](http://www.facebook.com/GynaeObsWorld)

[www.facebook.com/Ophtworld](http://www.facebook.com/Ophtworld)

[www.t.me/fcps1byfcpsworld](http://www.t.me/fcps1byfcpsworld)



**FILE IS ONLY FOR CLASS STUDENTS (DO NOT SHARE)**

# FCPS-1 ONLINE COURSE

Join FcpsWorld Online preparation courses and clear exam in 1st Attempt.


[WWW.FCPSWORLD.COM](http://WWW.FCPSWORLD.COM)



Fcpsworld



[www.fcpsworld.com](http://www.fcpsworld.com)



- ✓ Now you can join us Online for MD/MS & Fcps Preparation
- ✓ Complete course in 2months including Past paper discussion
- ✓ Join from anywhere using mobile/laptop using internet
- ✓ 100% feasible with job and 100% time adjustment for students
- ✓ [www.fcpsworld.com](http://www.fcpsworld.com) or Contact 03129684658
- ✓ Hostel Facility is also available (for those who want to join physical classes)

Www.Fcpsworld.com (Institute for Fcps & Md/Ms)

[www.facebook.com/FcpsWorld](http://www.facebook.com/FcpsWorld)

[www.facebook.com/GynaeObsWorld](http://www.facebook.com/GynaeObsWorld)

[www.facebook.com/Ophtworld](http://www.facebook.com/Ophtworld)

[www.t.me/fcps1byfcpsworld](http://www.t.me/fcps1byfcpsworld)



**FILE IS ONLY FOR CLASS STUDENTS (DO NOT SHARE)**



## GoldStandard FCPS



- ✓ Now you can join us Online for MD/MS & Fcps Preparation
- ✓ Complete course in 2months including Past paper discussion
- ✓ Join from anywhere using mobile/laptop using internet
- ✓ 100% feasible with job and 100% time adjustment for students
- ✓ [www.fcpsworld.com](http://www.fcpsworld.com) or Contact 03129684658
- ✓ Hostel Facility is also available (for those who want to join physical classes)





Www.Fcpsworld.com (Institute for Fcps & Md/Ms)

[www.facebook.com/FcpsWorld](https://www.facebook.com/FcpsWorld)

[www.facebook.com/GynaeObsWorld](https://www.facebook.com/GynaeObsWorld)

[www.facebook.com/Ophtworld](https://www.facebook.com/Ophtworld)

[www.t.me/fcps1byfcpsworld](https://www.t.me/fcps1byfcpsworld)

**FILE IS ONLY FOR CLASS STUDENTS (DO NOT SHARE)**

- ✓ Feb 2021 papers (recent updated)
- ✓ Authentic most repeated papers.
- ✓ MCQs with explanation and reference.
- ✓ 1 liner for rapid revision. (Cram them)
- ✓ Clear FCPS-1 in 1st Attempt (Dont miss chance)
- ✓ Free Cash on Delivery **Order at 03129684658**



- ✓ Now you can join us Online for MD/MS & Fcps Preparation
- ✓ Complete course in 2months including Past paper discussion
- ✓ Join from anywhere using mobile/laptop using internet
- ✓ 100% feasible with job and 100% time adjustment for students
- ✓ [www.fcpsworld.com](http://www.fcpsworld.com) or Contact 03129684658
- ✓ Hostel Facility is also available (for those who want to join physical classes)