



Www.Fcpsworld.com (Institute for Fcps & Md/Ms)

www.facebook.com/FcpsWorld

www.facebook.com/GynaeObsWorld

www.facebook.com/Ophtworld

www.t.me/fcps1byfcpsworld

FILE IS ONLY FOR CLASS STUDENTS (DO NOT SHARE)



www.FCPSWORLD.com

GoldStandard FCPS (FCPS-1)

Medicine & Allied

17-June-2021 (Afternoon)

Recent Past Papers

www.FcpsWorld.com

- ✓ Clear FCPS-1 in **FIRST ATTEMPT**
- ✓ Entire course will be completed in 2 months.
- ✓ Live lectures via video Portal
- ✓ Daily Test session (Test discussion will be on Via Portal)
- ✓ Follow our complete guideline for FCPS-1
- ✓ Get Hands on 20,000 CPSP question (most of them repeat)
- ✓ Free study material, whatsapp group (only for our students)
- ✓ Don't Miss the chance. (**LIMITED SEATS AVAILABLE.**)
- ✓ **WWW.FCPSWORLD.com**
- ✓ **WWW.facebook.com/fcpsworld**
- ✓ For Details Phone# 03129684658



- ✓ Now you can join us Online for MD/MS & Fcps Preparation
- ✓ Complete course in 2months including Past paper discussion
- ✓ Join from anywhere using mobile/laptop using internet
- ✓ 100% feasible with job and 100% time adjustment for students
- ✓ www.fcpsworld.com or Contact 03129684658
- ✓ Hostel Facility is also available (for those who want to join physical classes)

FILE IS ONLY FOR CLASS STUDENTS (DO NOT SHARE)

(Errors and omissions excepted)

Cram Statements Inshllah 40 % to 60% paper will come from this file. DO not skip any file

Diapedesis refers to	Migration
Balloon dilation of atrium and increasing pressure to 5mmhg encourages release of	Atrial natriuretic peptide
PT should be measured in	Jaundice
difficult labour and bleeding from multiple sites.inc PT, APTT, BT, Hb=4.2 g/dl, platelets=9x10.dx	DIC
The Most common Opportunistic Organism affecting HIV patients is	Pneumocytis Jirovecii
Join FcpsWorld Online Classes and Clear exam in 1st Attempt (94% Passing ratio).	
Incising swelling shows yellow material , most cells in pus are	Neutrophils
Post Brain stem stroke due to vertebral artery . Dysphagia due to	Nucleus Amblygus
After 5 years of transplant surgery there is an increase incidence of	Lymphoproliferative disorders
Scenario pT 17 seconds a PT 52 seconds treatment should given	Vitamin K
Cyanide poisoning leads to inhibition of	Inhibition of cytochrome oxidation
Referral system ?	Better management
Join FcpsWorld Online Classes and Clear exam in 1st Attempt (94% Passing ratio).	
Important for prevention heart loss is	Vasoconstriction
cause of hepatocellular carcinoma in developing countries is	Both hep B & C
drops of blood at the External Urethral Meatus.not passed urine and his bladder is palpable.he has	Urethral injury
A structure two feet away from appendix is	Meckle's diverticulum
CSF shows yeast with clear cytoplasm & Halo around it. Organism ?	Cryptococcus
Join FcpsWorld Online Classes and Clear exam in 1st Attempt (94% Passing ratio).	
feature of reversible injury is	Cell swelling
phospholipid membrane is	Both polar and non-polar
Buy our book 'GoldStandard FCPS'(All papers arranged chapterwise, unitwise,topic wise,1-liner) and revise 11yrs past papers in 7 days Order at 03129684658.	
Atrial depolarization is represented by	P wave
Buy our book 'GoldStandard FCPS'(All papers arranged chapterwise, unitwise,topic wise,1-liner) and revise 11yrs past papers in 7 days Order at 03129684658.	
Cytoplasm of the cells demonstrate Basophilia and stains blue due to	RER



- ✓ Now you can join us Online for MD/MS & Fcps Preparation
- ✓ Complete course in 2months including Past paper discussion
- ✓ Join from anywhere using mobile/laptop using internet
- ✓ 100% feasible with job and 100% time adjustment for students
- ✓ www.fcpsworld.com or Contact 03129684658
- ✓ Hostel Facility is also available (for those who want to join physical classes)

FILE IS ONLY FOR CLASS STUDENTS (DO NOT SHARE)

Most severe reaction occurs in blood transfusion of	A+ to O+
Buy our book 'GoldStandard FCPS'(All papers arranged chapterwise, unitwise,topic wise,1-liner) and revise 11yrs past papers in 7 days Order at 03129684658.	
Drug contraindicated in CLD is	Pentazosin
Female with amenorrhea of 5weeks presented with right sided iliac pain wbc's raised and patient febrile ,diagnosis is	acute appendicitis
Join FcpsWorld Online Classes and Clear exam in 1st Attempt (94% Passing ratio).	
Buy our book 'GoldStandard FCPS'(All papers arranged chapterwise, unitwise,topic wise,1-liner) and revise 11yrs past papers in 7 days Order at 03129684658.	
In surgery under GAM^iedycardia occurs. Drug for bradycardia	Atropine
Hungtinton disease female and normal male married, number of offspring having disease is	50%
high grade fever and infected with pseudomonas . Blood will have high level of	TNF
Buy our book 'GoldStandard FCPS'(All papers arranged chapterwise, unitwise,topic wise,1-liner) and revise 11yrs past papers in 7 days Order at 03129684658.	
Join FcpsWorld Online Classes and Clear exam in 1st Attempt (94% Passing ratio).	
highest protein content is present in	Plasma
Restrictive lung disease like Pulmonary fibrosis has normal	FEV1/FVC
Gummatous necrosis is present in	Syphilis
Join FcpsWorld Online Classes and Clear exam in 1st Attempt (94% Passing ratio).	
Cardiac output is decreased in	heart failure
plasma acting in DKA is buffered by	HCO ₃
Join FcpsWorld Online Classes and Clear exam in 1st Attempt (94% Passing ratio).	
Cause of pansystolic murmur in axilla is	Mitral regurgitation
Chest injury has led to respiratory distress and loss of inspiration due too damage of	Diaphragm
Buy our book 'GoldStandard FCPS'(All papers arranged chapterwise, unitwise,topic wise,1-liner) and revise 11yrs past papers in 7 days Order at 03129684658.	
Join FcpsWorld Online Classes and Clear exam in 1st Attempt (94% Passing ratio).	
bitemporal hemianopia.on CT there is a cyctic area in the brain.area will be damaged	Pituitary gland
During exercise, position and balance is maintained by	proprioceptors
Maximum Water and electrolytes are absorbed from	Jejunum
Join FcpsWorld Online Classes and Clear exam in 1st Attempt (94% Passing ratio).	



- ✓ Now you can join us Online for MD/MS & Fcps Preparation
- ✓ Complete course in 2months including Past paper discussion
- ✓ Join from anywhere using mobile/laptop using internet
- ✓ 100% feasible with job and 100% time adjustment for students
- ✓ www.fcpsworld.com or Contact 03129684658
- ✓ Hostel Facility is also available (for those who want to join physical classes)

FILE IS ONLY FOR CLASS STUDENTS (DO NOT SHARE)

Mechanism of reduction in size of organ of a patient undergoing chemotherapy is	Direct action of chemo drug
The muscle unlocking knee joint is.	Popliteus
A 30 years old female is having swelling in front of the neck with difficulty in breathing while in the supine position type of swelling in this patient is	Retrosternal goiter
Join FcpsWorld Online Classes and Clear exam in 1st Attempt (94% Passing ratio).	
Join FcpsWorld Online Classes and Clear exam in 1st Attempt (94% Passing ratio).	
Pin worm mode of spread is	injection of eggs
Examination of patient showed Deltoid weakness, reduced biceps jerk and numbness of thumb involved nerve root is	C5-C6
Lady went from cold weather area and developed vesicular lesions in mouth due to	HSV 1
A boy falls down and fractures his Medial Epicondyle . Sensations are affected in	Loss of sensation at medial 1/3 of dorsum and palmar aspect of hand
Error in reading of pulse oximeter is	Methemoglobinemia
Buy our book 'GoldStandard FCPS'(All papers arranged chapterwise, unitwise,topic wise,1-liner) and revise 11yrs past papers in 7 days Order at 03129684658.	
Slow pain is transmitted by	Unmyelinated c fibers
Buy our book 'GoldStandard FCPS'(All papers arranged chapterwise, unitwise,topic wise,1-liner) and revise 11yrs past papers in 7 days Order at 03129684658.	
RBCs are protected from oxidative stress by	HMP shunt
max drainage from arachnoid granulations	Superior Sagittal Sinus
unability to dorsiflex and evert foot due to damage of	common peroneal nerve
neoplasms arising from viral oncogenesis is	T-cell leukemia
Mycobacterium Leprae is	an acid fast intracellular
Immediate & Transient potent action of Angiotensin 2 is	Vasoconstriction
Regarding suprarenal glands which of the following statements is true anatomically?	Greater splanchnic nerve supply
Buy our book 'GoldStandard FCPS'(All papers arranged chapterwise, unitwise,topic wise,1-liner) and revise 11yrs past papers in 7 days Order at 03129684658.	
SA node acts as a pacemaker because it	produces impulses at a faster rate
Human chorionic gonadotropin	Maintain pregnancy
Buy our book 'GoldStandard FCPS'(All papers arranged chapterwise, unitwise,topic wise,1-liner) and	



- ✓ Now you can join us Online for MD/MS & Fcps Preparation
- ✓ Complete course in 2months including Past paper discussion
- ✓ Join from anywhere using mobile/laptop using internet
- ✓ 100% feasible with job and 100% time adjustment for students
- ✓ www.fcpsworld.com or Contact 03129684658
- ✓ Hostel Facility is also available (for those who want to join physical classes)

FILE IS ONLY FOR CLASS STUDENTS (DO NOT SHARE)

revise 11yrs past papers in 7 days Order at 03129684658.	
Extraembryonic mesoderm is the derivative of	Hypoblast
Aspirin toxicity causes	Coma
factor does not take part in intrinsic pathway	Factor?
When he stands up from supine position heart rate is 120. This increase is due to	Decrease venous return
Buy our book 'GoldStandard FCPS'(All papers arranged chapterwise, unitwise,topic wise,1-liner) and revise 11yrs past papers in 7 days Order at 03129684658.	
to increase ECF and decrease ICF. Give	1 litre of 3% Nacl solution
Join FcpsWorld Online Classes and Clear exam in 1st Attempt (94% Passing ratio).	
Oxidase enzyme is present in	Peroxisome
Buy our book 'GoldStandard FCPS'(All papers arranged chapterwise, unitwise,topic wise,1-liner) and revise 11yrs past papers in 7 days Order at 03129684658.	
1 st rib fracture is associated with injury of	Subclavian artery
2 cm below and Lateral to pubic tubercle is	obturator nerve
feature of crohn's disease is	Increase Oxalate Absorption & Hyperoxaluria
The axon/structure present in nucleus of tractus solitarius is	cell bodies of 2nd order neuron in taste pathway
Nerve conducting pain sensation from epigestrium is	Great splanchnic nerve
In IgA nephropathy the histopathological report will be consistent with	
suprarenal glands anatomically are related to	greater splanchnic nerve supply
Buy our book 'GoldStandard FCPS'(All papers arranged chapterwise, unitwise,topic wise,1-liner) and revise 11yrs past papers in 7 days Order at 03129684658.	
Ten days after blood transfusion patient presented with jaundice and Diarrhoea due to	Graft versus Host Disease
Metabolism of protein needs vitamin	riboflavin
GFR increases due to	decreased oncotic pressure
O ₂ and H ₂ O ₂ are produced in neutrophil from	Peroxisome
gene amplification in children results in	Neuroblastome
Join FcpsWorld Online Classes and Clear exam in 1st Attempt (94% Passing ratio).	
associated with HLA B51 ?	BECHET disease



- ✓ Now you can join us Online for MD/MS & Fcps Preparation
- ✓ Complete course in 2months including Past paper discussion
- ✓ Join from anywhere using mobile/laptop using internet
- ✓ 100% feasible with job and 100% time adjustment for students
- ✓ www.fcpsworld.com or Contact 03129684658
- ✓ Hostel Facility is also available (for those who want to join physical classes)

FILE IS ONLY FOR CLASS STUDENTS (DO NOT SHARE)

Young adult presented with jaundice Anemia raised alkaline phosphatase.dx	Pigment stone
After pelvic fracture patient went into shock due to	Hemorrhage
Blood lithium level most likely is to be	1.5-2
Join FcpsWorld Online Classes and Clear exam in 1st Attempt (94% Passing ratio).	
CD4 cells are	helper cells
Buy our book 'GoldStandard FCPS'(All papers arranged chapterwise, unitwise,topic wise,1-liner) and revise 11yrs past papers in 7 days Order at 03129684658.	
Join FcpsWorld Online Classes and Clear exam in 1st Attempt (94% Passing ratio).	
Silicosis is present in	Sand basting
60 years old female with know case of IHD now present with Ventricular arrythmia. ECG shows enlarged irregular QRS complex. treatment of choice is	Lignocaine
A woman'Had MI ana after 48 hours later she died on ECG there are irregular low voltage waves due to	Re entry of impulses
Burns occurred to deep layer of dermis of hands. Will complicate due to	Contracture
Type of hypersensitivity in TB is	Type 4
Buy our book 'GoldStandard FCPS'(All papers arranged chapterwise, unitwise,topic wise,1-liner) and revise 11yrs past papers in 7 days Order at 03129684658.	
Person has diarrhea, fever tenderness in Right hypogastric region occult blood in stool.ulceration of ascending colon. Causative organism	Entameoba histolytica
Join FcpsWorld Online Classes and Clear exam in 1st Attempt (94% Passing ratio).	
Buy our book 'GoldStandard FCPS'(All papers arranged chapterwise, unitwise,topic wise,1-liner) and revise 11yrs past papers in 7 days Order at 03129684658.	
Ulnar nerve damage at medial epicondyle will cause	Hypo thenar wasting
history of gastric pain. gastroesophageal junction, cells of epithelium will undergo	Metaplasia
Join FcpsWorld Online Classes and Clear exam in 1st Attempt (94% Passing ratio).	
Neurogenic shock is due to	Dec, TPR
no significant past history of heart disease. On autopsy she had thick myocardium. Organism is	Coxsackie B virus
The Disorganised tissue on histopathological investigations is	Teratoma



- ✓ Now you can join us Online for MD/MS & Fcps Preparation
- ✓ Complete course in 2months including Past paper discussion
- ✓ Join from anywhere using mobile/laptop using internet
- ✓ 100% feasible with job and 100% time adjustment for students
- ✓ www.fcpsworld.com or Contact 03129684658
- ✓ Hostel Facility is also available (for those who want to join physical classes)

FILE IS ONLY FOR CLASS STUDENTS (DO NOT SHARE)

In thrombin formation	1st step is patient adhesion
Join FcpsWorld Online Classes and Clear exam in 1st Attempt (94% Passing ratio).	
A male has cholangio carcinoma due to	C.sinesis
Buy our book 'GoldStandard FCPS'(All papers arranged chapterwise, unitwise,topic wise,1-liner) and revise 11yrs past papers in 7 days Order at 03129684658.	
Characteristics site of the hemorrhagic infarction is	Intestine
Before final composition of concentrated Urine, least osmolar dilute solution is present in	DCT
Join FcpsWorld Online Classes and Clear exam in 1st Attempt (94% Passing ratio).	
Liquefactive necrosis involves	brain
Join FcpsWorld Online Classes and Clear exam in 1st Attempt (94% Passing ratio).	
left shift of oxygen Hb dissociation curve occurs in	CO poisoning
Thyroglossal duct cyst is invested in	Pretracheal fascia
Join FcpsWorld Online Classes and Clear exam in 1st Attempt (94% Passing ratio).	
Breakdown of erythrocytes is	High yield bilirubin bound plasma protien taken to liver
profound effect on the heart via	Potassium
Female with Anorexia and weight loss. lesion in hypothalamus, effected area is	Lateral hypethatfamsis
A baby boy having low IQ, flat faces epicanthus fold has	Trisomy 21
High output cardiac failure and cardiomyopathy occur in deficiency of	Thiamine
Growth hormone is increased in	Exercise
Pontocerebellar syndrome is associated with nerve involvement of	CN VIII
Female presented with Hb 9.6, TLC and platelets and normal. Iron has given. After 2 months Hb 10.2. further diagnosis include	Ferritin
anterior to the aorta is	Left renal vein
Umbilical dermatome is	T10
child after exchange transfusion 10 days body becomes red, Diarrhoea,jaundice and deranged LfTs. He is having	Graft vs host disease
Buy our book 'GoldStandard FCPS'(All papers arranged chapterwise, unitwise,topic wise,1-liner) and revise 11yrs past papers in 7 days Order at 03129684658.	



- ✓ Now you can join us Online for MD/MS & Fcps Preparation
- ✓ Complete course in 2months including Past paper discussion
- ✓ Join from anywhere using mobile/laptop using internet
- ✓ 100% feasible with job and 100% time adjustment for students
- ✓ www.fcpsworld.com or Contact 03129684658
- ✓ Hostel Facility is also available (for those who want to join physical classes)

FILE IS ONLY FOR CLASS STUDENTS (DO NOT SHARE)


characteristic feature of right ventricle is to	give rise to pulmonary trunk
Join FcpsWorld Online Classes and Clear exam in 1st Attempt (94% Passing ratio).	
Result of positive screening test came positive and negative screening test came negative	specificity
Menopause is associated with	Low estrogen and high FSH and LH
Dull percussion over the chest is characteristic of	pleural effusion
high relative diffusion capacity is of	Water
testing efficacy of norfloxacin and amoxlclillin in UTI. grouped as a & b randomly allocated to patients receiving either one of them Is a	siingle blind
HCO ₃ is absorbed in	PCT & CT
Hyponatremia with increased ECF volume is seen in	Excessive water intake
Join FcpsWorld Online Classes and Clear exam in 1st Attempt (94% Passing ratio).	
thyrotoxicosis is associated with	Gluconeogenesis
A baby with congenital rubella have loud S2, Continuous machine-like murmur, and	PDA
Minor calyx recieves urine from	Papilla
Buy our book 'GoldStandard FCPS'(All papers arranged chapterwise, unitwise,topic wise,1-liner) and revise 11yrs past papers in 7 days Order at 03129684658.	
Unloading of oxygen in tissues	Decreased with increased ph
common cause of heart failure is	Fibrinous pericarditis
A boy falls down and fractures his Medial Epicondyle.sensation loss occurs in	Loss of sensation at medial 1 /3 of dorsum and palmer of hand
Most common global Infectious cause of blindness is	Chlamydia trachomatis
receptors that sense Pressure and vibration	Paccinian
Typical Pulmoanry edema.raised JVP.,drug of choice is	FURESEMIDE
abundant cholesterol is present in	LDL
An Immediate meohanism to lose heat from body is	Cutaneous vasodilation
Zona Glomerulosa is linked with	sodium reabsorption
Buy our book 'GoldStandard FCPS'(All papers arranged chapterwise, unitwise,topic wise,1-liner) and revise 11yrs past papers in 7 days Order at 03129684658.	
Hepatitis associated with P ANCA vasculitis & Fibrinoid Necrosis is	Hep B
Join FcpsWorld Online Classes and Clear exam in 1st Attempt (94% Passing ratio).	
Cardiogenic shock is due	acute MI



- ✓ Now you can join us Online for MD/MS & Fcps Preparation
- ✓ Complete course in 2months including Past paper discussion
- ✓ Join from anywhere using mobile/laptop using internet
- ✓ 100% feasible with job and 100% time adjustment for students
- ✓ www.fcpsworld.com or Contact 03129684658
- ✓ Hostel Facility is also available (for those who want to join physical classes)

FILE IS ONLY FOR CLASS STUDENTS (DO NOT SHARE)

Pregnant women infected with german measles. Will have baby with	Congenital deafness
complains of dysphagia.Labs show hb-5 mo/dl MCV=30.dx	iron deficiency anaemia
gastric emptying & Motility is stimulated by	increased gastrin
Right side weakness for 2 days with diplopia while looking left. leison of	Midbrain
The axon/structure present in nucleus of tractus solitarius is	Cell bodies of 2nd order neuron in taste pathway
Join FcpsWorld Online Classes and Clear exam in 1st Attempt (94% Passing ratio).	
Patient Urine Osmolarity was decreased with Polydipsia and Polyuria. ADH analogue given to patient and it increased osmolarity due to	Central D.I
karyotype about the Partial mole is	69XXY
Join FcpsWorld Online Classes and Clear exam in 1st Attempt (94% Passing ratio).	
Aplasia is	Absence of cells
TPR is directly related to	Vasomotor tone
rheumatic valvular heart disease with pansystolic murmur, splenomegaly and clubbing, the treatment is	Inj Penicillin + Gentamicin
Join FcpsWorld Online Classes and Clear exam in 1st Attempt (94% Passing ratio).	



Join FcpsWorld Telegram group



- ✓ Now you can join us Online for MD/MS & Fcps Preparation
- ✓ Complete course in 2months including Past paper discussion
- ✓ Join from anywhere using mobile/laptop using internet
- ✓ 100% feasible with job and 100% time adjustment for students
- ✓ www.fcpsworld.com or Contact 03129684658
- ✓ Hostel Facility is also available (for those who want to join physical classes)

Www.Fcpsworld.com (Institute for Fcps & Md/Ms)

www.facebook.com/FcpsWorld

www.facebook.com/GynaeObsWorld

www.facebook.com/Ophtworld

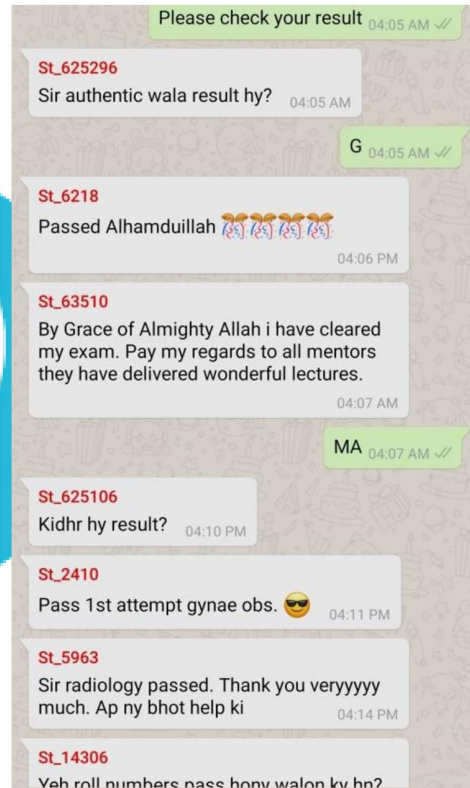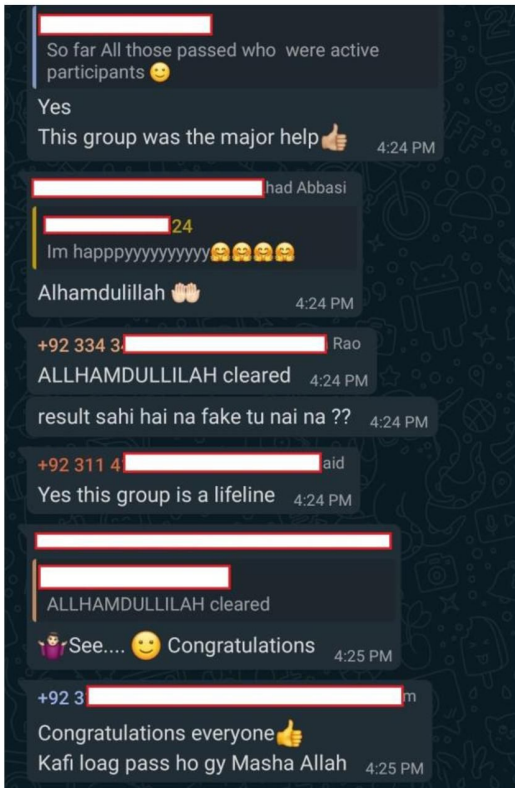www.t.me/fcps1byfcpsworld

FILE IS ONLY FOR CLASS STUDENTS (DO NOT SHARE)

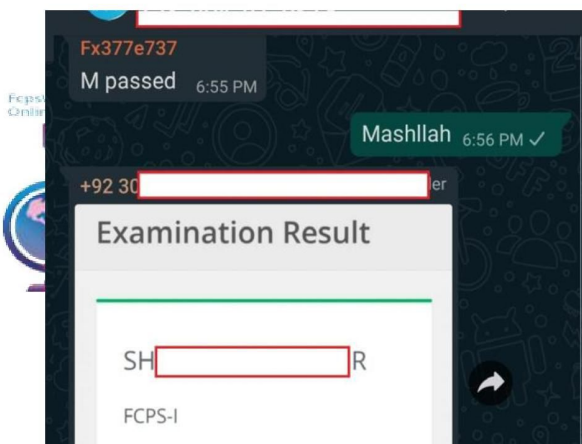
www.t.me/fcps1byfcpsworld

AND

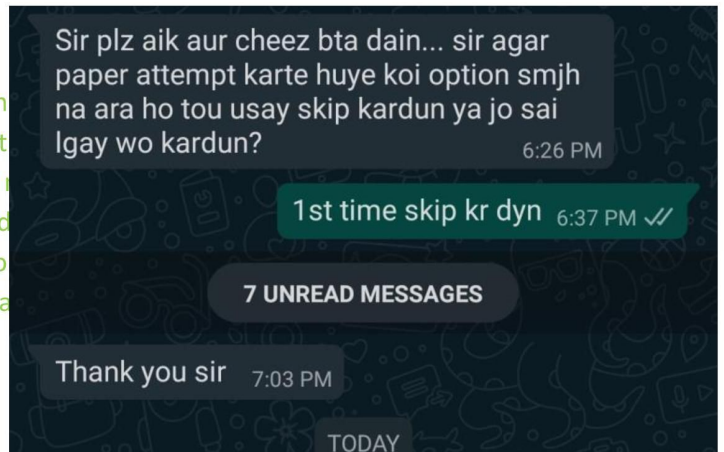
❖ Whatsapp 03129684658 to join whatsapp group of your speciality



& Many More Success Stories



us Online
in 2mont
ere using
h job and
om or Co
also availa





Www.Fcpsworld.com (Institute for Fcps & Md/Ms)

www.facebook.com/FcpsWorld

www.facebook.com/GynaeObsWorld

www.facebook.com/Ophtworld

www.t.me/fcps1byfcpsworld

FILE IS ONLY FOR CLASS STUDENTS (DO NOT SHARE)



& Many More Success Stories



- ✓ Now you can join us Online for MD/MS & Fcps Preparation
- ✓ Complete course in 2months including Past paper discussion
- ✓ Join from anywhere using mobile/laptop using internet
- ✓ 100% feasible with job and 100% time adjustment for students
- ✓ www.fcpsworld.com or Contact 03129684658
- ✓ Hostel Facility is also available (for those who want to join physical classes)

Www.Fcpsworld.com (Institute for Fcps & Md/Ms)

www.facebook.com/FcpsWorld

www.facebook.com/GynaeObsWorld

www.facebook.com/Ophtworld

www.t.me/fcps1byfcpsworld

FILE IS ONLY FOR CLASS STUDENTS (DO NOT SHARE)



FCPS-1 ONLINE COURSE

Join FcpsWorld Online preparation courses and clear exam in 1st Attempt.


WWW.FCPSWORLD.COM



Fcpsworld



www.fcpsworld.com





Www.Fcpsworld.com (Institute for Fcps & Md/Ms)

www.facebook.com/FcpsWorld

www.facebook.com/GynaeObsWorld

www.facebook.com/Ophtworld

www.t.me/fcps1byfcpsworld

FILE IS ONLY FOR CLASS STUDENTS (DO NOT SHARE)



GoldStandard FCPS



- ✓ Now you can join us Online for MD/MS & Fcps Preparation
- ✓ Complete course in 2months including Past paper discussion
- ✓ Join from anywhere using mobile/laptop using internet
- ✓ 100% feasible with job and 100% time adjustment for students
- ✓ www.fcpsworld.com or Contact 03129684658
- ✓ Hostel Facility is also available (for those who want to join physical classes)



Www.Fcpsworld.com (Institute for Fcps & Md/Ms)

www.facebook.com/FcpsWorld

www.facebook.com/GynaeObsWorld

www.facebook.com/Ophtworld

www.t.me/fcps1byfcpsworld

FILE IS ONLY FOR CLASS STUDENTS (DO NOT SHARE)

- ✓ Feb 2021 papers (recent updated)
- ✓ Authentic most repeated papers.
- ✓ MCQs with explanation and reference.
- ✓ 1 liner for rapid revision. (Cram them)
- ✓ Clear FCPS-1 in 1st Attempt (Dont miss chance)
- ✓ Free Cash on Delivery **Order at 03129684658**



- ✓ Now you can join us Online for MD/MS & Fcps Preparation
- ✓ Complete course in 2months including Past paper discussion
- ✓ Join from anywhere using mobile/laptop using internet
- ✓ 100% feasible with job and 100% time adjustment for students
- ✓ www.fcpsworld.com or Contact 03129684658
- ✓ Hostel Facility is also available (for those who want to join physical classes)