



Www.Fcpsworld.com (Institute for Fcps & Md/Ms)

www.facebook.com/FcpsWorld

www.facebook.com/GynaeObsWorld

www.facebook.com/Ophtworld


FILE IS ONLY FOR CLASS STUDENTS (DO NOT SHARE)



www.FCPSWORLD.com

GoldStandard FCPS

by FCPSWORLD



(50 to 60% paper is from this file

Inshllah)

- ✓ Clear FCPS-1 in **FIRST ATTEMPT**
- ✓ Entire course will be completed in 2 months.
- ✓ Live lectures via video Portal
- ✓ Daily Test session (Test discussion will be on Via Portal)
- ✓ Follow our complete guideline for FCPS-1
- ✓ Get Hands on 20,000 CPSP question (most of them repeat)
- ✓ Free study material, [whatsapp](#) group (only for our students)
- ✓ Don't Miss the chance. (LIMITED SEATS AVAILABLE.)
- ✓ WWW.FCPSWORLD.com
- ✓ WWW.facebook.com/fcpsworld
- ✓ For Details Phone# 03129684658



- ✓ Now you can join us Online for MD/MS & Fcps Preparation
- ✓ Complete course in 2months including Past paper discussion
- ✓ Join from anywhere using mobile/laptop using internet
- ✓ 100% feasible with job and 100% time adjustment for students
- ✓ www.fcpsworld.com or Contact 03129684658
- ✓ Hostel Facility is also available (for those who want to join physical classes)



Www.Fcpsworld.com (Institute for Fcps & Md/Ms)

www.facebook.com/FcpsWorld

www.facebook.com/GynaeObsWorld

www.facebook.com/Ophtworld

FILE IS ONLY FOR CLASS STUDENTS (DO NOT SHARE)

(Errors and omissions excepted)

Cram Statements Inshallah 70 % paper will come from this file. DO not skip this file...

- ❖ Upper 1/3 of esophagus supplied by----->Inferior thyroid artery
- ❖ Baby having pallor mev 56. Diagnosis----->Thalassemia trait
- ❖ Rotation of scapula is by----->Serratus ant
- ❖ Sudden rise in pulse pressure is due to----->Decrease in arterial compliance
- ❖ DOC for Taeniasolium----->Praziquantel
- ❖ the largest cell in blood----->monocyte
- ❖ Epicardium blood supply is by----->Pericardiophrenic artery
- ❖ DOC of bacterial meningitis----->Ceftriaxone
- ❖ Abduction of arm lost,nerves injured----->Axillary nerve + suprascapular nerve
- ❖ raised direct bilirubin, ALP was 10 timesdiagnosis is----->Extrahepatic cholestasis
- ❖ left sided chest pain, 4th-6th intercostal tenderness. Cardic markers normal----->Costochondritis

- ❖ green coloured organism is----->Pseudomonas
- ❖ Third heart sound is produced due to----->Rapid ventricular filling
- ❖ Fat necrosis can be seen in----->Trauma
- ❖ lymphadenopathy, CD 15, CD 30 positive, double nucleated cells are in----->hodginks lymphoma
- ❖ Scalp blood vessels are present in layer----->between skin and aponeurosis
- ❖ Antibodies are formed by----->Plasma cells
- ❖ most common lobe of prostate involed in CA----->Posterior
- ❖ Mother brought her neonate with signs of meningitis. organism is----->group B streptococci (agalactiae)
- ❖ structure is in immediate relation with Internal jugular vein after leaving from jugular foramen----->Internal carotid artery
- ❖ Inferior thyroid artery ligated,nerve damage----->Recurrent laryngeal nerve
- ❖ in shock best way to tell resuscitation----->Increase urine output
- ❖ Blood in CSF. problem----->Subarachnoid hemorrhage
- ❖ Neck of bladder in female----->Above surface of urogenital diaphragm
- ❖ micturitionreflex----->Sacral segments of spinal cord
- ❖ Muscle of stabilizing knee joint----->Vastus laterals
- ❖ Cimetidine is not taken with sucralfate. Reason----->decrease absorption



- ✓ Now you can join us Online for MD/MS & Fcps Preparation
- ✓ Complete course in 2months including Past paper discussion
- ✓ Join from anywhere using mobile/laptop using internet
- ✓ 100% feasible with job and 100% time adjustment for students
- ✓ www.fcpsworld.com or Contact 03129684658
- ✓ Hostel Facility is also available (for those who want to join physical classes)



Www.Fcpsworld.com (Institute for Fcps & Md/Ms)

www.facebook.com/FcpsWorld

www.facebook.com/GynaeObsWorld

www.facebook.com/Ophtworld

FILE IS ONLY FOR CLASS STUDENTS (DO NOT SHARE)

- ❖ Most common cause of mental retardation is----->Fragile X syndrome
- ❖ drug that has no receptor----->Aluminum hydroxide
- ❖ Vitamin is required for coenzyme A----->Pantothenic acid
- ❖ fell from bicycle.loss of lateral sensation of arm----->Axillary nerve
- ❖ Donut shaped organisms in stool ----->Cryptosporidium
- ❖ Complication of 3rd degree burn is----->Contracture
- ❖ Avulsion of lesser trochanter,contraction of which muscle will be seen----->Psoas
- ❖ Major stress hormone----->cortisol
- ❖ smoker with history of weight loss,diagnosis is ----->Bronchogenic carcinoma
- ❖ A person lost 3 L of water and drink 3 L of water, what will increase----->ICF volume
- ❖ RH negative transfused RH+. Treated by----->Anti D antibodies
- ❖ Colon carcinoma marker----->CEA
- ❖ Tumour suppressor gene----->P53
- ❖ Finger cut will release----->Histamine
- ❖ Combining two substance is by----->Synthesize
- ❖ joint pains, papilledema, dry mucosa is in toxicity of----->Vitamin A
- ❖ pain mediator----->Bradykinin
- ❖ bronchiectasis, infertility and situs in versus. Diagnosis----->Kartageners syndrome
- ❖ The nerve or part of brachial plexus gives a terminal branch and it supplies medial aspect of arm----->medial cord
- ❖ longest duration of anesthesia and decreases pain as well----->Bupivacaine

- ❖ Rigor mortis is due to----->Decrease ATP

- ❖ In second degree heart block----->Atria contact more than the ventricles
- ❖ homeostasis of internal environment of body is maintained by----->Negative feedback
- ❖ characteristic feature of follicular carcinoma of thyroid gland----->Invade Cendometrial proliferation capsule
- ❖ anterior cerebral artery (ACA) supply----->Somatosensory area
- ❖ Cytokeratin is an example of----->Intermediate filament
- ❖ Middle cerebral artery supplies----->Insula and opercula
- ❖ type of hypersensitivity reaction of post streptococcal glomerulonephritis----->Type III



- ✓ Now you can join us Online for MD/MS & Fcps Preparation
- ✓ Complete course in 2months including Past paper discussion
- ✓ Join from anywhere using mobile/laptop using internet
- ✓ 100% feasible with job and 100% time adjustment for students
- ✓ www.fcpsworld.com or Contact 03129684658
- ✓ Hostel Facility is also available (for those who want to join physical classes)



Www.Fcpsworld.com (Institute for Fcps & Md/Ms)

www.facebook.com/FcpsWorld

www.facebook.com/GynaeObsWorld

www.facebook.com/Ophtworld

FILE IS ONLY FOR CLASS STUDENTS (DO NOT SHARE)

- ❖ **PDA (patent ductus arteriosus) mostly present in-----**→In pre term births (After birth, the ductus arteriosus normally closes within two or three days. In premature infants, the connection often takes longer to close. If the connection remains open, its referred to as a patent ductus arteriosus. The abnormal opening causes too much blood to circulate to the babys lungs and heart.)
- ❖ **Halothane should be given with-----**→Nitrous oxide
- ❖ **chorea athetosis is feature of-----**→Huntingtons disease
- ❖ **Median umbilical ligament is remnant of-----**→Urachus
- ❖ **floor of inguinal canal is formed by-----**→inguinal ligament & lacunar ligament
- ❖ **Lowest testosterone in age-----**→Pre-school age
- ❖ **hx of pan chewing, oral lesion is premalignant-----**→submucosal fibrosis
- ❖ **Canalicular stage of lung development-----**→Alveolar ducts formation
- ❖ **Regarding relation of hip joint-----**→Inferior to obturator extemus
- ❖ **Pneumonia in cystic fibrosis. Organism-----**→Pseudomonas
- ❖ **Thyroid cancer in lady cervical lymphadenopathy-----**→Papillary
- ❖ **Anterior dislocation of shoulder causes damage to-----**→Axillary nerve
- ❖ **Estimatetion of renal plasma flow is by-----**→PAH
- ❖ **Diffusion depends upon -----**→Surface area of a membrane
- ❖ **in CRF there is hypertrophy of-----**→Parathyroid
- ❖ **cancer of infra temporal fossa eroding floor of middle cranial fossa. Structure will be damaged-----**→Greater wing of sphenoid
- ❖ **Lymphocytes enter . in thymus through-----**→Afferent subscapular sinus
- ❖ **Cushings show-----**→Hyperglycemia
- ❖ **hx stroke now has depression and confusion. lobe of brain involved-----**→Frontal
- ❖ **Thumb opposition is by-----**→Median nerve
- ❖ **Anterior duodenal perforation contents leak into-----**→Right paracolic gutter
- ❖ **Psoas muscle insertion-----**→Lesser trochanter
- ❖ **Oral premalignant condition-----**→Lichen planus
- ❖ **Amoeba ulcer most common site-----**→Caecum
- ❖ **Norepinephrine is released from-----**→Preganglionic sympathetic fibres
- ❖ **Sperms become partially motile in.-----**→Epididymis
- ❖ **Voluntary muscle contraction has alpha motor and gamma motor-----**→descending pathway
- ❖ **In hepatic cirrhosis there will be low-----**→Albumin



- ✓ Now you can join us Online for MD/MS & Fcps Preparation
- ✓ Complete course in 2months including Past paper discussion
- ✓ Join from anywhere using mobile/laptop using internet
- ✓ 100% feasible with job and 100% time adjustment for students
- ✓ www.fcpsworld.com or Contact 03129684658
- ✓ Hostel Facility is also available (for those who want to join physical classes)



Www.Fcpsworld.com (Institute for Fcps & Md/Ms)

www.facebook.com/FcpsWorld

www.facebook.com/GynaeObsWorld

www.facebook.com/Ophtworld

FILE IS ONLY FOR CLASS STUDENTS (DO NOT SHARE)

- ❖ Adrenocortical insufficiency with increase urine sodium is due to-----Unable to reabsorb from tubules
- ❖ nerve damage in appendicitis operation----->Iliohypogastric nerve
- ❖ post Gastrectomy have megaloblastic anemia, treated by----->IV Vit. B12
- ❖ hx of meningitis of CSF show lymphocytes with normal glucose.----->Viral
- ❖ In stroke, most likely thrombosis of branch fo internal carotid artery----->MCA
- ❖ typhoid vaccination give----->Active immunity
- ❖ Approach for thoracocentesis----->Lower 9th ICS mid clavicular line
- ❖ Abductor of femur----->gluteus maximus
- ❖ Right kidney hilum anterior relation with----->2nd part of duodenum (liver was not in option)
- ❖ Medial pterygoid and lateral pterygoid cause ----->protrusion of mandible
- ❖ 5 pack years of smoking history----->Squamous metaplasia (best among options)
- ❖ Amount of iron in adult female----->2g
- ❖ Subacute endocarditis is caused by----->streptococcus viridians
- ❖ hx of hepatosplenomegaly and xanthoma. Test should be----->Anti-mitochondrial antibodies
- ❖ Free margin of lesser omentum has----->CBD, hepatic artery, portal vein
- ❖ pia matter----->Extends to sulci and fissures
- ❖ Most imp in metastasis of Carcinoma----->loss of E-cadherin
- ❖ Dorsal scapular nerve innervates----->Levator scapulae
- ❖ gas has maximum diffusion capacity----->CO2
- ❖ Anterior to piriformis muscle----->Superior gluteal artery
- ❖ Increase drug absorption by----->Increase lipid solubility
- ❖ Avoid 1st pass effect is by route----->IV
- ❖ Drug of choice for bacterial meningitis----->Ceftriaxone
- ❖ Ontogenesis imperfecta has defect in----->Defect in collagen synthesis
- ❖ Left shift of curve----->Hypothermia
- ❖ Tumor with nerve sheath invasion----->Ex pleomorphic adenoma
- ❖ DVT thrombus lodges in----->Pulmonary artery

- ❖ Corticosteroids side effect----->Purple striae
- ❖ part of pituitary gland receives signals from Hypothalamus----->Adenohypophysis
- ❖ BT raised, APTT raised and PT normal----->vWF disease



- ✓ Now you can join us Online for MD/MS & Fcps Preparation
- ✓ Complete course in 2months including Past paper discussion
- ✓ Join from anywhere using mobile/laptop using internet
- ✓ 100% feasible with job and 100% time adjustment for students
- ✓ www.fcpsworld.com or Contact 03129684658
- ✓ Hostel Facility is also available (for those who want to join physical classes)



Www.Fcpsworld.com (Institute for Fcps & Md/Ms)

www.facebook.com/FcpsWorld

www.facebook.com/GynaeObsWorld

www.facebook.com/Ophtworld

FILE IS ONLY FOR CLASS STUDENTS (DO NOT SHARE)

- ❖ Autoregulation of coronary circulation is determined by----->Myocardial oxygen demand
- ❖ Prominent Pre-potential----->SA node
- ❖ abdominal pain and vomiting for 2 hours, cause is----->Enterotoxin
- ❖ Warfarin causing bleeding, treated by----->Vitamin K
- ❖ sudden loss of vision. Cause----->Emboli
- ❖ Lesion of Wernickes area ----->Speaks fluently makes no sense
- ❖ Output nuclei of basal ganglia are----->Globus pallidus internes + substanta nigra pars reticularis
- ❖ Turners syndrome genetics----->45X0
- ❖ In thyroid nodule, oval shaped cells filled with amyloid tissue, small cytoplasm. Cause----->Medullary cancer
- ❖ Mediator of pain is----->Prostaglandins & bradykinin
- ❖ Subdural hematoma is caused by----->bridging veins
- ❖ Thyroglobulin is secreted by----->Follicular cells
- ❖ Light falls in front of retina in----->Myopia
- ❖ ECG in acute MI----->St segment displacement
- ❖ loss 1.5L blood blood picture will be----->Normocytic normochromic
- ❖ Malignant tertian malaria is due to----->Plasmodium falciparum
- ❖ 1 gm of hemoglobin binds with O₂----->1.34 ml O₂ per gram
- ❖ Filtration of substance - excretion substance is----->Renal secretion {{{Urinary excretion rate = Filtration rate – Reabsorption rate + Secretion rate}}}
- ❖ All receptors are----->Protein in nature
- ❖ Bullet injury to cervical region. Nerve of muscle is damaged----->Diaphragm
- ❖ Most abundant immunoglobulin in serum----->IgG
- ❖ Marathon runner started sweating profusely, dizziness,confusion and fell----->heat exhaustion
- ❖ drug is responsible forfractures in asthma----->Prednisolone

- ❖ cause ofpneumonia in children----->Streptococcus pneumonia
- ❖ Structure present at crista terminals----->SA node
- ❖ the relation of pituitary gland----->Tumor causes junctional scotoma
- ❖ Inhaled anesthesia that increases blood flow to the brain----->halothane
- ❖ Pancreatic duodenal artery is a branchof----->Gastro duodenal artery
- ❖ Hyperemesis gravidarum result in----->Hypokalemia



- ✓ Now you can join us Online for MD/MS & Fcps Preparation
- ✓ Complete course in 2months including Past paper discussion
- ✓ Join from anywhere using mobile/laptop using internet
- ✓ 100% feasible with job and 100% time adjustment for students
- ✓ www.fcpsworld.com or Contact 03129684658
- ✓ Hostel Facility is also available (for those who want to join physical classes)



Www.Fcpsworld.com (Institute for Fcps & Md/Ms)

www.facebook.com/FcpsWorld

www.facebook.com/GynaeObsWorld

www.facebook.com/Ophtworld

FILE IS ONLY FOR CLASS STUDENTS (DO NOT SHARE)

- ❖ Muscles causes Dorsiflexion and inversion----->Tibialis anterior
- ❖ Medial longitudinal arch in sole formed by----->Talus
- ❖ Free HB is bound by a protein ----->Haptoglobin
- ❖ type of shock involves degranulation of basophils and mast cells----->Anaphylactic shock
- ❖ type of necrosis in liver----->Caseous necrosis.
- ❖ ecg show U waves, inverted T waves----->Hypokalemia
- ❖ boy holding 4 books suddenly drops books----->Inverse stretch reflex
- ❖ farmer after taking care of sheeps has black lesion on his arm with fever. diagnosis---->Anthrax

- ❖ Autosomal dominant traits are----->Mostly heterozygous trait
- ❖ on fracture POP applied. Result will----->Decreased in actin and myosin
- ❖ After 5 years of transplant cancer most likely----->Lymphoproliferative disorder
- ❖ A case of repeated abortion due to hormonal disturbance----->Progesterone
- ❖ Duodenal Ulcer, causing hemoptysis. Cause is----->Anterior perforation, gastro duodenal artery
- ❖ movement at atlantoaxial joint----->rotation
- ❖ on autopsy pt has thick myocardium Organism is----->Coxsackie virus
- ❖ Spore forming----->Clostridium
- ❖ Lower limb paralysis, lower face paralysis and homonymous hemianopia area damaged----->Frontal lobe
- ❖ Protein requirement in adult-----> 1g/kg
- ❖ Septic meningitis caused due to----->Streptococcus pneumonia
- ❖ Gram negative rod, c shaped, hemodynamically stable person(contained values of hb, hematocrit) ----->Campylobacter J ujeni
- ❖ in Caput medusae, left portal vein channeled to umbilical veins via----->Para-umbilical vein
- ❖ Supination of upper limb effected----->Musculocutaneus + Radial nerve
- ❖ Medial wall of ischiorectal fossa is formed by-----> Levator ani
- ❖ Aspirin inhibits----->Thromboxane A2 production
- ❖ Upper left breast drains into----->Anterior axillary lymph nodes



- ✓ Now you can join us Online for MD/MS & Fcps Preparation
- ✓ Complete course in 2months including Past paper discussion
- ✓ Join from anywhere using mobile/laptop using internet
- ✓ 100% feasible with job and 100% time adjustment for students
- ✓ www.fcpsworld.com or Contact 03129684658
- ✓ Hostel Facility is also available (for those who want to join physical classes)



Www.Fcpsworld.com (Institute for Fcps & Md/MS)

www.facebook.com/FcpsWorld

www.facebook.com/GynaeObsWorld

www.facebook.com/Ophtworld

FILE IS ONLY FOR CLASS STUDENTS (DO NOT SHARE)

- ❖ Glans penis has lymphatic drainage----->Deep inguinal lymph nodes
- ❖ Air-borne disease----->Anthrax
- ❖ Bronchial segment is supplied by----->Tertiary bronchus
- ❖ What is collagen fibres----->Stain with cosin
- ❖ tyre factory, presented with painless hematuria and transitional cell bladder carcinoma. cause----->Smoking
- ❖ X linked recessive disease example----->G6Pd deficiency
- ❖ S3 heart sound is produced due----->Rapid ventricular filling

- ❖ Basal ganglia damage----->voluntary movements
- ❖ Systemic embolism arises from----->Left ventricle mural thrombus
- ❖ the important function of progesterone----->Endometrial proliferation
- ❖ pt with headache and diplopia. CSF is blood stained. diagnosis----->Subarachnoid hemorrhage

- ❖ Conductive system of heart lies in----->Sub endocardium
- ❖ Vitamins are present in----->Vegetables
- ❖ Drug of choice for acute pancrea is-----> Pethidine
- ❖ Nutrition of bone matrix is-----> Osteocyte
- ❖ Lymphatic drainage from lateral part of breast----->anterior axillary LN
- ❖ Ovarian carcinoma lymph drainage in nodes----->Para-aortic
- ❖ ureter injured during hysterectomy----->Passes behind broad ligament
- ❖ drug that block adeny cyclase and low cAMP is used for----->Vibrio cholera
- ❖ TBW of 42 liter. Interstitial fluid is about----->11.2L
- ❖ After 4 hours of MI most sensitive test----->Troponin 1
- ❖ nerve of extensor carpi ulnar is----->Posterior interosseous nerve
- ❖ Peripheral neuritis cause----->Thiamine defi
- ❖ Chemotherapy cause----->Apoptosis
- ❖ Pericardiocentesis location for straw colored fluid----->Left parasternal 3rd intercostal space
- ❖ Internal oblique muscle aponeurosis----->Conjoint tendon
- ❖ Child birth is a process of----->Positive feedback mechanism
- ❖ activation of caspases is seen in----->Apoptosis
- ❖ During exercise person feels tired due to ----->Increased heart rate
- ❖ UMN lesion results in----->Hyperreflexia



- ✓ Now you can join us Online for MD/MS & Fcps Preparation
- ✓ Complete course in 2months including Past paper discussion
- ✓ Join from anywhere using mobile/laptop using internet
- ✓ 100% feasible with job and 100% time adjustment for students
- ✓ www.fcpsworld.com or Contact 03129684658
- ✓ Hostel Facility is also available (for those who want to join physical classes)



Www.Fcpsworld.com (Institute for Fcps & Md/Ms)

www.facebook.com/FcpsWorld

www.facebook.com/GynaeObsWorld

www.facebook.com/Ophtworld

FILE IS ONLY FOR CLASS STUDENTS (DO NOT SHARE)

- ❖ After thyroidectomy developed hoarseness. vocal cords are rigid and tense. Area damaged----->Cricothyroid
- ❖ Metastasis of tumor depends upon-----> Basement membrane invasion
- ❖ salivary gland is mainly mucinous----->Sublingual
- ❖ Best site of pleurocentesis----->lower part of 9th intercostal space in midaxillary line
- ❖ Parotid gland nerve supply----->General visceral efferent
- ❖ Bundle of Hiss supplied by----->RCA
- ❖ damaged to nucleus gracilis and cuneatus cause----->Astereognosis
- ❖ lambert Eaton syndrome----->antibody against Ca+ channels
- ❖ O2 transport from alveoli to RBC is an example of----->Passive diffusion
- ❖ Urinary bladder----->supplied by sympathetic and parasympathetic
- ❖ During respiration, increase in diameter of chest----->External intercostal muscle
- ❖ Hx of chest infection. presented with epistaxis, purpura, investigation will you order first----->BT
- ❖ malignant hyperthermia Receptors are-----> Ryanodine receptor

- ❖ best way to clean OT or floor of infected by AIDs----->1% hypochlorite
- ❖ PDGF are present in platelets in----->Alpha granules
- ❖ nonhealing wound on foot despite of dressing. Most likely cause of impaired healing----->Mobility
- ❖ In neonate spinal cord end at----->L3
- ❖ A middle aged woman with scleral icterus with no other finding, likely cause is-----> Intravascular hemolysis
- ❖ Transitional epithelium derived from----->Endoderm
- ❖ Lobules and alveoli developed by----->GnRH
- ❖ Starvation causes----->Increase ketone bodies in serum
- ❖ Increase in hypothalamus set point will cause----->Decreased sweating
- ❖ In erect position hyoid bone lies at----->C3
- ❖ hx of gum bleeds, pt raised, apt raised, bt raised, Aptt raised ----->DIC
- ❖ lymphatic drainage of the lower lip----->Submental and submandibular
- ❖ Increased pre-potential----->SA node
- ❖ CO2 transport as----->HCO3+
- ❖ muscle is responsible for unlocking the knee joint----->Popliteus
- ❖ Eversion of foot is by----->Peroneus longus
- ❖ loss of sensation at root of thumb, damage to nerve----->Radial nerve



- ✓ Now you can join us Online for MD/MS & Fcps Preparation
- ✓ Complete course in 2months including Past paper discussion
- ✓ Join from anywhere using mobile/laptop using internet
- ✓ 100% feasible with job and 100% time adjustment for students
- ✓ www.fcpsworld.com or Contact 03129684658
- ✓ Hostel Facility is also available (for those who want to join physical classes)



Www.Fcpsworld.com (Institute for Fcps & Md/Ms)

www.facebook.com/FcpsWorld

www.facebook.com/GynaeObsWorld

www.facebook.com/Ophtworld

FILE IS ONLY FOR CLASS STUDENTS (DO NOT SHARE)

- ❖ HLA-B27 positive in----->Reactive arthritis
- ❖ Hepatocellular carcinoma is due to----->Clonorchis sinensis
- ❖ vessel runs in interventricular groove----->Middle cardiac vein
- ❖ Maximum O2 saturation in----->Umbilical Veins
- ❖ Splenic vein drainage----->Posterior upper body and neck of pancreas
- ❖ epistaxis and history of vaccination. Diagnosis----->ITP
- ❖ in shock with MAP <50, most rapid response is by----->CNS ischemic response
- ❖ Autoimmune hemolytic anemia common cause----->Drugs
- ❖ pap smear show large nuclei with poikilocytosis. Cause is-----> Dysplasia
- ❖ pregnant lady developed short of breath and died on her way to hospital ER. Cause-----> Amniotic fluid embolism
- ❖ Hx of amenorrhea, proleptenimia. structure damaged is----->Pituitary gland
- ❖ recurrent bleeding a epistaxis----->platelets deficiency

- ❖ Derivative of first pharyngeal arch----->Mylohyoid
- ❖ Strongest inhibitory signals in CNS come from neurons----->Purkinje cells of cerebellum
- ❖ fibrocartilage----->contains an amorphous substance
- ❖ Active thyroid hormone is----->T3
- ❖ Pt. 13 seconds, bt 8 minutes, apt 61 seconds, defect lies in----->Intrinsic pathway
- ❖ FFP (fresh frozen plasma) is treatment of choice for----->Warfarin toxicity
- ❖ diagnose Beta hemolyticus can be by----->Blood culture
- ❖ after operation there is abdominal distension and low bp cause----->Hemorrhagic shock
- ❖ structure has pseudostratified epithelium with simple tubular glands that invade stroma----->Prostate
- ❖ bone matrix produced by ----->Osteoid
- ❖ Forceps delivery newborn has weak abduction. area damaged----->Upper trunk of brachial plexus
- ❖ Type of hypersensitivity reaction of myasthenia gravis is----->Type 2
- ❖ Outermost layer of retina----->Retinal pigment epithelium
- ❖ Prosopagnosia is inability to----->Recognize faces
- ❖ hx of bone pain. Serum show monoclonal bands. Diagnosis----->Multiple myeloma

- ❖ pt with +ve antimitochondrial antibodies. Diagnosis is----->Primary biliary cirrhosis



- ✓ Now you can join us Online for MD/MS & Fcps Preparation
- ✓ Complete course in 2months including Past paper discussion
- ✓ Join from anywhere using mobile/laptop using internet
- ✓ 100% feasible with job and 100% time adjustment for students
- ✓ www.fcpsworld.com or Contact 03129684658
- ✓ Hostel Facility is also available (for those who want to join physical classes)



Www.Fcpsworld.com (Institute for Fcps & Md/Ms)

www.facebook.com/FcpsWorld

www.facebook.com/GynaeObsWorld

www.facebook.com/Ophtworld

FILE IS ONLY FOR CLASS STUDENTS (DO NOT SHARE)

- ❖ burn pt is prone to non bacterial infection----->Candida
- ❖ Benign tumour----->Warthin tumour
- ❖ Levator anni nerve supply----->Pudendal nerve
- ❖ Heparin exerts its action by----->By potentiating action of anti-throma
- ❖ Carbon dioxide is mostly presented in body in form-----> Bicarbonate
- ❖ Sub capsular sinus lymphatics are----->Lymph node
- ❖ Renal column contains----->Interlobular artery
- ❖ pyelonephritis commonly caused by----->E-coli
- ❖ Shortest pre erythrocytic phase----->P. Falciparum
- ❖ Decrease lymphatic flow due to rise in----->capillary oncotic pressure
- ❖ Apex of heart is located----->5th ICS clavicular line

- ❖ Ca ovary marker----->Ca-125

- ❖ Clavulanic + amoxicillin due to-----> beta lactamases
- ❖ Botulinum toxin acts on----->Snap 25

- ❖ Median nerve damaged at wrist there is loss of----->Opposition
- ❖ cyanotic heart disease----->TOP
- ❖ BT increased, PT normal APTT normal----->ITP

- ❖ Tractus solitarius is formed by----->2nd order neuron
- ❖ Individual muscle fiber covered by----->Endomysium
- ❖ normal sperm count with azoospermia. Problem in----->Sertoli cells
- ❖ Middle meningeal artery is a branch----->Maxillary artery
- ❖ water intoxication will have----->Slow pulse (As the condition persists, papillary and vital signs may result including bradycardia and widened pulse pressure. The cells in the brain may swell to the point where blood flow is interrupted resulting in cerebral edema)
- ❖ site for ca prostate metastasis----->Vertebra
- ❖ cause of hepatic adenoma.----->Steroids (Anabolic steroid abuse is common among athletes and is associated with a number of medical complications[1-3]. Reported hepatic complications include cholestasis, elevation of aminotransferases, jaundice, benign hepatic adenomas, and rare cases of hepatocellular carcinoma)



- ✓ Now you can join us Online for MD/MS & Fcps Preparation
- ✓ Complete course in 2months including Past paper discussion
- ✓ Join from anywhere using mobile/laptop using internet
- ✓ 100% feasible with job and 100% time adjustment for students
- ✓ www.fcpsworld.com or Contact 03129684658
- ✓ Hostel Facility is also available (for those who want to join physical classes)



Www.Fcpsworld.com (Institute for Fcps & Md/Ms)

www.facebook.com/FcpsWorld

www.facebook.com/GynaeObsWorld

www.facebook.com/Ophtworld

FILE IS ONLY FOR CLASS STUDENTS (DO NOT SHARE)

- ❖ loss of flexion and supination hx of forceps delivery. Injury is at----->Upper trunk of brachial plexus
- ❖ Pinworm infection in human istransmitted by----->Ingestion of eggs
- ❖ Nerve supply of sternohyoid muscle is----->Ansa cervical
- ❖ muscle in neck----->Sclaneus anterior
- ❖ hx of numbness. MCV 120 deficiency is of----->Vitamin B12 deficiency

- ❖ Femoral sheath formed by----->Fascia iliac and Fascia transversals
- ❖ Dribbling of urine from umbilicus dueto----->Urachus
- ❖ pt normal, Aptt raised. Deficiency is of----->Factor 9
- ❖ Regarding S2 sound----->Has higher frequency than S1
- ❖ exudate contain----->many inflammatory cells

- ❖ Does not provide Active immunity----->Tetanus toxide
- ❖ Major scavengers at site of inflammation----->Macrophages
- ❖ Axillary sheath is continuation of----->Paravertebral fascia
- ❖ Pacinian corpuscles are----->Rapidly adaptive
- ❖ Parasympathetic effect is----->decrease heart rate
- ❖ Delayed gastric emptying is due to----->CCK
- ❖ Sub occipital nerve----->Rectus capitis posterior
- ❖ Pulmonary artery pressure increase in-----> Hypoxia
- ❖ Hypertensive changes in eye----->Av nipping
- ❖ Immediate action of angiotensin II----->Vasoconstriction
- ❖ HB 20. 2cm regular mass in lower pole. Diagnosis----->Carcinoma
- ❖ Percentage of total daily energy required for quiet normal breathing----->5%
- ❖ Patient with EBV is at the risk of----->Burkett lymphoma
- ❖ UMN lesion has----->Hvper-reflexia
- ❖ Separation of shoulder joint with lateral end of clavicle. Ligament is----->Coracoclavicular
- ❖ Myasthenia gravis treated by----->Neostigmine
- ❖ 1st step in clot formation----->Platelets adhesion on vessel
- ❖ Muscle that helps in standing from sitting----->Gluteus Maximus
- ❖ Thumb dermatome----->C6
- ❖ Total body water is measured by----->Anti pyrene
- ❖ Weil felix test is for----->Rickettsia



- ✓ Now you can join us Online for MD/MS & Fcps Preparation
- ✓ Complete course in 2months including Past paper discussion
- ✓ Join from anywhere using mobile/laptop using internet
- ✓ 100% feasible with job and 100% time adjustment for students
- ✓ www.fcpsworld.com or Contact 03129684658
- ✓ Hostel Facility is also available (for those who want to join physical classes)



Www.Fcpsworld.com (Institute for Fcps & Md/Ms)

www.facebook.com/FcpsWorld

www.facebook.com/GynaeObsWorld

www.facebook.com/Ophtworld

FILE IS ONLY FOR CLASS STUDENTS (DO NOT SHARE)

- ❖ **Vertebral bodies stabilized by----->Anterior and Posterior longitudinal ligament**

- ❖ **hx steroids for 10 years, he is at risk for-----> Hyperglycemia**
- ❖ **Albumin cant cross glomerulus due to----->Negative charge**
- ❖ **Thymoma is with -----> Pure red cell aplasia and myasthenia gravis**
- ❖ **hx of gall stones. drug can we give after morphine----->Hyosine**
- ❖ **Remnant of umbilical vein----->ligamentum teres (The ligamentum teres is the obliterated fibrous remnant of the left umbilical vein of the fetus. It originates at the umbilicus. It passes superiorly in the free margin of the falciform ligament.)**
- ❖ **Cabergolin is-----> D2 agonist**

- ❖ **cause of hepatic adenoma----->Aflatoxin**
- ❖ **Down syndrome, after 40 years of most common manifestation----->Alzheimers disease**
- ❖ **80 year old female PT, APTT, INR normal but ecchymosis on hand----->Capillary abnormality**
- ❖ **Vit. C deficiency result in loss of----->Hydroxylation of pro-collagen**
- ❖ **Pain due to parotid gland carried by nerve-----> Auriculo temporal nerve**
- ❖ **hormone works through cyclic amp----->TSH**
- ❖ **Blood supply of the heart depends upon----->Oxygen consumption**
- ❖ **most potent response of body when bp falls below 60mmhg----->CNS ischemic response**

- ❖ **Quatrain malaria is caused by----->Plasmodium malaria**
- ❖ **Name the Premalignant vulva----->Pagets disease**
- ❖ **Cancer due to radiation occurs after----->10 years**
- ❖ **Thirst is mediated by,-----> Angiotensin II**
- ❖ **total perentral nutrition side effect----->Hyperglycemia**
- ❖ **drug for rheumatoid arthritis with gastric ulcer----->Ibuprofen**
- ❖ **hx of fall, has urinary incontinence, nerve roots are----->S2, S3, S4**
- ❖ **After Terminal ileal resection there will be deficity of----->Vitamin B12 (Retention of terminal ileum tends to preserve vitamin B12 absorption capacity. Thus, if more than 60 cm of terminal ileum is removed, fat and B12 malabsorption are likely. The Schilling test is an indicator of the degree of terminal ileal dysfunction)**
- ❖ **Severe diarrhea leads to----->Hyponatremia**



- ✓ Now you can join us Online for MD/MS & Fcps Preparation
- ✓ Complete course in 2months including Past paper discussion
- ✓ Join from anywhere using mobile/laptop using internet
- ✓ 100% feasible with job and 100% time adjustment for students
- ✓ www.fcpsworld.com or Contact 03129684658
- ✓ Hostel Facility is also available (for those who want to join physical classes)



Www.Fcpsworld.com (Institute for Fcps & Md/Ms)

www.facebook.com/FcpsWorld

www.facebook.com/GynaeObsWorld

www.facebook.com/Ophtworld

FILE IS ONLY FOR CLASS STUDENTS (DO NOT SHARE)

- ❖ Cold sensation carried by receptor----->Krause end bulb
- ❖ A soldier returned from siachin with headache and peripheral cyanosis, cause ----->Secondary polycythemia
- ❖ labia majora lymph drainage ----->Medial superficial inguinal LN
- ❖ after excessive sweating pt took water, what will increase----->ICF
- ❖ Shigella causes dysentery by----->Mucosal invasion
- ❖ Content of anterior mediastinum----->Thymus
- ❖ Patient had depressed nasal bridge, caseating granuloma was found, and zn staining positive, Diagnosis-----> Leprosy
- ❖ Malignant melanoma, 1st line of defense----->NK cells
- ❖ Thymus at the age of 10 years----->inferior border of thyroid till 4th costal cartilage.
- ❖ Best thrombolytic for heart disease----->Streptokinase
- ❖ Part of portal system is-----> Hepatic vein

- ❖ GVE of Vagus nerve----->Dorsal motor nucleus
- ❖ Veins open directly into right atrium----->Anterior cardiac vein
- ❖ complain of abdominal pain after meals with fatty stool. Best test----->Stool analysis
- ❖ Ca prostate metastasizes to skull via----->Vertebral venous plexus

- ❖ newborn with epicanthal folds, anomaly is-----> Down syndrome
- ❖ Rete ridges in malignancy is in----->Verrucous Carcinoma
- ❖ doc for Schistosomia----->Praziquantel

- ❖ Stoke of internal capsule with unilateral hemiplegia. location of lesion----->Anterior part of posterior limb
- ❖ Oral-faecal transmission----->Hep. E
- ❖ in Osteogenesis alp is released by----->osteoblast
- ❖ nerve arising from trunk of brachial plexus is-----> Suprascapular nerve
- ❖ Parasympathectomy will have a greatest effect on ----->G1 muscles
- ❖ Glucose absorbed through----->Secondary active transport along with sodium
- ❖ Rods in comparison to cones----->Detect low intensity light
- ❖ Neurosecretory hormone accumulates in----->Nerve endings



- ✓ Now you can join us Online for MD/MS & Fcps Preparation
- ✓ Complete course in 2months including Past paper discussion
- ✓ Join from anywhere using mobile/laptop using internet
- ✓ 100% feasible with job and 100% time adjustment for students
- ✓ www.fcpsworld.com or Contact 03129684658
- ✓ Hostel Facility is also available (for those who want to join physical classes)

Www.Fcpsworld.com (Institute for Fcps & Md/Ms)

www.facebook.com/FcpsWorld

www.facebook.com/GynaeObsWorld

www.facebook.com/Ophtworld

FILE IS ONLY FOR CLASS STUDENTS (DO NOT SHARE)



- ❖ Weight lifted by bodybuilder and suddenly drops involve part is----->Golgi tendon organ
- ❖ Right border of heart is formed by----->Right atrium
- ❖ hx hirsutism, irregular menstrual cycle, she has increased----->Androstenedione
- ❖ Montoux induration due to----->CD4 + cells
- ❖ Posterior fibres of temporalis cause----->Retrusion of mandible (posterior portion has fibers which run horizontally and contraction of this portion results in retrusion of the mandible.)
- ❖ lost sensation of anterior chin up to suprasternal notch. Dermatome involved is----->C4
- ❖ Microbes are removed in lung by-----> H2O2
- ❖ Lambert eaten syndrome----->Antibodies against Ca+ channel
- ❖ Hodgkins lymphoma with best prognosis subtype----->Nodular sclerosing
- ❖ vessel has Maximum CO2 concentration----->Umbilical arteries
- ❖ Gluteus muscles are supplied by----->superior and inferior gluteal nerve
- ❖ Injury to lateral knee, pain on medial side, ligament involved ,----->Tibial collateral ligament
- ❖ hemi-section of spinal cord at thoracic level. Changes are----->hyperreflexia ipsilaterally (poor recall)
- ❖ Bifurcation of common carodd artery at the level of----->Upper border of thyroid
- ❖ Most common cancer occurring radiation----->Meningioma

- ❖ Oocytes complete their first meiotic division-----> Just before ovulation
- ❖ antidote of acetaminophen is----->N acetylcysteine
- ❖ age group has lowest level of testosterone----->Pre school
- ❖ Spinal sensory neurons are-----> Pseudo unipolar
- ❖ Aspirin act to alleviate pain by----->Decrease synthesis of prostaglandins
- ❖ Jaw abscess with draining sinus and yellow granules. organism is ----->Actinomyces
- ❖ Abdominal injury peritoneal bleeding in lesser sac pain transmitted through----->Greater splanchnic
- ❖ Utero umbilical fistula is caused to----->Patent urachus
- ❖ Most common feature of reversiable cell injury----->Cellular swelling
- ❖ Condition associated with decrease PO2----->Hypoventilation



- ✓ Now you can join us Online for MD/MS & Fcps Preparation
- ✓ Complete course in 2months including Past paper discussion
- ✓ Join from anywhere using mobile/laptop using internet
- ✓ 100% feasible with job and 100% time adjustment for students
- ✓ www.fcpsworld.com or Contact 03129684658
- ✓ Hostel Facility is also available (for those who want to join physical classes)



Www.Fcpsworld.com (Institute for Fcps & Md/Ms)

www.facebook.com/FcpsWorld

www.facebook.com/GynaeObsWorld

www.facebook.com/Ophtworld

FILE IS ONLY FOR CLASS STUDENTS (DO NOT SHARE)

- ❖ Rectum has----->Complete muscular wall
- ❖ Loss of thumb opposite, nerve is injured-----> Median nerve
- ❖ Chronic inflammation cause tissue damage----->Toxic free radicals
- ❖ Strongest layer of intestine----->Submucosa
- ❖ During 5th month of intrauterine blood is produced by----->liver
- ❖ Tunica vaginalis is remnant of----->Processes vaginalis
- ❖ Frontal lobe infarct, artery involved----->anterior cerebral artery
- ❖ 3rd degree uterine prolapse ligament responsible----->Uterosacral ligament
- ❖ Pain and temperature sensations are carried by----->Free nerve endings
- ❖ Most common great vessel abnormality----->PDA
- ❖ DOC for MARSAs----->vancomycin
- ❖ Norepinephrine causes----->Local vasoconstriction
- ❖ Adenocarcinoma of colon first spread to-----> Liver
- ❖ Oropharyngeal carcinoma by----->HPV {{{HPV can infect the mouth and throat and cause cancers of the oropharynx (back of the throat, including the base of the tongue and tonsils). This is called oropharyngeal cancer. HPV is thought to cause 70% of oropharyngeal cancers in the United States.}}}
- ❖ Cutaneous sensation is lost on dorsum of thumb due to injury ----->Radial
- ❖ Increase in renin causes----->vaso constriction by angiotensin 2
- ❖ Data obtained in presence or absence of vomiting is----->Nominal
- ❖ Crescent formation in glomerulus is by----->Parietal epithelial cells
- ❖ Sympathetic system activation leads to----->Bronchodilation
- ❖ scenerio of Measles. Feature is ----->Kopliks spot
- ❖ response of body to acidosis----->CNS depression
- ❖ Nor epinephrine effect on the heart is----->Increased diastolic heart rate
- ❖ Grading in a tumour indicates----->Degree of anaplasia
- ❖ the premalignant lesion of breast----->Atypical hyperplasia of duct
- ❖ 11 year old girl, last to ossify on x-ray elbow----->lateral epicondyle



- ✓ Now you can join us Online for MD/MS & Fcps Preparation
- ✓ Complete course in 2months including Past paper discussion
- ✓ Join from anywhere using mobile/laptop using internet
- ✓ 100% feasible with job and 100% time adjustment for students
- ✓ www.fcpsworld.com or Contact 03129684658
- ✓ Hostel Facility is also available (for those who want to join physical classes)



Www.Fcpsworld.com (Institute for Fcps & Md/Ms)

www.facebook.com/FcpsWorld

www.facebook.com/GynaeObsWorld

www.facebook.com/Ophtworld

FILE IS ONLY FOR CLASS STUDENTS (DO NOT SHARE)

- ❖ Foul smelling discharge due to----->Bacteroides fragilis
- ❖ Most malignant is-----> Melanoma
- ❖ A patient known case of CKD wr BUN 3, creatinine 7, of tl following drug is contraindicated----->Gentamycin
- ❖ Inc. PT, APTT, FDP and low PLT-----> DIC
- ❖ common site of rib fracture-----> Angle

- ❖ Fat embolism----->After 12 hours
- ❖ cervical squamous epithelium with pleomorphic cells ----->Dysplasia
- ❖ major support of uterus----->round ligament
- ❖ Virus related cancer----->T- cell leukemia
- ❖ fat soluble anesthetic is ----->More potent
- ❖ After hip fracture with pelvis shifted to one side. Muscle paralyzed is-----> Gluteus medius , gluteus minimus
- ❖ bronchopulmonary segment----->supplied by tertiary bronchioles
- ❖ Nucleus ambiguous present in----->Medulla
- ❖ No surface agglutinins in blood group----->AB+
- ❖ Heparin is released by----->Mast cells

- ❖ In Sepsis poor prognosis due to----->DIC
- ❖ Left gastric artery is a branch of----->Celiac artery
- ❖ Sample of trponema pallidum is to be taken from----->Genital sores
- ❖ Artery that remains in true pelvis is-----> Middle rectal artery
- ❖ Most important in stress----->Cortisol
- ❖ Corneal transparency is maintained by----->Corneal endothelium
- ❖ tall man presented with sudden chest pain and hx of dislocation of crystalline lens. Diagnosis----->Marfan syndrome
- ❖ Earliest manifestation of vitamin Adeficiency----->Night blindness
- ❖ Mode of inheritance of ontogenesis imperfect----->Autosomal dominant

- ❖ Death due to food poisoning result from----->Clostridium botulinum
- ❖ Infant hematocrit is----->55%
- ❖ Baroreceptors reflex increases ----->MAP
- ❖ Renal plasma flow is measured by----->PAH Para-aminohippurate



- ✓ Now you can join us Online for MD/MS & Fcps Preparation
- ✓ Complete course in 2months including Past paper discussion
- ✓ Join from anywhere using mobile/laptop using internet
- ✓ 100% feasible with job and 100% time adjustment for students
- ✓ www.fcpsworld.com or Contact 03129684658
- ✓ Hostel Facility is also available (for those who want to join physical classes)



Www.Fcpsworld.com (Institute for Fcps & Md/Ms)

www.facebook.com/FcpsWorld

www.facebook.com/GynaeObsWorld

www.facebook.com/Ophtworld

FILE IS ONLY FOR CLASS STUDENTS (DO NOT SHARE)

- ❖ Artificial pacemaker placed in heart for defect in conduction----->AV node
 - ❖ remnant of gubernaculum testes----->Scrotal ligament
 - ❖ Veins of brain are direct tributaries of----->Dural sinuses
 - ❖ Blood group agglutinogens-----> Secreted by saliva
 - ❖ Earliest sign of atheroma----->Fatty streaks
 - ❖ Muscle injury indicated by----->CK-MM
 - ❖ Hyoid bone lies at the level of----->C3
 - ❖ at which level crossing of cervical spinal cord occurs----->C7
 - ❖ Left circumflex artery MI effects----->Posterior wall of left ventricle
 - ❖ polyuria due to raised blood glucose----->osmotic effect of glucose (excess glucose ends up in the urine, where it pulls more water and results in more urine)
 - ❖ originate from Posterior ramus of c2 ----->Greater occipital nerve
 - ❖ organism is most likely involved in allergic reactions-----> Mycobacterium tuberculosis
 - ❖ For the initial diagnosis of leprosy-----> Nasal scrapings
 - ❖ Ca pancreas head will lead to----->Obstruction of CBD
 - ❖ gene amplification is feature of----->Neuroblastoma
 - ❖ dietary substance is a carcinogen and play a role in carcinoma esophagus----->Nitrosamines
 - ❖ Femoral head nerve supply-----> Retinacular artery
-
- ❖ Parallel chromosomes held together at chromatid in----->Prophase
 - ❖ Patent lumen of allantois results in.----->Urachal fistula
 - ❖ loss of dorsal foot sensations, no dorsiflexion----->Common perineal nerve at fibular neck
 - ❖ Tumor of breast grading----->
 - ❖ iron deficiency anemia has----->Low MCV, low MCH, low MCHC
 - ❖ Thyroglobulin synthesized by----->Follicular cells
 - ❖ Gastro esophageal junction stabilized or tone increased by-----> Metoclopramide
 - ❖ malnutrition edema is by----->Decreased albumin
 - ❖ Ulnar nerve injury at medial epicondyle injury. Loss of----->Medial 2 lumbricals
 - ❖ Voluntary control of micturition----->Pudendal N
 - ❖ 44yrs female has lost weight over 12 months, she has noticed episodes where her heart beats rapidly and strongly, her pulse is 90bpm and regular, enlarged goiter and



- ✓ Now you can join us Online for MD/MS & Fcps Preparation
- ✓ Complete course in 2months including Past paper discussion
- ✓ Join from anywhere using mobile/laptop using internet
- ✓ 100% feasible with job and 100% time adjustment for students
- ✓ www.fcpsworld.com or Contact 03129684658
- ✓ Hostel Facility is also available (for those who want to join physical classes)

Www.Fcpsworld.com (Institute for Fcps & Md/MS)

www.facebook.com/FcpsWorld

www.facebook.com/GynaeObsWorld

www.facebook.com/Ophtworld

FILE IS ONLY FOR CLASS STUDENTS (DO NOT SHARE)



her ECG shows sinus rhythm. What is her problem----->Standard error of mean & T-Value

- ❖ variceal bleed vessel involve----->Left Gastric Vein
- ❖ A Deficiency of enzyme produced at brush border will cause----->Lactose intolerance

- ❖ Center of micturition----->Pons (also medulla)
- ❖ In shock GFR is low due to----->Low arterial blood
- ❖ ICF differs from ECF in terms of----->PH
- ❖ CO₂ from tissue to lungs is camec----->Bicarbonate ions in plasma
- ❖ Nerve continuation of the medial cord ----- ulnar
- ❖ Loss of supination of arm lesion in ----- musculocutaneous and radial nerve
- ❖ Fatty liver in kwashiorkor----- aflatoxin
- ❖ Organism with multiple discharging sinuses----- Actinomycetes
- ❖ Artery most likely damaged during difficult C-section----- Uterine
- ❖ Lymphatic drainage of skin of glans penis----- Superficial inguinal lymph nodes
- ❖ Inorganic compound causing carcinoma----- Asbestosis
- ❖ In breast CA surgery, Sentinel lymph node is resected to----- Prevent axillary lymph node clearance
- ❖ structure most likely to be damaged during appendectomy is -----Iliohypogastric nerve
- ❖ Structure which leaves the gluteal region by passing above the piriformis muscle----- Superior gluteal artery
- ❖ Person is unable to scratch his back. Muscle most likely involved----- Lattismus dorsi
- ❖ Floor disinfectant after HIV positive surgery -----1% hypochlorite
- ❖ 39 year old lady complain of nausea and vomiting from last 5weeks, after endoscopic biopsy reveal plasma cell, macrophage and t lymphocytes ----- H. Pylori
- ❖ Lymphatic drainage of prostate ----- internal ilic nodes
- ❖ lost eversion, muscle involve----- muscle anterior and posterior tibial
- ❖ Special feature about the epithelium of vagina----- Contains abundant elastic tissue
- ❖ Pan systolic murmur is heard in-----VSD
- ❖ IVC blocked just above azygous, blood goes into-----rt ascending lumbar veins
- ❖ Short gastric artery are the branches of----- Splenic artery
- ❖ Person falls on outstretched hand and injured his wrist. Which structure will get damaged while passing superficial to flexor retinaculum----- Ulnar artery and nerve
- ❖ Clavicle fractured, which muscle injured-----pect major (best in recalled option)



- ✓ Now you can join us Online for MD/MS & Fcps Preparation
- ✓ Complete course in 2months including Past paper discussion
- ✓ Join from anywhere using mobile/laptop using internet
- ✓ 100% feasible with job and 100% time adjustment for students
- ✓ www.fcpsworld.com or Contact 03129684658
- ✓ Hostel Facility is also available (for those who want to join physical classes)



Www.Fcpsworld.com (Institute for Fcps & Md/Ms)

www.facebook.com/FcpsWorld

www.facebook.com/GynaeObsWorld

www.facebook.com/Ophtworld

FILE IS ONLY FOR CLASS STUDENTS (DO NOT SHARE)

- ❖ Pain in right hypogastrium soon after fatty meal ----- due to gallbladder
- ❖ Reticular fibers seen in ----- tonsils
- ❖ Infertility, azospermia due to----- sertoli cell
- ❖ Artery not leaving true pelvis-----middle rectal
- ❖ Treachostomy level ----- 2C-3C (adults) ; C3-C4 (children)
- ❖ Kala azar scenario -----patient from balochistan, sleeps on floor, splenomegaly
- ❖ Anti-mitochondrial antibodies, Pruritus diagnosis ----- PBC
- ❖ Orofecal route-----HEV
- ❖ S3 sound shows-----ventricular filling
- ❖ cheilosis, scaly dermatitis, glossitis due to deficiency of ----- riboflavin
- ❖ in Factor 8 deficiency what can be given ----- cryoprecipitate
- ❖ Daily protein requirements ----- 0.8g/1gm
- ❖ Calcitonin given in ----- Pagets disease
- ❖ Wernicke area lesion result in ----- speaks fluently but no sense
- ❖ bone formed by both intramembranous and endochondrial ossification ----- mandible
- ❖ Patient cant close eye nerve damaged -----facial
- ❖ CBD relation to pancreas is ----- posterior / embedded
- ❖ Highest pH in secretions of ----- pancreas
- ❖ Prolonged APTT is feature of ----- haemophilia
- ❖ Grading shows ----- degree of differentiation
- ❖ Staging show ----- extend of invasion
- ❖ Main support of uterus ----- transverse cervical ligament
- ❖ vaginal prolapse due to weakness of ----- uterosacral ligament
- ❖ During exercise ----- Decrease TPR
- ❖ Clavicle fracture, Cant rotate Arm laterally ----- Teres Minor
- ❖ Prostate MAINLY drains into ----- Internal iliac nodes
- ❖ Proliferation of endometrial ----- Progesterone
- ❖ Skin of glans penis drains into ----- Deep inguinal nodes (superficial if deep is not present)
- ❖ Negative free water loss occurs ----- SIADH
- ❖ Boy with erection loss and breast development hormone responsible ----- prolactin
- ❖ cancer due to radiation ----- meningioma
- ❖ type of narcosis in liver ----- coagulative necrosis
- ❖ Child tumor with blue cells and gene amplification ----- Neuroblastoma
- ❖ Heat kills bacteria by ----- oxidation (ref. heat sterilization)



- ✓ Now you can join us Online for MD/MS & Fcps Preparation
- ✓ Complete course in 2months including Past paper discussion
- ✓ Join from anywhere using mobile/laptop using internet
- ✓ 100% feasible with job and 100% time adjustment for students
- ✓ www.fcpsworld.com or Contact 03129684658
- ✓ Hostel Facility is also available (for those who want to join physical classes)



Www.Fcpsworld.com (Institute for Fcps & Md/Ms)

www.facebook.com/FcpsWorld

www.facebook.com/GynaeObsWorld

www.facebook.com/Ophtworld

FILE IS ONLY FOR CLASS STUDENTS (DO NOT SHARE)

- ❖ Active sodium absorption occurs in ----- colon
- ❖ Submucosal glands found in gut in ----- duodenum (burners gland)
- ❖ Hoarseness of voice and mass in brain nerve involve ----- vagus
- ❖ Prominent U wave on ECG cause is ----- hypokalemia
- ❖ Lady with RTA has risk of ----- fat embolism
- ❖ Liver to body wall attachment -----Falciform ligament
- ❖ Sympathetic Nerve supply of jejunum ----- Greater and lesser splanchnic nerve (parasymp. Is by vagus)
- ❖ Boy fall from cycle, anuria cause ----- rupture of urethra
- ❖ Posterior ventricular grooves content -----posterior interventricular artery and middle cardiac vein
- ❖ Nerve supply of pleura ----- phrenic nerve
- ❖ Neurotoxin that selectively cleaves the synaptic protein SNAP-25 ----- botulinum a and b
- ❖ Post triangle neck ----- Base by middle 3rd clavicle
- ❖ Enzyme to determine Reinfarction -- CKMB
- ❖ Aphasia result from damage to ----- temporal lobe
- ❖ Least in blood ----- Basophils
- ❖ Change of shape cell ----- Dysplasia
- ❖ Structure damage above piriformis ----- superior gluteal artery
- ❖ MAIN lymph drainage of Breast ----- Axillary lymph nodes on axillary vessels
- ❖ Damage in Post triangle muscle damage ----- Trapezius
- ❖ House Officer taking ABGs in ----- heparinized Tube
- ❖ Femoral artery felt at-----Mid inguinal point
- ❖ Superficial to Flexor Reticulum ----- Ulnar Nerve and Ulnar Artery.
- ❖ Common peroneal damageresult in loss of ----- Eversion of foot
- ❖ After running there is echymosis Athlete, can stand but painful ----- plantar rupture
- ❖ What is the least important thing during first interaction with patient-----showing your authority
- ❖ Pregnancy women asked to left semi prone position to dec pressure on ----- IVC
- ❖ I/v urography of 8 years old boy shows normal right kidney but absence of shadow on left side Instead there is small shadow just above the bladder on left side ----- pelvic kidney
- ❖ reticuloendothelial system affected in----- histoplasmosis
- ❖ Pulmonary artery embolism will cause V/Q to ----- Decrease



- ✓ Now you can join us Online for MD/MS & Fcps Preparation
- ✓ Complete course in 2months including Past paper discussion
- ✓ Join from anywhere using mobile/laptop using internet
- ✓ 100% feasible with job and 100% time adjustment for students
- ✓ www.fcpsworld.com or Contact 03129684658
- ✓ Hostel Facility is also available (for those who want to join physical classes)



Www.Fcpsworld.com (Institute for Fcps & Md/Ms)

www.facebook.com/FcpsWorld

www.facebook.com/GynaeObsWorld

www.facebook.com/Ophtworld

FILE IS ONLY FOR CLASS STUDENTS (DO NOT SHARE)

- ❖ V/Q lower than normal in ----- shunt
- ❖ Max o2 is present in ----- Umbilical vein
- ❖ Cholera Food and water ----- resistance to alkaline pH
- ❖ In pregnancy asked to left semi prone position to Dec pressure on ----- IVC
- ❖ I/v urography of 8 years old boy shows normal right kidney but absence of shadow on left side Instead there is small shadow just above the bladder on left side ----- pelvic kidney
- ❖ Vasoconstriction in lungs is caused by ----- hypoxia
- ❖ HIV pt, post-surgery OT floor cleaning agent ----- 1% Hypochlorite
- ❖ Lady in kitchen has cut her middle finger immediately effect----- vasoconstriction (best among recalled options)
- ❖ landmark for NVD ----- ischeal spine (if not then sacral promontory)
- ❖ Difficult C — Section has been done. Which artery will be damage ----- uterine artery
- ❖ Tumor which invade nerve sheet ----- ex pleomorphic adenoma
- ❖ most likely Tumor after radiation ----- Meningioma
- ❖ transmission by Oro-fecal rout ----- HEV
- ❖ site of Pudendal nerve block ----- ischial spine
- ❖ injury to TMJ joint, muscle damage ----- Lateral pterygoid
- ❖ Morphine causes----- tachycardia + miosis
- ❖ Primordial germ cells derived ----- At the end of 3rd week
- ❖ Adrenal gland supply ----- Greater splanchnic nerve
- ❖ Scenario of Splinter hemorrhage ,Bacterial endocarditis best test -----Blood culture
- ❖ Endometrial proliferation is by hormone ----- estrogen
- ❖ Corpus luteum produces ----- estrogen +progesterone +inhibin.
- ❖ Vomiting center is in ----- medulla
- ❖ corpus blood oozing out ----- Corpus hemorrhagicum
- ❖ Corticospinal tract responsible for ----- voluntary movements
- ❖ Aphasia occurs due to damage to ----- temporal lobe
- ❖ Most malignant tumor is ----- melanoma
- ❖ Speak easily but senseless ----- Wernicks area damage
- ❖ Main action of insulin ----- entry of glucose
- ❖ Premature baby, jaundice and easy bruising, mom takes antibiotics in pregnant ----- - vitamin K.
- ❖ RIGOR MORTIS occurs due to ----- Dec. ATP



- ✓ Now you can join us Online for MD/MS & Fcps Preparation
- ✓ Complete course in 2months including Past paper discussion
- ✓ Join from anywhere using mobile/laptop using internet
- ✓ 100% feasible with job and 100% time adjustment for students
- ✓ www.fcpsworld.com or Contact 03129684658
- ✓ Hostel Facility is also available (for those who want to join physical classes)



Www.Fcpsworld.com (Institute for Fcps & Md/Ms)

www.facebook.com/FcpsWorld

www.facebook.com/GynaeObsWorld

www.facebook.com/Ophtworld

FILE IS ONLY FOR CLASS STUDENTS (DO NOT SHARE)

- ❖ Medical student hold 3 book, took next book resulted in Dropped all ----- inverse flexor reflex
- ❖ Drug given have highest 1st pass metabolism----- epinephrine
- ❖ Painful parotid swelling is carried by----- auriculotemporal nerve
- ❖ Steady pressure is sensed by ----- Ruffini corpuscles
- ❖ Estrogen producing tumor ----- Granulosa cell
- ❖ Cytokeratin is ----- Intermediate filament
- ❖ Malignant hyperthermia caused by ----- ryanodine receptors mutation
- ❖ Shortest pro-erythrocyte stage is character of ----- Falciparum
- ❖ In CRF undergoing dialysis, important to monitor ----- K+ [IN CRF creatinine is already raised, we look for K+ levels which may cause arrhythmias)
- ❖ For vitamins deficiency, best advice to take ----- vegetables
- ❖ Reinfarction can be determine by ----- CK MB
- ❖ Good analgesic but not so good anesthesia ----- nitric oxide
- ❖ Nor epinephrine release from ----- Post ganglionic sympathetic nerve fiber
- ❖ Definite sign of ovulation ----- Ferning of cervical
- ❖ Delivery of baby is example of ----- Positive feedback
- ❖ Branch of internal iliac artery remain to true pelvis ----- middle Rectal artery
- ❖ in patient of HIV what is the most likely skin cancer ----- Kaposi sarcoma
- ❖ In Athletes at rest there is ----- increase Stroke volume as compared to normal people
- ❖ Iron deficiency anemia is best diagnosed by ----- serum ferritin
- ❖ Cholangiocarcinoma is caused by ----- Clonorchis sinensis
- ❖ Multiple draining abscess ----- Actinomycosis
- ❖ Musculoskeletal growth changes are seen in which disease ----- Achondroplasia
- ❖ In the formation of thyroid hormone synthesis the first step is binding of iodine to -----
-- B thyroglobulin
- ❖ Caucassian community o positive group ----- 47%
- ❖ In liver disease edema is due to ----- dec oncotic pressure
- ❖ Pus in adductor canal will damage -----Femoral vein
- ❖ Biopsy of axillary node in breast CA because of ----- help in prognosis
- ❖ Premature baby born, most common cardiac abnormality ----- PDA
- ❖ Stress hormone is ----- ACTH (cortisol was not in option, cortisol is secreted due to ACTH, CPSP changed old stem)
- ❖ New born with blue red tumor on face ----- Hemangioma



- ✓ Now you can join us Online for MD/MS & Fcps Preparation
- ✓ Complete course in 2months including Past paper discussion
- ✓ Join from anywhere using mobile/laptop using internet
- ✓ 100% feasible with job and 100% time adjustment for students
- ✓ www.fcpsworld.com or Contact 03129684658
- ✓ Hostel Facility is also available (for those who want to join physical classes)



Www.Fcpsworld.com (Institute for Fcps & Md/Ms)

www.facebook.com/FcpsWorld

www.facebook.com/GynaeObsWorld

www.facebook.com/Ophtworld

FILE IS ONLY FOR CLASS STUDENTS (DO NOT SHARE)

- ❖ Corticosteroids long term adverse effects ----- Osteoporosis
- ❖ Blood is warmed at 37°C before transfusion for the following reason ----- Left to right shift
- ❖ Red–green color blindness ----- X-linked recessive disorders
- ❖ Conversion of one normal epithelium into other normal epithelium ----- Metaplasia
- ❖ proteins cannot pass through basement membrane due to character ----- negative charge
- ❖ responsible for Cyclic AMP messenger ----- TSH
- ❖ neurotransmitters situated at autonomic ganglia is ----- Ach
- ❖ a patient presented with fever and cough since for last 1 month biopsy show epithelioid cells diagnosis is ----- Tuberculosis
- ❖ relation anterior to hilum of right kidney ----- second part of duodenum
- ❖ hormone that remains normal during pregnancy ----- growth hormone
- ❖ finger cut by knife which is primary mediator in acute inflammation ----- histamine
- ❖ type of drug will have maximum oral bioavailability ----- Largely hydrophobic, yet soluble in aqueous solutions.
- ❖ when temperature is set higher than body temperature there is ----- decrease Sweating
- ❖ lymph from fundus of stomach drain ----- celiac LN
- ❖ internal jugular vein after emergence to jugular foramen has relation ----- anterior to internal carotid artery
- ❖ Cretinism different from dwarfism ----- mental retardation
- ❖ nucleus cutenus and nucleus gracilis responsible for ----- astereognosis
- ❖ factor 8 is produced by ----- endothelium
- ❖ Bronchopulmonary segment is aerated by ----- tertiary bronchus
- ❖ Parasympathetic nerves ----- are pelvic splanchnic nerves
- ❖ complication regarding intervention procedures ----- remain within limits of professional competence regarding
- ❖ smooth muscles has larger of ----- both circular and longitudinal muscles
- ❖ Test for amoebic liver abscess ----- serology
- ❖ Dormant state of malaria parasite ----- hypnozoites
- ❖ Organism produce fluorescent pigment and is resistant to beta-lactam ----- pseudomonas



- ✓ Now you can join us Online for MD/MS & Fcps Preparation
- ✓ Complete course in 2 months including Past paper discussion
- ✓ Join from anywhere using mobile/laptop using internet
- ✓ 100% feasible with job and 100% time adjustment for students
- ✓ www.fcpsworld.com or Contact 03129684658
- ✓ Hostel Facility is also available (for those who want to join physical classes)



Www.Fcpsworld.com (Institute for Fcps & Md/Ms)

www.facebook.com/FcpsWorld

www.facebook.com/GynaeObsWorld

www.facebook.com/Ophtworld

FILE IS ONLY FOR CLASS STUDENTS (DO NOT SHARE)

- ❖ Hemoglobin is 10 gram oxygen saturation 90% pO₂ 60 calculate oxygen content -----
13% (1 gm Hb contain 1.34ml Oxygen so 10g × 1.34 = 13.4)
- ❖ Type of necrosis in pancreatitis ----- fat necrosis
- ❖ in dehydration thirst is stimulated by ----- angiotensin II
- ❖ Which of the following crosses Placenta in pregnant female ----- thyroxin
- ❖ during meiosis abnormality may occur if one of the cell gets an extra chromosome
instead of haploid numbers this condition is ----- trisomy
- ❖ Lambert Eaton syndrome has antibodies targeted against ----- voltage-gated
Calcium channel
- ❖ Which of the following is a tumor suppressor gene ----- p53
- ❖ Lymphocyte form blood enter in lymph node via ----- subscapular efferent arteries
- ❖ Which is spore forming bacteria ----- clostridium
- ❖ Upper motor neuron lesion features ----- hyper reflexia
- ❖ liver is attached to interior abdominal wall ----- falciform ligament
- ❖ Thyroglobulin is synthesized ----- follicular cells
- ❖ a patient with hb 15 oxygen content of HB 20 ml PO₂ 45 arterial oxygen 40 oxygen 15
type of hypoxia ----- hypoxic hypoxia
- ❖ Abdominal angina is due to ----- Superior mesenteric artery
- ❖ an isolated complete rupture of anterior cruciate ligament will result in instability of
Tibia over femur the direction of instability will be ----- anterior
- ❖ Pt under gone tubal ligation. Post-operative her abdomen was reopened due to
slippage of ligature hemorrhage. Bleeding most probably from which artery -----
uterine artery
- ❖ Regarding skeletal muscle belly ----- fleshy throughout the length
- ❖ The largest cross section area is ----- capillaries
- ❖ Small cell carcinoma of lung causes ----- Cushing syndrome
- ❖ young patient with decrease urine output BP 160 by 120 has defect -----
juxtaglomerular cells
- ❖ Drug of choice for bacterial meningitis ----- ceftriaxone
- ❖ The joint between vertebral bodies ----- symphysis
- ❖ Major lipoprotein source of cholesterol used in cells ----- LDL
- ❖ A man heard better noise in environment than alone ----- otosclerosis
- ❖ grading determines degree ----- anaplasia
- ❖ used to measure total body water weight ----- antipyrine



- ✓ Now you can join us Online for MD/MS & Fcps Preparation
- ✓ Complete course in 2 months including Past paper discussion
- ✓ Join from anywhere using mobile/laptop using internet
- ✓ 100% feasible with job and 100% time adjustment for students
- ✓ www.fcpsworld.com or Contact 03129684658
- ✓ Hostel Facility is also available (for those who want to join physical classes)



Www.Fcpsworld.com (Institute for Fcps & Md/Ms)

www.facebook.com/FcpsWorld

www.facebook.com/GynaeObsWorld

www.facebook.com/Ophtworld

FILE IS ONLY FOR CLASS STUDENTS (DO NOT SHARE)

- ❖ Involvement of which part of brain control direct autonomic reflexes ----- hypothalamus
- ❖ patient come to you with portal hypotension most commonly dilated ----- esophageal vein
- ❖ Example of drug receptor interaction ----- labetalol bradycardia
- ❖ Albumin RBC cast and cells in urine possible site of damage ----- glomerulus
- ❖ Significantly raised Alpha fetoprotein is characteristic ----- hepatocellular carcinoma
- ❖ gastric pain since three years columnar cells above cardia -----diagnosis metaplasia
- ❖ data collected for some clinics trial based on presence or absence of vomiting what type of data -----nominal data
- ❖ Which cancer has virus etiology ----- T cell leukaemia
- ❖ Strongest layer in git----- submucosa
- ❖ Amen known case of hypertension presented with shortness of breath pulmonary edema cause ----- hydrostatic pressure
- ❖ Pancreatic trypsin enzyme converts to active form with the help of ----- enterokinase
- ❖ Thiazide causes----- hypokalemia
- ❖ Hypo chlorothiazide causes ----- hyperuricemia
- ❖ Mechanism of action of cimetidine ----- inhibit hepatic metabolism
- ❖ Most common lobe of prostate cancer ----- posterior
- ❖ Prostate cancer metastasize via ----- vertebral plexus
- ❖ patient with peptic ulcer has epigastric pain that referred which has pain is mediated by----- greatest splenic nerves
- ❖ A patient with proper relapsed shows increased PT and ptt bleeding time is normal cause ----- deficiency factor 8
- ❖ Structures prone to damage at lateral pelvic wall ----- ovarian artery
- ❖ scenario of bleeding and epistaxis with prolonged bleeding time of 20 minutes diagnosis ----- Von will brand disease (bleeding time is raised defect of platelets)
- ❖ in middle trimester pregnancy hematopoiesis occurs -----liver of fetus
- ❖ Greenish first discharge after Operation. Organism is -----pseudomonas
- ❖ Religion in which area cause resting tremor and expressionless face ----- substantia nigra
- ❖ Regarding left coronary artery ----- supplies bundle of his
- ❖ which muscle extends from femur having role in stability of knee joint -----vastus lateralis



- ✓ Now you can join us Online for MD/MS & Fcps Preparation
- ✓ Complete course in 2months including Past paper discussion
- ✓ Join from anywhere using mobile/laptop using internet
- ✓ 100% feasible with job and 100% time adjustment for students
- ✓ www.fcpsworld.com or Contact 03129684658
- ✓ Hostel Facility is also available (for those who want to join physical classes)



Www.Fcpsworld.com (Institute for Fcps & Md/Ms)

www.facebook.com/FcpsWorld

www.facebook.com/GynaeObsWorld

www.facebook.com/Ophtworld

FILE IS ONLY FOR CLASS STUDENTS (DO NOT SHARE)

- ❖ In hypovolemic shock the decrease glomerular filtration is due to decrease ----- arterial blood pressure
- ❖ Regarding cauda equina anterior and posterior roots of spinal form -----L1 L5
- ❖ Regarding vibrio cholerae transmitted ----- drinking water and uncooked food
- ❖ Oxygen is transferred from alveoli to pulmonary capillaries ----- passive diffusion
- ❖ Heprin is naturally produced ----- mast cells
- ❖ Right ovarian vein drains into ----- inferior Vena cava
- ❖ Cells get stained due to ----- ribosome
- ❖ In which phase of cell cycle are sister chromatid arranged parallel ----- Prophase
- ❖ 5 year boy presented with fever and progressive lithology blood reports head 7 HP WBC 3. 2 10% neutrophil platelets 50 thousand appropriate investigation ----- bone marrow biopsy
- ❖ Structure passes under the free margin of lesser omentum ----- bile duct hepatic artery portal vein
- ❖ Tuberculin test done to patient after 40 hours 15mm erythema is noticed cell responsible for this ----- cytotoxic t cells
- ❖ a patient with bleeding oozing from a site he has developed generalized swelling hb was low reason of swelling ----- decreased albumin
- ❖ Coronary blood flow is mainly maintained by ----- myocardial oxygen demand and consumption
- ❖ spinal grey matter receiving neuron stimulus ----- lamina 1
- ❖ a man involved in RTA with structure you noticed abdomen is moving more during breathing which muscle is helping him breathing -----external intercostal muscle
- ❖ Iron is stored in form of ----- hemosiderin
- ❖ Landmark of pudendal nerve block is ----- ischial spine
- ❖ Raised heterophile antibody titre ----- infectious mononucleosis
- ❖ melenoma normal reaches orbital cavity through ----- Emissary vein
- ❖ how to prevent cross region related cytomegalovirus infection Pakistan ----- screening the blood before transfusion
- ❖ PAS is positive in -----whipples disease
- ❖ Thirst activated by -----extracellular dehydration
- ❖ index of total peripheral resistance in circulation is ----- mean arterial pressure
- ❖ structured lies superficial to sternocleidomastoid -----external jugular
- ❖ Cervical carcinoma lymphatic drainage -----internal iliac lymph node



- ✓ Now you can join us Online for MD/MS & Fcps Preparation
- ✓ Complete course in 2months including Past paper discussion
- ✓ Join from anywhere using mobile/laptop using internet
- ✓ 100% feasible with job and 100% time adjustment for students
- ✓ www.fcpsworld.com or Contact 03129684658
- ✓ Hostel Facility is also available (for those who want to join physical classes)



Www.Fcpsworld.com (Institute for Fcps & Md/Ms)

www.facebook.com/FcpsWorld

www.facebook.com/GynaeObsWorld

www.facebook.com/Ophtworld

FILE IS ONLY FOR CLASS STUDENTS (DO NOT SHARE)

- ❖ Case on cervical cancer a lady has multiple sexual partners cause -----HPV
- ❖ Appendicular artery is branch of ----- iliocolic
- ❖ Membranous ossification Centre----- distal end of femur
- ❖ Loss of abduction at arm nerves involve -----axillary and suprascapular nerve
- ❖ child came in emergency with fever and strider investigation for -----throat swab culture
- ❖ Female press patient present fever rash on tonsil and koplic spots on Oral mucosa diagnosis ----- measles
- ❖ Damage to ulnar nerve at elbow -----medial 2 lumbricals (best in options)
- ❖ Leukocyte resulted phagocytosis ----- neutrophils (macrophages was not an option)
- ❖ Feature of typical neuron nissel granules helps in ----- synthesis of protein
- ❖ Type of cells are mostly abundant in immune system -----helper t cells
- ❖ Silicone breast implant leakage cells of inflammatory ----- giant cells
- ❖ Adenovirus ----- is DNA virus
- ❖ patient with pattern Rose spots on body on palpation abdomen was the investigation -- -----widal test
- ❖ Tumor on lateral surface of tongue lymphatic drainage ----- submandibular lymph node
- ❖ Cause of G6PD hemolysis ----- self limiting hemolysis
- ❖ Esmolol is ----- short acting
- ❖ Infection with tabs tibialis dorsalis cause ----- atonic bladder
- ❖ 20 year girl presented with proximal tibial swelling on Histology both epiphases and diaphasis were involved giant cells seen diagnosis -----giant cell tumor
- ❖ after road traffic accident depressed mood loss of motivation which lobe is involved --- ----- frontal love
- ❖ Potentially motile sperms ----- epidydmus
- ❖ Klinefelter syndrome genotype ----- x x y
- ❖ A player has suffered fracture of right first rib arteries will be damaged----- subclavian damage
- ❖ Main difference between primary and secondary intention wound healing ----- contraction
- ❖ Rich source of vitamin K ----- green leafy vegetables
- ❖ P53 mutation ----- cell survival
- ❖ Nasopharyngeal carcinoma is caused by ----- epstein-barr virus
- ❖ Which organism is associated with bladder cancer ----- schistosoma haematobium



- ✓ Now you can join us Online for MD/MS & Fcps Preparation
- ✓ Complete course in 2months including Past paper discussion
- ✓ Join from anywhere using mobile/laptop using internet
- ✓ 100% feasible with job and 100% time adjustment for students
- ✓ www.fcpsworld.com or Contact 03129684658
- ✓ Hostel Facility is also available (for those who want to join physical classes)



Www.Fcpsworld.com (Institute for Fcps & Md/Ms)

www.facebook.com/FcpsWorld

www.facebook.com/GynaeObsWorld

www.facebook.com/Ophtworld

FILE IS ONLY FOR CLASS STUDENTS (DO NOT SHARE)

- ❖ Internal jugular at subclavian meet to form ----- brachiocephalic
- ❖ Gardener presented with respiratory dress x-ray shows opacity in lower lobe cause ----
----- aspergillosis
- ❖ Antibodies in primary biliary cirrhosis ----- antimitochondrial antibody
- ❖ case in brown squad syndrome ----- contralateral pain and temperature loss below
the level of region
- ❖ in inferior wall MI ----- Right Coronary Artery
- ❖ Proximal muscle flexion is caused by ----- corticospinal tract
- ❖ Follicular carcinoma ----- vascular invasion
- ❖ Foramen caecum give rise to ----- thyroid
- ❖ Which of following tumor secretes serotonin ----- carcinoid tumor
- Pellagra is caused by deficiency of which vitamin----->Niacin
- absorption of glucose in kidneys occurs through ----->Secondary active transport
- antiseptic used to clean the floor after surgery of a HIV ----->1% hypochlorite
- boundaries of Posterior triangle of the neck----->Covered by investing layer of deep
cervical fascia
- breast lesion occurs bilaterally----->Lobular carcinoma
- childhood tumor with gene amplification----->Neuroblastoma
- cystic swelling between labia majora and minora arises from----->Greater vestibular
gland
- factor 8 best source is----->Cryoprecipitate
- hormone stimulates release of FSH and LH----->GnRH
- Least amount of minerals are found in ----->Tubers
- least infarcted in arterial supply blockage ----->Liver
- Lymphatic drainage of labia majora----->Superficial inguinal nodes
- membranous labyrinth, ----->Contains organs of hearing and balance
- mitochondrial mutations----->Only transmitted from mother
- Mononuclear phagocytosis originates from ----->Bone marrow
- neurotransmitter in post synaptic and autonomic nervous system ----->Nor
epinephrine
- numbness of medial arm and atrophy of small muscles of hand. Cause----->Cervical
rib
- organism produce greenish pus discharge from post-op wounds----->Pseudomonas
- pain in the epigastric region after a fatty meal. Cause----->Gall bladder
- painless testicular swelling, biopsy shows mature stem cells. diagnosis----->Teratoma



- ✓ Now you can join us Online for MD/MS & Fcps Preparation
- ✓ Complete course in 2months including Past paper discussion
- ✓ Join from anywhere using mobile/laptop using internet
- ✓ 100% feasible with job and 100% time adjustment for students
- ✓ www.fcpsworld.com or Contact 03129684658
- ✓ Hostel Facility is also available (for those who want to join physical classes)



Www.Fcpsworld.com (Institute for Fcps & Md/Ms)

www.facebook.com/FcpsWorld

www.facebook.com/GynaeObsWorld

www.facebook.com/Ophtworld

FILE IS ONLY FOR CLASS STUDENTS (DO NOT SHARE)

- painless testicular swelling. Labs show increased LDH. diagnosis----->seminoma
- parasympathetic ganglia in sigmoid colon receive preganglionic fibers from which segment of spinal cord----->S2, 3, 4
- premalignant lesion leads to SCC ----->Actinic keratosis
- prolapse uterus and intact anal canal. Damaged structure----->Pelvic diaphragm
- pt develops prolactin excess. cells most likely to be increased----->Eosinophils
- right ventricle has----->Origin of Pulmonary trunk
- structure is not visible in indirect laryngoscope----->Pyramidal sinus
- study in a population comparing symptoms in diseased & lack of symptoms in non-diseased. Type of study----->Case control
- tall man with sudden excruciating chest pain, epigastric pain radiating to the back and dyspnea. With hypotension. Diagnosis----->Dissecting aortic aneurysm
- The primary oocytes complete their first meiotic division ----->Before ovulation
- The skin at areas most prone to abrasions, damage -----> Stratified squamous keratinized
- 2 weeks later after hepatitis A, the liver biopsy will show----->Normal histology
- 41 % of hematocrit means----->41% of formed elements in blood are RBC
- 70 kg has total body water of 42L (60% of body weight). How much of this will be present in interstitial fluid----->11.5L
- 70% of the SA node is supplied by----->RCA
- A lesion in the pyramidal tract ----->loss of Motor function
- A new born baby has amputated limb. cause is----->Amniotic bands
- A patient cannot recognize opposite side of his body. Damaged----->Primary Somesthetic area
- A patient presented on 18th day of her menstrual cycle, phase ----->Secretory
- A person came back from Ireland and now presented with fever, chills, body aches and postural hypotension. ---->Malaria
- A pt with lacerated wound on thigh 5 days back presented with hypotensive & fever. cause----->Toxic shock
- A tire factory worker, exposed to hydrocarbons risk----->Bladder Ca
- A type 1 diabetic with persistent morning hyperglycemia. What should be given ----->Regular Insulin with Intermediate Insulin twice daily
- A young pt with GFR 50%. increase will be----->Creatinine
- Adherence of WBC to endothelium is via----->ICAM



- ✓ Now you can join us Online for MD/MS & Fcps Preparation
- ✓ Complete course in 2 months including Past paper discussion
- ✓ Join from anywhere using mobile/laptop using internet
- ✓ 100% feasible with job and 100% time adjustment for students
- ✓ www.fcpsworld.com or Contact 03129684658
- ✓ Hostel Facility is also available (for those who want to join physical classes)

Www.Fcpsworld.com (Institute for Fcps & Md/Ms)

www.facebook.com/FcpsWorld

www.facebook.com/GynaeObsWorld

www.facebook.com/Ophtworld

FILE IS ONLY FOR CLASS STUDENTS (DO NOT SHARE)



- After a gunshot injury to the cervical vertebra, the patient now is experiencing respiratory distress. Muscle effected----->Diaphragm
 - after bee sting, cell of this type of hypersensitivity are----->Mast cells
 - antithrombotic is present naturally in blood----->Plasminogen
 - Apoptosis is initiated by----->Activation of caspases
 - Area sensitive to inhalational anesthesia ----->Reticular activity system
 - Aspiration is prevented by----->Closure of false vocal cord
 - ATT side effect inability to differentiate between red and green color to his doctor. Drug----->Ethambutol
 - Bells phenomenon ----->Eye globe moves upward when he tries to close his eyes
- Blood is warmed up to 37 degrees before transfusion----->To prevent infection and hypersensitivity (best among options)
- cause of a negative Mantoux test in a TB is ----->Immunosuppressive therapy
 - Chromosomal maneuvering does not occur in----->Asexual reproduction
 - chronic Hep C for many years will show----->Fibrosis and periportal fibrosis
 - Chronic Hypervitaminosis A leads to----->Hepatomegaly
 - circulates least in blood stream ----->Basophils
 - C-myc gene disruption is associated with----->Burkitt lymphoma
 - Co2 transport is an example of----->Negative feedback
 - cyst in kidney of an adult. Pattern----->Autosomal dominant disease
 - Cysticercosis caused by----->Ingesting egg of tenia Solium
 - decreased urine output, increased creatinine and hypertension. Problem in----->Juxtglomerular
 - Defecation carried out by----->Sacral parasympathetic
 - Development of anterior pituitary gland is from----->Outpouching from stomodeum
 - Diagnosis of Amyloidosis is made by----->Rectal biopsy
 - Diagnostic test for diabetic nephropathy is----->Microalbuminuria
 - Diphtheria exotoxin has the most toxic effect on----->Heart
 - disease prevent 25 cholecalciferol conversion to 1,25 cholecalciferol----->Renal failure
 - do not cause increase in edema----->Arteriolar constriction
 - DOC for beta streptococcal pharyngitis (sore throat) ----->Benzathine Penicillin
 - drug quantity in body can decreased by alkalization of urine to increase its excretion----->phenobarbital



- ✓ Now you can join us Online for MD/MS & Fcps Preparation
- ✓ Complete course in 2months including Past paper discussion
- ✓ Join from anywhere using mobile/laptop using internet
- ✓ 100% feasible with job and 100% time adjustment for students
- ✓ www.fcpsworld.com or Contact 03129684658
- ✓ Hostel Facility is also available (for those who want to join physical classes)



Www.Fcpsworld.com (Institute for Fcps & Md/Ms)

www.facebook.com/FcpsWorld

www.facebook.com/GynaeObsWorld

www.facebook.com/Ophtworld

FILE IS ONLY FOR CLASS STUDENTS (DO NOT SHARE)

Urine alkalinization increases the urine elimination of chlorpropamide, 2,4-dichlorophenoxyacetic acid, diflunisal, fluoride, mecoprop, methotrexate, phenobarbital, and salicylate

- During which stage of sleep do theta- waves appear on EEG----->NREM stage 1
- ECF is different to ICF in----->Inorganic Anions
- edematous tonsil with yellow colored abscess. The most likely organism involved is--->Staph aureus
- effect of acidosis on the body----->Increased respiration
- End product of purine metabolism is----->Uric acid
- Excitation of nerve trunk ----->Compound potential
- fall while cycling, presented with anuria. Most likely the lesion is in----->Urethra
- Feature of dysplasia are----->Loss of polarity and architecture
- feature of TB lesion is----->Caseous necrosis
- Fibro vascular tissue with layers of mesothelium. ----->Lung
- First line of defense in lungs is by----->Alveolar macrophages
- flexion at the metacarpophalangeal joints is by----->Lumbrical muscle
- GFR increase when----->Decrease afferent arteriole resistance
- given for Factor 9 in its deficiency----->FFP
- Gonorrhoea diagnosed by----->Gram stain
- has hyaline cartilage----->Larynx
- Heart muscles works as syncytium due to----->Gap junction
- Heat loss through evaporation and non-evaporation depends on----->Core body temperature
- hormone replacement therapy is at increased risk of developing----->Breast cancer

How to access the compliance of patient therapy----->Patient perception of severity of disease and effects after not using the drug

- HX of forcep delivery unable to abduct left shoulder and loss flexion of left elbow and inability to supinate left arm. Most probable injury is to----->Upper brachial plexus

Patients with upper-trunk palsies are unable to use the shoulder to raise the arm away from the body, have weakness in the arm, and may be unable to bend the arm at the elbow. There may be loss of sensation in the shoulder, outside of the arm, and the thumb.

- Hypospadias is due to defect in----->Urogenital folds
- important function of progesterone ----->Endometrial proliferation



- ✓ Now you can join us Online for MD/MS & Fcps Preparation
- ✓ Complete course in 2months including Past paper discussion
- ✓ Join from anywhere using mobile/laptop using internet
- ✓ 100% feasible with job and 100% time adjustment for students
- ✓ www.fcpsworld.com or Contact 03129684658
- ✓ Hostel Facility is also available (for those who want to join physical classes)



Www.Fcpsworld.com (Institute for Fcps & Md/Ms)

www.facebook.com/FcpsWorld

www.facebook.com/GynaeObsWorld

www.facebook.com/Ophtworld

FILE IS ONLY FOR CLASS STUDENTS (DO NOT SHARE)

- In a neonate of 5kg weight, the estimated blood volume will be----->420ml
BloodVol = Weight * AvgBloodVol in Neonates (85)
- In hyperosmotic urine there decrease water flow in----->DCT
- Infection of the first web space will be first drained by----->Infraclavicular lymph node
- inhales 500 mL each breath with respiratory rate 10 Breaths /min. alveolar ventilation----->3500 ml/min
- Insulin independent glucose uptake occurs in----->Hypothalamus / Exercising muscle
- Lacunar ligament is medial rolled up part of----->Reflected inguinal ligament
- Left shift of the oxygen dissociation curve due to low pCO₂ is known as----->Haldane effect
- Longest pro-erythrocyte phase seen in----->P. malariae
- Loud S1, opening snap and mid diastolic rumbling murmur at apex are characteristic finding of----->Mitral stenosis
- Lymphogranuloma venereum is caused by----->Chlamydia trachomatis
- macula densa has----->Deep basal lamina
- Major supply to posterior 1/3rd of the interventricular septum is from ----->RCA
- MCA blood supply----->Insula and opercula
- Mechanism of edema is----->Hypoalbuminemia with salt retention
- Metastatic calcification in kidney is caused by----->Hyperparathyroidism
- Middle thyroid vein drain into----->Internal jugular vein
- Morphine acts on----->meu receptors.
- most common association with urothelial cancer----->Bladder extrophy
- Most common complication of AIDS----->Pneumocystis carini
- Most common spread by blood transfusion is----->Hepatitis B virus
- Mother RH positive and father RH negative conceive a baby. How will you counsel them regarding the child ----->No complications
- multiple rib fractures the abdomen is moving more during breathing. Muscle responsible----->External intercostals
- Muscle cut in episiotomy is----->Superior transverse perineal plus Bulbospongiosus
- Myasthenia gravis shows which type of hypersensitivity----->Type 2
- necrosis is seen in ischemic brain injury ----->coagulative necrosis
- Nerve supply to adrenal medulla is from----->Greater thoracic splanchnic nerve
- Nucleus ambiguous contains----->CN 9,10,11



- ✓ Now you can join us Online for MD/MS & Fcps Preparation
- ✓ Complete course in 2months including Past paper discussion
- ✓ Join from anywhere using mobile/laptop using internet
- ✓ 100% feasible with job and 100% time adjustment for students
- ✓ www.fcpsworld.com or Contact 03129684658
- ✓ Hostel Facility is also available (for those who want to join physical classes)



Www.Fcpsworld.com (Institute for Fcps & Md/Ms)

www.facebook.com/FcpsWorld

www.facebook.com/GynaeObsWorld

www.facebook.com/Ophtworld

FILE IS ONLY FOR CLASS STUDENTS (DO NOT SHARE)

- Outline of a cell is preserved necrosis type ----->Coagulative
- parameters decreased during moderate exercise ----->Total peripheral resistance (TPR)

Total peripheral resistance (tpr)-in anticipation of exercise, the central command increases sympathetic outflow to the heart and blood vessels, causing an increase in heart rate and contractility. venous return is increased by muscular activity and contributes to an increase in cardiac output by the frank-starling mechanism. pulse pressure is increased because stroke volume is increased. although increased sympathetic outflow to the blood vessels might be expected to increase total peripheral resistance (tpr), it does not because there is an overriding vasodilation of the skeletal muscle arterioles as a result of the buildup of vasodilator metabolites (lactate, K^+ , adenosine). because this vasodilation improves the delivery of O_2 , more O_2 can be extracted and used by the contracting muscle.

- Parasympathetic nerves supplying the urinary bladder are----->Pelvic splanchnic nerves
- patellar tendon is tapped, ----->Quadriceps femoris contraction
- Pericardiocentesis is best achieved by passing a needle through----->Left 6th intercostal space at the parasternal border
- Primary tumor of heart in adults is----->Myxoma
- produced by corpus luteum to maintain pregnancy -----> Progesterone
- Regarding carina----->Cartilage running anterioposteriorly at trachea bifurcation
- Regarding spinal nerves----->Exit from intervertebral foramen

Regarding trachoma----->Inclusion cell conjunctivitis

- Remnant of vitellointestinal duct ----->Meckel diverticulum
- Removal of carbohydrate from proteins results in----->Aggregation and precipitation
- Rete ridgesy and increased nuclear to cytoplasmic ratio. Diagnosis ----->Verrocous CA
- Right shift of the Oxy-Hb curve will result in decrease of ----->pH
- risk of asbestos exposure. ----->Malignant mesothelioma
- rupture of bulbar urethra----->Extravasation in Superficial perineal pouch
- S2 heart sound is due to----->Isovolumetric relaxation
- seen in the microscopy of acute appendicitis----->Neutrophils in muscular wall
- sensations of peritoneal irritation by the gastric acid in the lesser sac is carried by----->Greater splanchnic nerve
- similar to Kaposi sarcoma ----->Bacillary angiomatosis
- Small muscle of hand is supplied by----->T1



- ✓ Now you can join us Online for MD/MS & Fcps Preparation
- ✓ Complete course in 2months including Past paper discussion
- ✓ Join from anywhere using mobile/laptop using internet
- ✓ 100% feasible with job and 100% time adjustment for students
- ✓ www.fcpsworld.com or Contact 03129684658
- ✓ Hostel Facility is also available (for those who want to join physical classes)



Www.Fcpsworld.com (Institute for Fcps & Md/Ms)

www.facebook.com/FcpsWorld

www.facebook.com/GynaeObsWorld

www.facebook.com/Ophtworld

FILE IS ONLY FOR CLASS STUDENTS (DO NOT SHARE)

- Sternohyoid s innervated by----->Ansa cervicalis
- Superficial external pudental artery passes through----->Saphenous opening
- T test is used----->To compare 2 categories/groups
- Tetanus in a population can be prevented by giving----->Tetanus Toxoid
- the adverse effect of a drug----->Variable
- The aponeurosis of internal oblique muscle forms----->Posterior boundary of inguinal canal
- The conducting system of the heart lies in----->Sub endocardium
- The drug of choice for severe Clostridium difficile infection is----->Vancomycin
- The esophagus passes through esophageal opening with ----->Vagus nerve and esophageal vessels
- The fastest nerve conduction ----->A Alpha
- The largest total cross-sectional area is of----->Capillaries
- The main support of uterus is by----->Transverse cervical ligament
- The size of muscle reduced after cast was applied for. Cause ----->Temporary decrease of actin and myosin
- Thirst center stimulated by activation of----->Angiotensin 2
- Thoracic duct drain into----->Junction of left subclavian and internal jugular vein
- Tunica vaginalis is remnant of----->Processes vaginalis
- umbilicus, dermatome ----->T10
- uterine prolapse ligament responsible----->Uterosacral ligament
- vaccinated 2 weeks back now develops rash all over body and fever. Hb 14, WBC 7x10 and low large platelet. diagnosis----->ITP
- Virus causes cancer by alteration in----->Proto-oncogene
- Vit K dependent factors are----->Factor 2, 7, 9, 10
- weakness if thenar eminence and impaired sensation in the thumb, index middle and medial side of ring finger. Cause----->Carpel tunnel syndrome
- Which is the most potent anti-oxidant----->Glutathione
- yellow cough sputum organism----->Streptococcus Pneumonia
- hormone causes smooth muscle constriction In Arterioles----->ADH
- lymphadenopathy and Hepato- splenomegaly, anemia and fatigue. On Peripheral blood film unicellular structure can be seen The diagnosis is -----> Kalazar
- released in stress due to surgery-----> ACTH/epinephrin both are correct
- feature of TB-----> Caseous necrosis
- Regarding Smooth muscle, -----> Sustained and slow contraction



- ✓ Now you can join us Online for MD/MS & Fcps Preparation
- ✓ Complete course in 2months including Past paper discussion
- ✓ Join from anywhere using mobile/laptop using internet
- ✓ 100% feasible with job and 100% time adjustment for students
- ✓ www.fcpsworld.com or Contact 03129684658
- ✓ Hostel Facility is also available (for those who want to join physical classes)



Www.Fcpsworld.com (Institute for Fcps & Md/Ms)

www.facebook.com/FcpsWorld

www.facebook.com/GynaeObsWorld

www.facebook.com/Ophtworld

FILE IS ONLY FOR CLASS STUDENTS (DO NOT SHARE)

- complains of decrease urine output, BP 210/160 taking antihypertensives and creatinine raised. Defect is in----> Juxtaglomerular cells
 - Definition of sickness----> Sense of one not feeling well

 - received exchanged transfusion. After 10 days she developed diarrhea and a rash on body. Diagnosis----> Graft versus host disease/Delayed hemolytic reaction (better)
 - Blood group with No agglutinins ---->AB positive
 - The function of femoral canal is---->To provide space during straining
 - type of hepatitis is most likely prevalent in the pregnant women---->Hep E
 - prevents complications regarding the procedure---->Remain within the limits of professional competence

 - A patient with compound fracture of femur and laceration on thigh region. some serosanguinous fluid was oozing from suture site .Cause ----> Foreign body
 - Tumor metaphysis of bone ---->Osteosarcoma
 - common skin tumor associated with HIV is---->Kaposi sarcoma
 - inflammation of throat mediators----> TNF and interleukin
- xAn inflammatory mediator is a messenger that acts on blood vessels and/or cells to promote an inflammatory response. Inflammatory mediators that contribute to neoplasia include prostaglandins, inflammatory cytokines such as IL-1 β , TNF- α , IL-6 and IL-15 and chemokines such as IL-8 and GRO-alpha.
- Neutrophil increase by----> -Granulocyte colony stimulating factor
 - right sided weakness in both upper and lower limb and deviation of angle of mouth to the left while talking. lesion----> Internal capsule

 - Structure which separates superficial and deep part of submandibular gland----> Mylohyoid
 - Damage to common peroneal nerve---->Eversion lost
 - in the last trimester of pregnancy estrogen and progesterone are produced by---->Placenta
 - Similarity between Cardiac and Skeletal muscle is---->Transverse striations
 - Cushings syndrome characteristic----> Abdominal striae
 - Child with blue cell tumor and high catecholamines. Cause---->Neuroblastoma
 - raised in MI in 2nd hour----> CK MB
 - Pterygomandibular raphe attachment---->Superior constrictor & Buccinator



- ✓ Now you can join us Online for MD/MS & Fcps Preparation
- ✓ Complete course in 2months including Past paper discussion
- ✓ Join from anywhere using mobile/laptop using internet
- ✓ 100% feasible with job and 100% time adjustment for students
- ✓ www.fcpsworld.com or Contact 03129684658
- ✓ Hostel Facility is also available (for those who want to join physical classes)



Www.Fcpsworld.com (Institute for Fcps & Md/Ms)

www.facebook.com/FcpsWorld

www.facebook.com/GynaeObsWorld

www.facebook.com/Ophtworld

FILE IS ONLY FOR CLASS STUDENTS (DO NOT SHARE)

➤ agent commonly used to wash floors after surgery---->1% hypochlorite

➤ Post ganglionic sympathetic fibers are present in ---->All spinal nerves

What manages the levels of phosphate and calcium---->Parathyroid hormone serves to increase blood concentrations of calcium. Mechanistically, parathyroid hormone preserves blood calcium by several major effects ... To prevent detrimental increases in phosphate, parathyroid hormone also has a potent effect on the kidney to eliminate phosphate (phosphaturic effect

➤ The most sensitive test for DIC is---->Serum levels of fibrin degradation products (FDP)

➤ Nerve supplying the dura of middle cranial fossa ---->Trigeminal nerve

➤ Amino acid source of DNA---->Histidine

➤ Alveolar ventilation decreased by ---->Hering beurer reflex

➤ Prostate drains mainly into which ----> Internal iliac nodes

➤ weakness of internal rotation of her right arm at the shoulder. Muscle involved---->subscapularis

➤ Co2 transport is an example of---->Negative feedback

➤ All adductors of shoulder lost, damage ---->Posterior cord + upper trunk

➤ Axillary nerve damage will lead to---->15 to 90 degree abduction lost

➤ loss of abduction and proximal upper arm lateral side sensation. Lesion in---->Axillary nerve

➤ Type of cell with no basement membrane --> Ependyma

➤ Supporting cells in pars nervosa are---->Pituicytes

➤ Most sup structure in parotid---->Facial nerve

➤ In Dehydration, water is mainly absorbed from---->PCT

➤ Pap smear showed atypical giant cells with nuclear chromasia and koilocytes. ---->Dysplasia

➤ homonymous hemianopia due to damage of---->Optic tract

➤ presented with weight loss, lethargy and palpitations labs =normal urea, Hyponatremia, hyperkalemia. Cause---->Addisons disease

➤ Renal correction of acute hyperkalemia will result in ----> Acidosis

➤ upper outer quadrant of the breast. The lymphatic drainage ---->Pectoral axillary nodes

➤ Regarding smooth muscles----> Has layers of circular and longitudinal muscle



- ✓ Now you can join us Online for MD/MS & Fcps Preparation
- ✓ Complete course in 2months including Past paper discussion
- ✓ Join from anywhere using mobile/laptop using internet
- ✓ 100% feasible with job and 100% time adjustment for students
- ✓ www.fcpsworld.com or Contact 03129684658
- ✓ Hostel Facility is also available (for those who want to join physical classes)



Www.Fcpsworld.com (Institute for Fcps & Md/Ms)

www.facebook.com/FcpsWorld

www.facebook.com/GynaeObsWorld

www.facebook.com/Ophtworld

FILE IS ONLY FOR CLASS STUDENTS (DO NOT SHARE)

- Drug absorbed mostly through aqueous diffusion---->Diazepam
- Internal spermatic fascia is derived from---->Fascia Transversalis
- Pulmonary smooth muscles has----> O₂ sensitive K channel
- Blood supply of head of femur---->Retinacular artery
- Most common side effect of protamine---->Hypotension
- Radial artery passes between the tendons of---->Brachioradialis and flexor carpi radialis
- Earliest sign of bupivacaine toxicity---->Ringing of ears
- Eosinophils increase in ---->Parasitic
- increased prolactin will show---->Increase in eosinophil
- Immediate mediator of allergic reaction---->Histamine
- biopsy= villous atrophy and gluten free diet doesnt improve his symptoms. the probable diagnosis---->Giardiasis
- Parotid gland swelling. stones in duct are found. atrophic changes are due to---->Apoptosis
- Dilator muscle of ileal opening in the large intestine----> Longitudinal muscle
- amount of CO₂ dissolved in the Plasma at 45mmHg is---->0.027
- newborn---->C shaped vertebral column
- First cry in neonates is necessary for---->Pulmonary function
- In small cell (oat cell) lung carcinoma tumor marker is present----> ACTH
- Regarding Bronchial Asthma, ---->FEV₁/FVC < 65%
- earliest sign of Vit A deficiency---->Conjunctival xerosis
- The muscle which increase the transverse and anteroposterior diameter of thorax is-->External Intercostal
- history of using antimalarial and cola color urine Diagnosis is---->G6PD
- Patient reported with hyperglycemic coma. Which insulin will be used----> Regular insulin
- Insulin secretion is increased due to ---->Secretin
- Total volume of ICF in 70kg adult man ---->28 Liters
- Investigation of choice on pneumonia---->Sputum culture
- Mature lymphocytes were found in a 70-year with anemia, fever and recurrent infection history.cause---->922 translocation
- The difference between the mean of 2 groups is ---->T-test



- ✓ Now you can join us Online for MD/MS & Fcps Preparation
- ✓ Complete course in 2months including Past paper discussion
- ✓ Join from anywhere using mobile/laptop using internet
- ✓ 100% feasible with job and 100% time adjustment for students
- ✓ www.fcpsworld.com or Contact 03129684658
- ✓ Hostel Facility is also available (for those who want to join physical classes)



Www.Fcpsworld.com (Institute for Fcps & Md/Ms)

www.facebook.com/FcpsWorld

www.facebook.com/GynaeObsWorld

www.facebook.com/Ophtworld

FILE IS ONLY FOR CLASS STUDENTS (DO NOT SHARE)

- Calcitonin is a tumor marker for---->Thyroid
- thermoregulation receptors----> Long Receptive Field
- Virus cause cancer by---->Proto oncogene
- Cabergoline acts on ----> D2 agonist
- Immediate effect of Local anesthesia on ---->C-Fibers
- regarding fat embolism is---->Symptoms appear after 12 hours
- Difference btw PCT and DCT is---->PCT has extensive brush borders
- Relation anterior to hilum of the right kidney is---->Second part of duodenum
- Organ which removes 70-80% oxygen of its arterial supply at rest---->Heart
- Circadian rhythm is controlled by---->Supra chiasmatic nucleus
- Killed whole organism used as vaccine for---->Whooping cough
- Thirst center stimulated by activation of---->Angiotensin 2
- TPN included problem will be----> Hyperglycemia

- Sarcoidosis is diagnosed microscopically by---->Granuloma with asteroid
- ACTH increase in blood, ACTH would be found in---->Venous blood of anterior pituitary
- Mixed venous blood sample can be obtained from ---->Pulmonary arteries
- lymph nodes drains the fundus of stomach---->Celiac nodes
- Terminal part of CBD in relation to pancreas is that it----> Lies posteriorly
- trachea starts---->C6
- 60% of SA node is supplied by---->RCA
- A shoulder separation that involves the lateral end of the clavicle sliding onto the superior aspect of the acromion would most likely result from damage to the ----> Coracoclavicular ligament
- Gummatous necrosis occurs in----> Syphilis
- extraction of upper molar tooth, patient presents with swollen face and nasal discharge. route of spread of infection---->Maxillary sinus

- if hypertensive, presented with shortness of breath (pulmonary edema), cause---->Increase hydrostatic pressure
- generalized edema and proteinuria of 3.6 gm in 24 hours. Cause---->Decreased colloid osmotic pressure
- on mandibular marginal pulsation which artery ---->Facial
- Most abundant glial cells in gray matter ---->Protoplasmic astrocyte



- ✓ Now you can join us Online for MD/MS & Fcps Preparation
- ✓ Complete course in 2months including Past paper discussion
- ✓ Join from anywhere using mobile/laptop using internet
- ✓ 100% feasible with job and 100% time adjustment for students
- ✓ www.fcpsworld.com or Contact 03129684658
- ✓ Hostel Facility is also available (for those who want to join physical classes)



Www.Fcpsworld.com (Institute for Fcps & Md/Ms)

www.facebook.com/FcpsWorld

www.facebook.com/GynaeObsWorld

www.facebook.com/Ophtworld

FILE IS ONLY FOR CLASS STUDENTS (DO NOT SHARE)

- Man moving up in elevator, balance by ---->Saccule
- Right crus of diaphragm Arises from ---->L1, L2, L3
- The roof of the anterior horn of the lateral ventricle is formed by ---->Body of corpus callosum
- Origin of diaphragm...---->Cervical somites
- What type of Necrosis seen in heart ---->Coagulative necrosis
- peripheral blood picture shows low Hb and raised MCV. ---->Folic acid deficiency
- The left atrium is supplied by ---->LCX
- Most common cause of venous thrombosis ---->Prolonged immobilization
- hormone remains normal during pregnancy ---->Growth hormone

- segment of ECG coincide with a-wave of JVP ---->PR interval
- Function and development of seminiferous tubule requires ---->FSH and androgen
- plot standard deviation with mean on graph ---->Variability in data
- Blood show Hb 10, platelets normal. BT more than 27mins, APTT 28s. diagnosis---->VWD
- L-dopa inhibit which hormone in lactating mother----> Prolactin
- Low doses of aspirin reduce platelet aggregation and clot formation by inhibiting the production of---->Thromboxane A2
- Alcoholic patient came with bleeding at base of hair in scalp. cell is defective----> Fibroblasts
- affected by action of beta 2 adrenergic----> Glycogenolysis
- Peripheral smear show Large Platelets & count 45000, diagnosis---->Bernard-Soulier syndrome
- overnight petechial spots & 2 weeks back he had history of abdominal pain and no hepatosplenomegaly. Diagnosis is ---->Idiopathic thrombocytopenic purpura
- BP less than 60. effect is most pronounced---->CNS ischemic response
- Ptosis after trauma, lesion at which site---->T1-T4
- Function exclusive to liver----> Urea production
- Difference b/w Anaphylactic and hypovolemic shock is ---->CO
- early open neural tube defect which one of the following is used for screening ----> Ultrasound
- Most common site of lodging of ureteric stone is----> Pelvic brim when crossing the iliac artery



- ✓ Now you can join us Online for MD/MS & Fcps Preparation
- ✓ Complete course in 2months including Past paper discussion
- ✓ Join from anywhere using mobile/laptop using internet
- ✓ 100% feasible with job and 100% time adjustment for students
- ✓ www.fcpsworld.com or Contact 03129684658
- ✓ Hostel Facility is also available (for those who want to join physical classes)



Www.Fcpsworld.com (Institute for Fcps & Md/Ms)

www.facebook.com/FcpsWorld

www.facebook.com/GynaeObsWorld

www.facebook.com/Ophtworld

FILE IS ONLY FOR CLASS STUDENTS (DO NOT SHARE)

- Jaw fracture, fix with wiring now draining abscess yellow in color organism is----
>Staph, aureus
- autosomal dominant disease who dont express it phenotypically---->Incomplete penetrance
- Correct pairing of reflex---->Biceps - C5, C6
- multiple abscesses in neck region draining sinus outside. organism ---->Actinomyces Israeli
- Osteomyelitis of mandible. Organism involved is---->Staph Aureus
- Inguinal swelling cough impulse positive swelling moves down n medial by pulling testis----> Inguinal hernia
- Cause of increase pulse pressure---->Increase Stroke volume
- sister and mother dying of metastatic breast CA before the age of 40. gene responsible---->BRCA-1 mutation
- smoker with increasing retrosternal pain and progressive dysphagia, . the most likely dx ----> Esophageal carcinoma
- Rupture of #bulbar urethra urine leaks into ---->Superficial perineal pouch
- Most accurate measure of GFR is by---->Inulin
- Liver biopsy shows onion skin lesion. diagnosis ----> Ulcerative colitis

- Hospital acquired wound infection is caused by----> Staph aureus
- The roof of the anterior horn of the lateral ventricle is formed by----> Body of corpus callosum
- unable to abduct left shoulder, loss of active flexion of left elbow and inability to supinate left arm. Most probably injury is to---->Upper brachial plexus
- Inc in no. Of mitochondria ---->Self-Replication
- Amoebic liver abscess labs---->Serology b CT scan
- Most common site of peanut lodgment is----> Right inferior lobe
- Pancreatic trypsinogen enzyme converted to active form trypsin by help of ---->Enterokinase
- Pain on forehead, HSV is confirmed, nerve involved---->Ophthalmic
- Diabetic patient with 600 RBS , suffering from and polyuria which is due to;---->Increased glucose excretion by PCT
- Most common side effect of thiazides is----> Hypokalemia
- benign tumor---->Warthin
- Final common Motor pathway---->Alpha efferent of spinal motor neuron



- ✓ Now you can join us Online for MD/MS & Fcps Preparation
- ✓ Complete course in 2months including Past paper discussion
- ✓ Join from anywhere using mobile/laptop using internet
- ✓ 100% feasible with job and 100% time adjustment for students
- ✓ www.fcpsworld.com or Contact 03129684658
- ✓ Hostel Facility is also available (for those who want to join physical classes)



Www.Fcpsworld.com (Institute for Fcps & Md/Ms)

www.facebook.com/FcpsWorld

www.facebook.com/GynaeObsWorld

www.facebook.com/Ophtworld

FILE IS ONLY FOR CLASS STUDENTS (DO NOT SHARE)

- During Voluntary muscle contraction----> Both alpha and gamma motor neuron in descending pathway are excited
- The oocyte released during ovulation is called---->Secondary oocyte
- Acrosome in spermatid is formed---->Golgi bodies
- During LP after crossing flavum at L3, L4 the needle touches which structure first ---->Epidural space
- Regarding pia mater .---->Extends into sulci and fissures of brain tissue
- Test for patients with purpura and ecchymosis ----> Platelet count
- A farmer presented with right lower lobe coin like mass 3.4cm in size. The most common cause is---->Aspergillosis
- Dilation of esophagus will compress which part of heart----> Left Atrium
- A thyroid mass usually moves- with swallowing because the thyrofc gland is enclosed by fascia----> Pretracheal fascia
- smoker .Primary site of tumor origin---->Lungs
- Regarding Cimetidine-sucralfate interaction---->Sucralfate prevent cimetidine absorption
- Lymph flow is decreased by----> Hemorrhage
- substances is produced by the action of lipoxigenase on arachidonic acid, is a potent chemotactic factor ---->Leukotriene B4
- Excitation of nerve trunk is shown by----> Compound potential
- In venous blood RBCs have----> More CL
- Nerve supply to adrenal medulla is from ----> Greater thoracic splanchnic nerve
- Virus associated with Nasopharyngeal Ca----> EBV
- Klinefelter Syndrome karyotype---->47 XXY
- testicular swelling. Biopsy shows mature specialized cells. Diagnosis---->Teratoma

T lymphocytes are protected from autoimmune destruction by---->Blood thymus barrier

- sign of cerebellar disease is---->Dysdiadokokinesia
- 60% of SA node is supplied by---->RCA
- 80% Oxygenated blood---->Umbilical vein
- fracture of pelvic bone in RTA with shock. Most likely cause of shock is----> Excessive blood loss
- PT normal APTT 60 sec and BT 6 min. the defect----> Intrinsic pathway



- ✓ Now you can join us Online for MD/MS & Fcps Preparation
- ✓ Complete course in 2months including Past paper discussion
- ✓ Join from anywhere using mobile/laptop using internet
- ✓ 100% feasible with job and 100% time adjustment for students
- ✓ www.fcpsworld.com or Contact 03129684658
- ✓ Hostel Facility is also available (for those who want to join physical classes)



Www.Fcpsworld.com (Institute for Fcps & Md/Ms)

www.facebook.com/FcpsWorld

www.facebook.com/GynaeObsWorld

www.facebook.com/Ophtworld

FILE IS ONLY FOR CLASS STUDENTS (DO NOT SHARE)

- smoker is working at a tire factory. cause of carcinoma in him---->Smoking
- given hyperbaric oxygen goes into respiratory distress. Cause---->Spontaneous pneumothorax
- compound fracture of femur After few days wound was healing well with some serosanguinous fluid oozing ----> Foreign body
- A patient with known HBV infection comes with HBsAg +ve, HBeAg +ve, HBc Ab IgM +ve. the diagnosis----> Acute hepatitis
- A pregnant lady with labor pains and obstructed labor was taken to the hospital but died before reaching to the hospital. Most likely cause is----> Amniotic fluid embolism
- Alcoholic man presented with abdominal pain, serum amylase level came to be 1600, ALT 75, your diagnosis---->Acute pancreatitis
- APTT prolong. PT & BT normal, cause ---->Factor 8 deficiency
- artery lies almost behind the sternum----> Internal thoracic artery (ascending aorta is directly behind sternum)
- Bifurcation of Trachea at vertebral Level of---->T4
- Blood supply of head of femur---->Retinacular artery
- Carcinoma (adenocarcinoma)of colon will metastasize first to----> Liver
- common cause of hyperthyroidism---->Graves disease
- Cranial nerve causing Salivation---->IX
- Cysticercosis caused by < ingestion---->Pork
- Dorsal nucleus of vagus nerve is present at----> Medulla
- drug increases the esophageal sphincter tone and gastrointestinal motility---->Metoclopramide
- DVT triad---->Endothelial damage, increase viscosity, stasis (SHE)
- factor wont delay the healing----> Sutures
- feature for malignant tumor----> Invasion of adjacent tissue
- Ferrous form of iron---->Hemoglobin
- fluid given indehydration, initially decrease ICF and increase ECF and increases total body water---->3% normal saline
- function of cerebellum---->Maintain gait
- Gustatory sweating after superficial Parotidectomy. nerve damaged is---->Auriculotemporal nerve
- history of intake of continuous antibiotics by mother which vitamin will be deficient -> VitK

Hypercalcemia will lead to formation of ---->24,25 hydroxycholecalciferol



- ✓ Now you can join us Online for MD/MS & Fcps Preparation
- ✓ Complete course in 2months including Past paper discussion
- ✓ Join from anywhere using mobile/laptop using internet
- ✓ 100% feasible with job and 100% time adjustment for students
- ✓ www.fcpsworld.com or Contact 03129684658
- ✓ Hostel Facility is also available (for those who want to join physical classes)

Www.Fcpsworld.com (Institute for Fcps & Md/Ms)

www.facebook.com/FcpsWorld

www.facebook.com/GynaeObsWorld

www.facebook.com/Ophtworld

FILE IS ONLY FOR CLASS STUDENTS (DO NOT SHARE)



- immediate effect of Insulin---->Potassium entry into the cell
- In a study, a population was divided into subgroups based on age and from each subgroup the samples were taken randomly. Such sampling is known as----> Stratified random sampling
- In lesion distal to optic chiasma on left side, the visual defect will be----> Right homonymous hemianopia
- In primary dehydration, ECF becomes----> Hypertonic
- Inc Serum Ca⁺⁺, Inc PTH, Dec serum PO₄, inc urine Calcium and hematuria diagnosis-->Primary Hyperparathyroidism
- Injury in the region of anatomical snuff box resulted in severe bleeding due to injury of---->Radial artery
- Injury to sacral segments of spinal cord cause----> Autonomous bladder causing continuous dribbling
- Left accessory hepatic artery arise from---->Left Gastric artery
- Mean is----> Sum of all values divided by total
- medial to Thyroid gland----> Recurrent laryngeal nerve
- most common lobe involved in prostate carcinoma is---->Posterior
- Most radiosensitive tumor---->Seminoma
- Muscle open mouth---->Lateral pterygoid
- Night blindness in due to deficiency of----> Retinol
- nucleus will activate to lose heat from the body---->Anterior hypothalamus
- Organism in Surgery of Abdomen ----> Bacteroides fragilis

- Oxidative burst of neutrophils is related to----> Initiation of microbicidal killing
- pain in parotid region, is aggravated by chewing. nerve involved---->Auriculotemporal
- Paraneoplastic Include---->Small cell Ca
- part of nephron the most hypotonic urine will be present---->DCT
- Patient diagnosed with terminal ovarian cancer. Told you not to tell her family. what do you---->Tell them nothing
- Patient presented with blood values of pH. 7.52, HCO₃ 38.2, PCO₂ 31.----> Uncompensated metabolic alkalosis
- Patient with abdominal bloating and foul smelling stools. Test---->Stool D/R
- pituitary----> Laterally to cavernous sinus
- Post ganglionic sympathetic fibers are present in----> All spinal nerves
- post thyroidectomy. Hoarseness of voice. Damage to---->Post Cricoarytenoid



- ✓ Now you can join us Online for MD/MS & Fcps Preparation
- ✓ Complete course in 2months including Past paper discussion
- ✓ Join from anywhere using mobile/laptop using internet
- ✓ 100% feasible with job and 100% time adjustment for students
- ✓ www.fcpsworld.com or Contact 03129684658
- ✓ Hostel Facility is also available (for those who want to join physical classes)



FILE IS ONLY FOR CLASS STUDENTS (DO NOT SHARE)

- Pregnant Lady (Amenorrhea of twenty weeks) presented with increased fundal height Change in uterus is---->Hypertrophy Plus Hyperplasia
- Prostaglandins are secreted into semen by ---->Seminal vesicles
- psuedostratified epithelium ----> All cell reach basement membrane

Pt with peptic ulcer has epigastric pain, the referred visceral pain is mediated by----> Vagus nerve

- Pubic symphysis is----> Secondary cartilaginous
- Pus contains---->Dead Neutrophils
- Regarding Lymph node---->Drain tissue fluid
- Right leg pain. Right leg cordotomy was performed which tract was involved---->Jeft lateral spinothalamic tract
- soldier after retiring from Siachen presents to with complains of headache and peripheral cyanosis of his fingers. cause is----> Secondary polycythemia
- Suppuration in abscess is caused by---->Neutrophils
- Tactile sensations from the finger Tips are detected by which receptors---->Meissner
- terminal ileum and ileocecal junction resection result in deficiency of ---->Vit B12
- The ground substance of Fibrocartilage has abundant of----> Collagen
- Therapeutic and toxic side effect of Loop diuretics is----> Low blood volume
- thick yellow mucoid sputum, most likely organism.---->Staph pneumonia
- traffic accident& lost blood result in anemia type---->Normocytic normochromic anemia
- transmitted through Orofecal route---->Hep E

The hepatitis A and E virus, transmitted mainly by oro-fecal route

- upper outer quadrant of the breast. Lymphatic drainage ---->Pectoral axillary nodes
- Vitamin E activity---->Antioxidant Activity
- weight loss palpitations hypertension diarrhea your diagnosis---->Hyperthyroidism
- A diabetic with jaw draining abscess. Histological findings seen will be---->Granuloma with Abscess (best among answers)
- A young medical student already holding 3 books want to pick up a fourth book from the library. Upon holding the fourth book, she drops all the book. This is most likely due to---->Inverse stretch reflex
- abduction of upto 40 degree is by---->Supraspinatus
- abundant mucinous glands with few serous glands and also few ducts were seen. ----> Submandibular



- ✓ Now you can join us Online for MD/MS & Fcps Preparation
- ✓ Complete course in 2months including Past paper discussion
- ✓ Join from anywhere using mobile/laptop using internet
- ✓ 100% feasible with job and 100% time adjustment for students
- ✓ www.fcpsworld.com or Contact 03129684658
- ✓ Hostel Facility is also available (for those who want to join physical classes)



Www.Fcpsworld.com (Institute for Fcps & Md/Ms)

www.facebook.com/FcpsWorld

www.facebook.com/GynaeObsWorld

www.facebook.com/Ophtworld

FILE IS ONLY FOR CLASS STUDENTS (DO NOT SHARE)

- AFP is raised in----> Anencephaly
- After cast is removed and his calf muscles show reduced muscle mass. This is----> Dec work load
- After surgery wound is not healing properly. he is taking diet rich in proteins and carbohydrate, reason of poor wound healing----> Decrease tensile strength of wound
- Amino acids which are Ketogenic ---->Lysine + Leucine
- Amoeba commonly resides in---->Cecum
- autosomal recessive disorder---->Alpha-1 -antitrypsin deficiency
- Bar body present in---->Neutrophils
- Baroreceptor reflex increases ----> MAP
- bicep tendon reflex is absent .where the compression is---->C5-C6
- Boundaries of Posterior triangle of the neck---->Covered by investing layer of deep cervical fascia
- Breast carcinoma T3 N2 M0---->III-A
- Carotid and Aortic receptors get activated by----> Decreased O₂
- Cause of atheroma---->Diastolic HTN
- child history of burn got treatment after 24 hours he developed edema due to----> Endothelial retraction
- Clavicle fracture at outer 1/3 & inner 2/3. Inner clavicle elevated by which muscle---->Sternocleidomastoid
- Common Hepatitis in Asia with less complications---->Hep A
- Correct about Supra renal gland---->Supplied by Thoracic sympathetic trunk
- CXR show gut loops in left side of the pleural cavity. the likely cause---->Pleuroperitoneal defect
- Damage to basal ganglia will lead to---->Abnormal involuntary movements
- damaged in incision on Mcburneys point ----> Iliohypogastric nerve
- Deep palmar arch is formed by---->Radial artery
- Direct inguinal hernia lies---->Medial to inferior epigastric vessels
- DOC in Pseudomonas UTI---->Ceftazidime
- drugs will have maximum oral bioavailability---->Largely hydrophobic, yet soluble in aqueous solutions
- During Exercise blood flow to which organ decreases---->Splanchnic
- During lumbar puncture CSF is drained from----> Subarchanoid space
- Effect of norepinephrine on heart----> Increase in rate of SA node depolarization
- Energy expenditure in inspiration---->0.05



- ✓ Now you can join us Online for MD/MS & Fcps Preparation
- ✓ Complete course in 2months including Past paper discussion
- ✓ Join from anywhere using mobile/laptop using internet
- ✓ 100% feasible with job and 100% time adjustment for students
- ✓ www.fcpsworld.com or Contact 03129684658
- ✓ Hostel Facility is also available (for those who want to join physical classes)

Www.Fcpsworld.com (Institute for Fcps & Md/Ms)

www.facebook.com/FcpsWorld

www.facebook.com/GynaeObsWorld

www.facebook.com/Ophtworld

FILE IS ONLY FOR CLASS STUDENTS (DO NOT SHARE)



- Enzymes act by---->Decreasing the activation energy
- Epiploic foramen is bounded inferiorly by----> 1st part of duodenum
- Factor deficiency that causes coagulation rather than bleeding ----> Factor 5
- Factor increase renin----> Sympathetic stimulation via renal nerve
- Fecal incontinence----> Damage to external anal sphincter
- Femoral hernia gets strangulated due to---->Narrow neck of sac
- Function of Sertoli cells----> Aid in spermiogenesis
- G-protein phospholipase-C results in---->IP3
- HB formed by Yolk Sac---->Gower
- HCO₃ absorption occurs in which part of the nephron----> PCT and collecting

Hyaline cartilage is present in---->Larynx

- Hypothyroidism due to thyroid gland disease is associated with increased level of---->Cholesterol
- In embryo Primordial germ cells are formed at ---->3rd week
- Inc in no. of mitochondria by---->Self-Replication
- Inferior Thyroid artery is branch of---->Thyrocervical trunk
- Injection in gluteal can damage to---->Superior gluteal nerve
- Internal body environment is regulated by----> Negative feedback mechanism
- LCX (Left Circumflex Artery) block area affected---->Left atrium + left ventricle
- main objective of Screening test for Cancer----> Early Diagnosis
- Most common feature of carpal tunnel syndrome---->Wasting of thenar muscles
- Most common Pituitary tumor cells----> Acidophils
- Muscle have ---->Desmin
- On 2nd day of life breast feeding baby present with jaundice indirect bilirubin 8.5 mg/dL, total bilirubin is 9 mg/dL, diagnosis---->Physiological jaundice
- ovarian cancer Tumor marker will be---->CA-125
- Parotid duct opens at---->Upper 2nd Molar
- Patient had RTA then loss of skin sensation on lateral side of arm---->Axillary nerve
- Patient having ST elevation in Lead 2 and complete heart block vessel involved---->RCA
- Patient with decrease neutrophils. Increase lymphocytes and eosinophils. Increased ACTH level. Diagnosis----> Addison's Disease
- Persistent increase renin occurs in---->Secondary hypertension
- Popliteal Lymph node enlarged .Infection primary site most probably will be----> Lateral side of foot



- ✓ Now you can join us Online for MD/MS & Fcps Preparation
- ✓ Complete course in 2 months including Past paper discussion
- ✓ Join from anywhere using mobile/laptop using internet
- ✓ 100% feasible with job and 100% time adjustment for students
- ✓ www.fcpsworld.com or Contact 03129684658
- ✓ Hostel Facility is also available (for those who want to join physical classes)



Www.Fcpsworld.com (Institute for Fcps & Md/Ms)

www.facebook.com/FcpsWorld

www.facebook.com/GynaeObsWorld

www.facebook.com/Ophtworld

FILE IS ONLY FOR CLASS STUDENTS (DO NOT SHARE)

- Prostatic cancer metastasize to---->Vertebrae
- Pt presented with severe trauma and he has lost huge blood what can be given emergency situation----> Blood O-
- Regarding Bronchopulmonary segment----> Aerated by tertiary bronchus
- right sided weakness in ipsilateral limb and deviation of angle of mouth to the left while talking. lesion----> Internal capsule

Lesions result in a contralateral hemiparesis or hemiplegia.

- stab wound 3 cm vertical on lateral right side of linea alba. vessel is damaged----> IVC
- Superior mesenteric vein and splenic vein join to form portal vein at ----> Behind neck of pancreas
- tall T waves on ECG ---->Hyperkalemia
- The best parameter for fluid resuscitation in hypovolemic shock is----> Increase in urine output
- The first pass metabolism of a drug can be avoided if given via---->Sublingual
- The internal anal sphincter receives its nerve supply from the ----> Hypogastric plexuses.
- The muscle which increase the transverse and anteroposterior diameter of thorax is--> External Intercostal
- Traotbs Solitarius is formed by----> 2nd order neurons
- trauma with bleeding of 2L. The initial response to injury is---->Vasoconstriction
- Type of hypersensitivity reaction in myasthenia gravis is----> Type II
- Ulcer caused by anaerobic staphylococcus---->Venous
- unequal BP reading in both the arms. visible intercostal pulsation and X-ray shows notching of ribs. Diagnosis----> Post ductal aortic coarctation

aortic narrowing, is a congenital condition whereby the aorta is narrow, usually in the area where the ductus arteriosus (ligamentum arteriosum after regression) inserts. Preductal coarctation The narrowing is proximal to the ductus arteriosus. Blood flow to the aorta that is distal to the narrowing is dependent on the ductus arteriosus; therefore severe coarctation can be life-threatening. Preductal coarctation results when an intracardiac anomaly during fetal life decreases blood flow through the left side of the heart, leading to hypoplastic development of the aorta. This is the type seen in approximately 5% of infants with Turner syndrome.[4][5] Ductal coarctation The narrowing occurs at the insertion of the ductus arteriosus. This kind usually appears when the ductus arteriosus closes. Postductal coarctation The narrowing is distal to the insertion of the ductus arteriosus. Even with an open ductus arteriosus, blood flow to



- ✓ Now you can join us Online for MD/MS & Fcps Preparation
- ✓ Complete course in 2months including Past paper discussion
- ✓ Join from anywhere using mobile/laptop using internet
- ✓ 100% feasible with job and 100% time adjustment for students
- ✓ www.fcpsworld.com or Contact 03129684658
- ✓ Hostel Facility is also available (for those who want to join physical classes)



Www.Fcpsworld.com (Institute for Fcps & Md/Ms)

www.facebook.com/FcpsWorld

www.facebook.com/GynaeObsWorld

www.facebook.com/Ophtworld

FILE IS ONLY FOR CLASS STUDENTS (DO NOT SHARE)

the lower body can be impaired. This type is most common in adults. It is associated with notching of the ribs (because of collateral circulation), hypertension in the upper extremities, and weak pulses in the lower extremities. Postductal coarctation is most likely the result of the extension of a muscular artery (ductus arteriosus) into an elastic artery (aorta) during fetal life, where the contraction and fibrosis of the ductus arteriosus upon birth subsequently narrows the aortic lumen

- Uterus cancer travels to labia majora through which route---->Round ligament
- when he stands on his left leg his right hip sinks down. Lesion is at which level----> Left gluteus minimus paralysis

membranous labyrinth,---->Contains organs of hearing and balance

- analgesic for post OP asthmatic patient---->Paracetamol
- in chronic renal failure structure hypertrophied is ----> Parathyroid gland
- Hypertrophy and hyperplasia are seen in---->Uterus in pregnancy

- ✓ The center for vomiting is located in---->Medulla
- drug commonly distributed in the ECF is---->Mannitol
- short muscles of hand are supplied by---->Ulnar nerve
- ✓ loss of flexion at elbow. Nerve damaged is ---->Musculocutaneous
- enzyme released in heart failure---->BNP
- in cubii fossa, nerve likely to damage----> Median nerve
- Hx of travel, complaints of chills, confusion & Labs show deranged RFTs, and decreased Hb, WBC, platelets. Cause---->Plasmodium Falciparum (best among options)
- Common symptoms of malaria includeshaking chills that can range from moderate to severe high fever.profuse sweating.headache.nausea abdominal pain.hemoglobin (decreased in 25% of patients, often profoundly in young children), platelet counts (thrombocytopenia in 50-68% of patients), and liver function (results abnormal in 50% of patients) In patients with suspected malaria, obtaining a history of recent or remote travel to an endemic area is critical
- Ovarian artery has increased chances of damage during exploratory laparotomy
- boy brought for circumcision bleeding profusely after circumcision. Best lab test----> Increased APTT



- ✓ Now you can join us Online for MD/MS & Fcps Preparation
- ✓ Complete course in 2months including Past paper discussion
- ✓ Join from anywhere using mobile/laptop using internet
- ✓ 100% feasible with job and 100% time adjustment for students
- ✓ www.fcpsworld.com or Contact 03129684658
- ✓ Hostel Facility is also available (for those who want to join physical classes)

Www.Fcpsworld.com (Institute for Fcps & Md/Ms)

www.facebook.com/FcpsWorld

www.facebook.com/GynaeObsWorld

www.facebook.com/Ophtworld

FILE IS ONLY FOR CLASS STUDENTS (DO NOT SHARE)



- ✓ A 5-year child presents with repeated episodes of epistaxis Blood show Hb 11, platelet normal. BT more than 24mins, APTT 26s. Cause---->VWD
- bleeding time indicates platelets defect

- cause of congenital cyanotic heart disease----> Tetralogy of fallot
- ✓ tumor marker of ovarian tumor is----> CA 125
- ✓ Calcitonin is released in malignancy of ---->Thyroid
- ✓ Indirect action of parathyroid hormone is----> Intestinal Ca absorption
- After hormonal/chemo therapy, the tumor size regresses by ---->Apoptosis
- The medial wall of ischiorectal fossa is formed by----> External anal sphincter
- fracture of pelvic bone in RTA... cause of shock is----> Excessive blood loss
- ✓ diagnosed with DM. on his 1st visit to his physician, drug should he be started----> Biguanides and sulfonylureas
- ✓ In 2nd trimester haematopoiesis in fetus occurs in---->Liver
- ✓ Anemia of pregnancy is due to---->Increase plasma volume
- ✓ Sodium is actively absorbed from----> Colon
- ✓ test is required to decide dialysis or transplant---->Creatinine clearance
- ✓ Type of Hypersensitivity in Hashimoto's thyroiditis is---->Type 4

- dyspnea on lying down, the structure likely to cause this dyspnea is---->Retrosternal goiter
- Raised T3 and T4 and decrease TSH occur in---->Primary hyperthyroidism
- Cause of meningitis in neonates <28 days----> Streptococcus agalactiae (Group B Strep)

- ✓ commonest hospital-acquired organism causing infection is----> Staph Aureus
- ✓ Organism which produces fluorescent pigments---->Pseudomonas
- Post-op wound causes greenish pus discharge. organism ---->Pseudomonas
- ✓ derived from 3rd pharyngeal arch----> Stylopharyngeus
- resting tremors and expressionless face---->Substantia nigra
- The primary oocytes complete their first meiotic division---->Before ovulation
- ✓ sign of irreversible cell injury in cardiac cell----> Contraction bands in cytoplasm
- ✓ Left coronary artery---->Gives LCX that runs in Anterior interventricular groove
- Left gastric vein drain directly into the---->portal vein



- ✓ Now you can join us Online for MD/MS & Fcps Preparation
- ✓ Complete course in 2months including Past paper discussion
- ✓ Join from anywhere using mobile/laptop using internet
- ✓ 100% feasible with job and 100% time adjustment for students
- ✓ www.fcpsworld.com or Contact 03129684658
- ✓ Hostel Facility is also available (for those who want to join physical classes)



Www.Fcpsworld.com (Institute for Fcps & Md/Ms)

www.facebook.com/FcpsWorld

www.facebook.com/GynaeObsWorld

www.facebook.com/Ophtworld

FILE IS ONLY FOR CLASS STUDENTS (DO NOT SHARE)

- The left gastric vein runs to the left along the lesser curvature, receiving the esophageal veins below the esophageal hiatus in the diaphragm. It usually drains directly into the portal vein at the superior border of the pancreas
- RCA after giving Rt marginal artery, supplies---->AV node
- Karyotype of a True hermaphrodite is---->46 XX/XY
About 60% of true hermaphrodites have a 46,XX karyotype, and the remainder are characterized by various forms of mosaicism, 46,XX/46,XY. ... The diagnosis of true hermaphroditism should be considered in any patient typically combining ambiguous genitalia, one or no palpable gonad, and 46,XX karyotype.

a part of portal venous system---->Superior rectal vein

- tumor of head of pancreas will compress----> CBD
- ✓ Blood supply to the upper 1/3 of the esophagus is from----> Inferior thyroid artery

Ovarian cancer first metastasizes to---->

- the CSF specific gravity---->1.005 to 1.009
- ✓ Iliolumbar artery is branch---->Internal iliac

Left shift of the oxygen dissociation curve occurs in---->

- ✓ mutation associated with adenocarcinoma of colon is----> K-RAS

Pulmonary valve opens when the pressure in right ventricle exceeds---->8mmHg

- right ventricular pressure of 8mmhg is required to open pulmonary valve

- ✓ boy is presented with chills and severe headache hepatosplenomegaly. organism was identified with Giemsa stain. organism is----> P. Falciparum

- ✓ Chronic Hypervitaminosis A leads to----> Hepatomegaly
- ✓ Epiploic appendages are present on---->Sigmoid colon
- in foot drop, nerves is most likely injured---->Common Peroneal
- ✓ bleeding from the left ear and the pupil of the left eye is dilated. cranial nerve is damaged---->Oculomotor
- gland shows many acini lined with pseudostratified columnar epithelium, embedded in stroma with smooth muscle. gland is ---->Prostate gland
- ✓ During hysterectomy, ureter can be damaged at ---->At pelvic brim
- The roof of anterior horn of lateral ventricle is formed by----> Body of corpus callosum



- ✓ Now you can join us Online for MD/MS & Fcps Preparation
- ✓ Complete course in 2months including Past paper discussion
- ✓ Join from anywhere using mobile/laptop using internet
- ✓ 100% feasible with job and 100% time adjustment for students
- ✓ www.fcpsworld.com or Contact 03129684658
- ✓ Hostel Facility is also available (for those who want to join physical classes)



Www.Fcpsworld.com (Institute for Fcps & Md/Ms)

www.facebook.com/FcpsWorld

www.facebook.com/GynaeObsWorld

www.facebook.com/Ophtworld

FILE IS ONLY FOR CLASS STUDENTS (DO NOT SHARE)

A 33wk pregnant woman presents with vaginal bleeding, low Hb, low Pit, increased bilirubin, AST normal, APTT & PT increased. the most likely dx----> DIC

- women of arterial disease has pulsatile mass in abdomen is noted. Site of origin is ----> T12-L2 (chose level <L4)
- The abdominal aorta is a continuation of the thoracic aorta beginning at the level of the T12 vertebrae. It is approximately 13cm long and ends at the level of the L4 vertebra. At this level, the aorta terminates by bifurcating into the right and left common iliac arteries that supply the lower body.
- a branch of internal iliac that remains in the true pelvis----> Middle rectal
- The GIT epithelium regenerates itself after how much time----> 2-7 days
- Most common acquired deficiency causing thrombosis is----> Antiphospholipid antibody syndrome
- ✓ test is performed in disease person and person is positive then the test is----> True positive
- FRC is sum of----> Expiratory reserve volume plus residual volume
- During difficult delivery, muscle likely to get paralyzed ----> Levator ani
- Side effect of Chlorpromazine----> Dystonia
- ✓ After trauma to mandible, lower teeth and chin sensation are lost Which nerve is compromised ----> Inferior alveolar nerve
- inferior alveolar nerve (IAN) is the third branch of the trigeminal nerve and it controls sensation of the lower teeth, lips, chin, and cheek
- ✓ Superior radioulnar joint is an example of ----> Pivot
- ✓ A shopkeeper suddenly collapsed with thin and thready pulse. O/E his BP was 80/40, cold clammy skin and gives Hx of sudden crushing chest pain before collapse. Diagnosis----> Massive Pulmonary Embolism
- Anterior 2/3rd of tongue fibres carrying taste sensations are----> Special Visceral Afferent
- ✓ Kaplan- Meier curve are used for----> Survival of patients
- HIV positive patient is complaining of headache neck stiffness and fungal meningitis is suspected. Organism----> Cryptococcus neoformans
- ✓ Nerve passing through petrous of temporal bone is----> Facial nerve
- ✓ Length of thoracic duct----> 45cm
- ✓ A Pt had a C-section complains of lumbar pain/anuria. Structure damaged----> Ureter



- ✓ Now you can join us Online for MD/MS & Fcps Preparation
- ✓ Complete course in 2 months including Past paper discussion
- ✓ Join from anywhere using mobile/laptop using internet
- ✓ 100% feasible with job and 100% time adjustment for students
- ✓ www.fcpsworld.com or Contact 03129684658
- ✓ Hostel Facility is also available (for those who want to join physical classes)



Www.Fcpsworld.com (Institute for Fcps & Md/Ms)

www.facebook.com/FcpsWorld

www.facebook.com/GynaeObsWorld

www.facebook.com/Ophtworld

FILE IS ONLY FOR CLASS STUDENTS (DO NOT SHARE)

- Axillary nerve is most commonly damage in----> Shoulder joint dislocation
- ✓ A 30 years man came to the outpatient department because he had suddenly developed double vision. O/E it was found that his right eye, when at rest, was turned medially. The most likely anatomical structures involved are----> Lateral rectus and Abducent nerve
- jejunum is distinguished from ileum on basis of---->More arterial arcade in mesentery
- ✓ pt of weight loss, palpitations with normal urea, Hyponatremia, hyperkalemia. Diagnosis----> Addisons disease
- ✓ drug causes fetal kidney damage in utero----> Captopril
- Secondary bone ossification centre in adult ---->Epiphysis
- ✓ Alleles are---->Non identical genes at same locus
- presented with jaundice and generalized itching. Direct Bilirubin 13 mg, SGPT 73U/L, Alkaline Phosphate 3400 IU/L 400IU/L. The most likely cause is ----> Extra hepatic Cholestasis
- ✓ During reperfusion, free radicals are released by----> Neutrophils
- indication for passive immunity---->A patient with acquired immune deficiency
- muscle extending from femur having role in stability of knee joint----> Vastus lateralis
- ✓ ECG reveals S1, Q3, T3 pattern. Next investigation----> Gallium scan
- Increased intake of protein is accompanied by increased intake of----> Riboflavin
- Neurovascular bundle is present in chest wall between----> Internal and innermost layer
- ✓ Hemiballismus result when damage occurs to which area of the brain---->subthalamic nucleus
- Pt works in demolition of old buildings, has pulmonary disease due to---->Asbestosis
- Gall bladder pain is referred to tip of shoulder via---->phrenic nerve

Pain arising from structures supplied by the phrenic nerve is often "referred" to other somatic regions served by spinal nerves C3-C5. For example, a subphrenic abscess beneath the right diaphragm might cause a patient to feel pain in the right shoulder. Source wikipedia

- Nerve supply of rectus abdominis is----> Subcostal only
- ✓ In Anterior inferior iliac spine fracture, pelvic avulsion is done ----> Rectus femoris
- Therapeutic dose of drug is decided on----> Potency
- ✓ Epidural Hemorrhage is due to ---->Middle meningeal artery
- ✓ Pt with severe haemorrhage have---->Tachycardia, hypotension, low CVP



- ✓ Now you can join us Online for MD/MS & Fcps Preparation
- ✓ Complete course in 2months including Past paper discussion
- ✓ Join from anywhere using mobile/laptop using internet
- ✓ 100% feasible with job and 100% time adjustment for students
- ✓ www.fcpsworld.com or Contact 03129684658
- ✓ Hostel Facility is also available (for those who want to join physical classes)



Www.Fcpsworld.com (Institute for Fcps & Md/Ms)

www.facebook.com/FcpsWorld

www.facebook.com/GynaeObsWorld

www.facebook.com/Ophtworld

FILE IS ONLY FOR CLASS STUDENTS (DO NOT SHARE)

- ✓ Reverse T3 present in age of---->fetus
- ✓ ECG shows prolonged PR interval with no missed beats. Diagnosis----> First degree heart block
- First-degree atrioventricular (AV) block, or first-degree heart block, is defined as prolongation of the PR interval on an electrocardiogram (ECG) to more than 200 msec. ...

- Right testicular vein drain into---->IVC
- The femoral sheath of the femoral vessels is formed by the ----> Fascia transversalis and the fascia iliaca
- Nerve stimulation is more difficult to create action potential in----> Hypokalemia
- ✓ participate in circle of Willis----> Posterior communicating artery
- ✓ Injury to sacral segments of spinal cord cause----> Autonomous bladder causing continuous dribbling
- Nerve conducting one sensation modality at a time is----> Labelled Line Principle
- ligament that has both intra as well as extra pelvic extension---->Round ligament of uterus
- ✓ Regarding S1---->Longer than S2
- complicated diabetic pts have ----> Angiopathy and neuropathy
- ✓ immediate effect of Insulin---->Potassium entry into the cell
- M bands cells are produced by----> Plasma cells
- ✓ In obstructive jaundice, there is increased clotting time due to----> Prothrombin deficiency
- ✓ A boy inhaled peanut, lodged in---->Rt lower bronchus
- In Chronic pancreatitis, steatorrhea occurs due to deficiency in ---->Lipase
- Is not a tumor suppressor gene---->BCL2
- Alcohol detoxification is done by ---->Peroxisome
- Number of umbilical arteries in fetus ---->2
- common cause of congenital hypothyroidism ----> Maternal iodide deficiency
- ✓ A child is born with cataract, mother is infected by----> Rubella

- ✓ Loss of inversion of foot. Muscle paralyzed---->Tibialis anterior and Tibialis posterior
- A boy with right testes in scrotum and left undescended. ---->Neoplasia
- ✓ increase the potency of local anaesthesia ---->120000 epinephrine
- ✓ analgesic with bronchodilator effect ---->Ketamine



- ✓ Now you can join us Online for MD/MS & Fcps Preparation
- ✓ Complete course in 2months including Past paper discussion
- ✓ Join from anywhere using mobile/laptop using internet
- ✓ 100% feasible with job and 100% time adjustment for students
- ✓ www.fcpsworld.com or Contact 03129684658
- ✓ Hostel Facility is also available (for those who want to join physical classes)



Www.Fcpsworld.com (Institute for Fcps & Md/Ms)

www.facebook.com/FcpsWorld

www.facebook.com/GynaeObsWorld

www.facebook.com/Ophtworld

FILE IS ONLY FOR CLASS STUDENTS (DO NOT SHARE)

Ketamine acts as a bronchodilator probably by two different mechanisms – firstly, via a central effect inducing catecholamine release, thereby stimulating β_2 adrenergic receptors, resulting in bronchodilation, and secondly, via inhibition of vagal pathways to produce an anticholinergic effect acting directly on bronchial smooth muscle

- formed from ventral and dorsal primordium ----> Pancreas
- cells involved in acute inflammatory process and also has myeloperoxidases and other enzymes----> Neutrophils & Monocytes
- A 3 years old baby inhaled something CXR confirmed foreign body lodged in left lower bronchus. diagnosis----> Situs inverses
- Regarding Cauda equina----> Anterior and posterior roots of spinal cord from L1-L5
- ✓ The most common feature of Pulmonary embolism----> Clinically silent
- ✓ Huntington Disease in mother, father is normal. Pattern of disease transmission to children is----> autosomal dominant pattern
- ✓ Neurons present in the sensory nerve body of spinal ganglia----> Pseudo unipolar
- ✓ A Child having Meckels diverticulum presents with bleeding per rectum. This is most likely due to----> Ectopic gastric tissue
- Complications arising from Meckels diverticulum include gastrointestinal bleeding, intussusception, intestinal obstruction, abdominal pain, and incarcerated hernia . The main cause of bleeding is the acid secreted from the ectopic mucosa, leading to ulceration of the adjacent ileal mucosa.
- ✓ professionalism of a doctor----> Polite and good bedside manners
- ✓ An accessory cervical rib arising from transverse process of cervical vertebrae may cause damage to----> T1
- in caput medusae. veins are involved----> Paraumbilical and epigastric veins
- Most common lobe involved in prostate carcinoma is----> Posterior
- ✓ Upper outer quadrant breast tumor lymph will drain into----> Pectoral
- ✓ Platelets are transfused at room temperature----> To optimize their function
- During cell division, the chromosome is arranged at the equatorial plate in----> Metaphase
- ✓ Accessory right hepatic artery arises from----> Superior mesenteric artery
- pt with dysphagia to liquid, biopsy reveal normal histology. Cause is----> Neuromuscular incoordination
- CSF differ from plasma in----> Dec pH
- pairing of reflex ----> Biceps - C5, C6



- ✓ Now you can join us Online for MD/MS & Fcps Preparation
- ✓ Complete course in 2 months including Past paper discussion
- ✓ Join from anywhere using mobile/laptop using internet
- ✓ 100% feasible with job and 100% time adjustment for students
- ✓ www.fcpsworld.com or Contact 03129684658
- ✓ Hostel Facility is also available (for those who want to join physical classes)



Www.Fcpsworld.com (Institute for Fcps & Md/Ms)

www.facebook.com/FcpsWorld

www.facebook.com/GynaeObsWorld

www.facebook.com/Ophtworld

FILE IS ONLY FOR CLASS STUDENTS (DO NOT SHARE)

- Function of Geniohyoid is---->Elevate hyoid or depress mandible
- ✓ artery behind sternum ---->ascending aorta>Int. thoracic artery
- vertebra in newborn---->C shaped vertebral column
- An old patient after abdominal surgery develops abdominal distention. O/E he was pale and BP low and tachycardiac. Most likely cause of shock is---->Hypovolemic shock
- The first changes in vital signs seen in hypovolemic shock include an increase in diastolic blood pressure with narrowed pulse pressure. As volume status continues to decrease, systolic blood pressure drops resulting into tachycardia

unable to extend the thumb and metacarpopharyngeal joints as well as the abduction of thumb. There was no loss of sensations. Nerve involved is----> Radial nerve

- ✓ Coarctation of aorta is ---->Constriction just after subclavian artery
- After renal transplant, patient presents with renal failure. the likely cause ---->Acute cellular rejection
- ✓ tympanic membrane---->Forms the lateral part of tympanic cavity
- bloody nipple discharge without any palpable mass. the most probable diagnosis----> Intraductal papilloma
- ✓ Pigment and neuronal layer of retina are kept in approximation by----> Glycosaminoglycan
- ✓ Glomerular artery form by---->Afferent arteriole
- Pain through free nerve ends is transmit by---->Spinothalamic tract
- Soldier with torrential diarrhea, donut shaped microorganism in stool . Diagnosis---->Cryptosporidiosis
- Superficial fascia is made up of---->Loose areolar tissue and adipose tissue
- Nerve likely to be injured during Submandibular gland surgery is---->Marginal branch of facial nerve
- The Right ovarian vein drain into ---->Inferior vena cava
- The most dangerous area of scalp is---->Loose areolar tissue
- A female taking estrogen therapy will likely have increased risk of---->Thromboembolisms
- Regarding Drug receptors---->Protein in nature
- Epiploic appendages are present on---->Sigmoid colon
- Thiamine deficiency is associated with---->Peripheral neuropathy
- Cremasteric reflex is supplied by---->Genital branch of genitofemoral



- ✓ Now you can join us Online for MD/MS & Fcps Preparation
- ✓ Complete course in 2months including Past paper discussion
- ✓ Join from anywhere using mobile/laptop using internet
- ✓ 100% feasible with job and 100% time adjustment for students
- ✓ www.fcpsworld.com or Contact 03129684658
- ✓ Hostel Facility is also available (for those who want to join physical classes)



Www.Fcpsworld.com (Institute for Fcps & Md/Ms)

www.facebook.com/FcpsWorld

www.facebook.com/GynaeObsWorld

www.facebook.com/Ophtworld

FILE IS ONLY FOR CLASS STUDENTS (DO NOT SHARE)

- Fall from bike. X-RAY reveals fracture of head of fibula. foot drop. nerves likely injured---->Deep Peroneal Common Peroneal
- First line of defense against tumor cells is ---->NK cells
- sexually transmitted ---->HepB
- Which amongst the following is the most aggressive carcinoma ---->Melanoma
- jaundice and generalized itching.Direct Bilirubin 11 mg/100 ml, SGPT 75U/L, Alkaline Phosphate 2300 IU/L 500IU/L. The most likely cause is---->Extra hepatic Cholestasis
- Fractured Medial Side of clavicle and right Sternoclavicular Joint pressed posteriorly. Damage to ---->Trachea
- An obese pregnant lady present jaundice. USG shows bile duct obstruction. Diagnostic investigation will be----> ERCP
- unable to open jaw because of tetanus resulting from a wound from a rusty nail. muscles likely paralyzed ---->Lateral pterygoid muscle
- The following part of the brachial plexus has branches that supply the extensor muscles of the arm---->Posterior cord
- Right supra renal vein drains into---->IVC
- Right testicular vein drain into---->IVC
- RTA with right leg injury. O/E swollen, warm and crepitus positive, foul smelling discharge, hypotensive and feels chills. reason---->Toxic shock
- After abdominal surgery, pt goes in hypotension, tachycardia, abdominal distention and has cold and clammy peripheries. Diagnosis---->Hypovolemic shock
- Bicarbonate absorption is through---->PCT and Collecting ducts
- Anti-HCV positive on investigation, while donating blood no Hx of jaundice no signs and symptoms and normal LFT. best approach---->Repeat Anti-HCV
- The site of production of aldosterone in the body is ---->Zona glomerulosa
- Cause of edema in child with periorbital edema and proteinuria more than 3.5gm is--->Decreased colloid osmotic pressure
- Which pregnancy test is used to confirm in less than 10 days after the date of conception---->Serum beta HCG
- A known CRF patient develops pneumonia. Which antimicrobial should he be started on---->Ceftazidime
- A pt on ATT for 2 months now presented with moderately elevated ESR. the most likely cause---->Superimposed bacterial infection
- Female is on HRT.most common risk she is at developing---->Thromboembolism
- The circadian rhythm is regulated by nuclei---->Suprachiasmatic



- ✓ Now you can join us Online for MD/MS & Fcps Preparation
- ✓ Complete course in 2months including Past paper discussion
- ✓ Join from anywhere using mobile/laptop using internet
- ✓ 100% feasible with job and 100% time adjustment for students
- ✓ www.fcpsworld.com or Contact 03129684658
- ✓ Hostel Facility is also available (for those who want to join physical classes)



Www.Fcpsworld.com (Institute for Fcps & Md/Ms)

www.facebook.com/FcpsWorld

www.facebook.com/GynaeObsWorld

www.facebook.com/Ophtworld

FILE IS ONLY FOR CLASS STUDENTS (DO NOT SHARE)

- Bitemporal hemianopia indicates a lesion in---->Central part of the optic chiasma
- 6 weeks previously healthy baby,with jaundice and yellow stain in diaper. All the other labs were normal except it showed hyperbilirubinemia. Diagnosis---->Biliary atresia
- A 28-year male with history of jaundice and raised ALT. The liver histology shows councilman bodies. These are most likely to be process of---->Apoptosis
- Polycystic kidney disease in adult is---->Autosomal dominant
- Regarding late fetus, which is ~ appropriate---->Liver will be 5% of body weight
- Insulin secretion is increased due to ---->Beta blockers
- Sympathetic supply of vessels is by---->Beta 2 adrenergic
- Hematoma at forehead after fall from bed. Labs show Hb 4.5 and gives Hx that the elder sister are normal but his maternal uncle died of circumcision . For screening best test---->Coagulation profile
- Regarding S3---->Produced during rapid ventricular filling
- Regarding S1---->Longer than S2
- Preganglionic supply of supra-adrenal gland is by---->Greater thoracic splanchnic nerve
- Lung compliance increases in---->Old age
- Most common heart valve affected in diseases is---->Mitral
- In caput medusa, distended umbilical veins is connection between paraumbilical veins and ---->Small epigastric veins of anterior abdominal wall
- The femoral sheath of the femoral vessels is formed by the---->Fascia transversalis and the fascia iliaca
- A boy with swollen left knee and hx of excessive bleeding after circumcision- What test should be done to confirm diagnosis---->Factor 8 assay
- In paediatrics, narrowest site in the airway is---->Cricoid
- Insulin independent glucose uptake occurs in---->Hypothalamus
- In bronchoscopy, which part of bronchus will be seen first---->Right lower bronchus
- pathologic processes has most likely occurred in the brain---->
- Transfer of 1-carbon fragments requires---->Folate
- Most common method to detect any type of cancer in blood is---->Tumor marker
- Injury on lateral aspect of his right knee with fracture of neck of fibula. artery will be damaged---->Inferior genicular
- A fisherman develop ecchymosis and bleeding gums. Most likely it is due to deficiency of---->Vit A



- ✓ Now you can join us Online for MD/MS & Fcps Preparation
- ✓ Complete course in 2months including Past paper discussion
- ✓ Join from anywhere using mobile/laptop using internet
- ✓ 100% feasible with job and 100% time adjustment for students
- ✓ www.fcpsworld.com or Contact 03129684658
- ✓ Hostel Facility is also available (for those who want to join physical classes)



Www.Fcpsworld.com (Institute for Fcps & Md/Ms)

www.facebook.com/FcpsWorld

www.facebook.com/GynaeObsWorld

www.facebook.com/Ophtworld

FILE IS ONLY FOR CLASS STUDENTS (DO NOT SHARE)

loss of consciousness, no speech or movement of right arm and leg. Later, a head CT scan showed a large cystic area in the left parietal lobe. Which pathologic processes has occurred in the brain---->

- first visible gross evidence for the formation of an atheroma ---->Calcification
- a benign tumor---->Warthin
- Patent lumen of Allantois form---->Urachal cyst
- A normal healthy individual is---->Disease free
- How much venous drainage of the myocardium is drained by coronary sinus---->2/3 of heart
- Which hepatitis has the highest mortality rate---->Hep D
- easy fatigability, pallor, body aches. Hb 6.5, MCV 22, MCHC 26. cause---->Iron deficiency anemia
- . Which type of hepatitis is most likely prevalent in the pregnant women ---->Hep E
- 33wk pregnant woman with vaginal bleeding, low Hb, low Pit, increased bilirubin, AST normal, APTT & PT increased. dx---->DIC
- Visitor develops fever, chills, confusion and goes into coma.deranged RFTs, Hb low and low platelets. Cause is---->Plasmodium Falciparum
- Deep cut on the posterolateral aspect of the forearm just distal to the neck of radius. unable to extend the thumb and metacarpopharyngeal joints as well as the abduction of thumb. There was no loss of sensations. Nerve involved is---->Radial nerve
- Lymphatic drainage of skin of the scrotum is to---->Superficial inguinal nodes
- Virus associated cancer is---->T cell leukemia
- Physiological dead space is increased in---->Pulmonary hypotension
- Which molecule best help in transient adhesion---->Selectin
- Jaundice age 65,Hb 4.5, increase bilirubin, increase retie count 10%. Polychromasia and clumps.test to confirm diagnosis---->Coombs
- The mechanism by which the size decreases after chemo is ---->Apoptosis
- pan chewer presents with a mouth ulcer. The most likely diagnosis is---->Submucosal fibrosis
- values are the best indexes of the preload on the heart---->Left ventricular end diastolic volume
- The most prominent deficiency in Lacrimal secretion when compared to plasma is---->Amino acid
- SA node is the pacemaker of heart because---->High firing rate



- ✓ Now you can join us Online for MD/MS & Fcps Preparation
- ✓ Complete course in 2months including Past paper discussion
- ✓ Join from anywhere using mobile/laptop using internet
- ✓ 100% feasible with job and 100% time adjustment for students
- ✓ www.fcpsworld.com or Contact 03129684658
- ✓ Hostel Facility is also available (for those who want to join physical classes)

Www.Fcpsworld.com (Institute for Fcps & Md/Ms)

www.facebook.com/FcpsWorld

www.facebook.com/GynaeObsWorld

www.facebook.com/Ophtworld

FILE IS ONLY FOR CLASS STUDENTS (DO NOT SHARE)



- fracture of surgical neck of humerus, arm not raised above shoulder and sensory loss on lateral surface of arm. Which artery is damaged---->Posterior circumflex humeral artery
- Pt with acute chest pain, normal ECG and cardiac enzymes, tenderness on the 4th and 5th ribs. Diagnosis---->Costochondritis
- Characteristic lesion of cerebellar disease is---->Adiadochokinesia
- As a result of dehydration, hypotonic fluid is present in---->DCT
- 80% of oxygen saturation in fetus is present in---->Umbilical vein
- Regarding Articular cartilage---->On epiphysis of long bones in synovial joints
- Strongest layer of GIT is---->Submucosa
- chest pain from 4 hours radiating to left arm. ECG shows ST elevation. Which cardiac enzyme will be raised ----> trop I
- Large portion of anterior surface of heart is made up by---->Right ventricle
- Large portion of anterior surface of heart is made up by---->Right ventricle
- Growth hormone secretion increases during---->Exercise
- Hard blow to the neck of fibula resulting in fracture will most likely cause damage to which nerve----> common peroneal nerve
- automobile accident, fracture of left 10 & 11th ribs. Which of following organs is most likely to have been injured---->Spleen
- ICF differs from ECF in---->Increased K
- an extension from renal cortex in between pyramid---->Renal column
- Neuronal repolarization is due to---->K efflux
- diabetic pt sensory abnormalities of the left foot and ulcer of big toe. The pathogenesis ---->Angiopathy and neuropathy
- After decussation in medulla, the corticospinal tract continues as---->Pyramidal tract
- Chain smoker for 20 years presented with mild upper respiratory infection. Biopsy of alveoli, will show---->Increase glandular secretion
- After secretion of trypsinogen into the duodenum, the enzyme is converted into its active form, trypsin, by---->Enteropeptidase
- A multinodular radiolucency on a radiograph from the mandibular molar area is pathognomonic for ----> Ameloblastoma
- Histological feature of TB granuloma is ---->Caseous necrosis
- attaches the liver to the anterior abdominal wall ---->Falciform ligament
- Internal oblique muscle aponeurosis form ---->Conjoint tendon
- Factor 8 is produced by---->Endothelial cells



- ✓ Now you can join us Online for MD/MS & Fcps Preparation
- ✓ Complete course in 2months including Past paper discussion
- ✓ Join from anywhere using mobile/laptop using internet
- ✓ 100% feasible with job and 100% time adjustment for students
- ✓ www.fcpsworld.com or Contact 03129684658
- ✓ Hostel Facility is also available (for those who want to join physical classes)

Www.Fcpsworld.com (Institute for Fcps & Md/Ms)

www.facebook.com/FcpsWorld

www.facebook.com/GynaeObsWorld

www.facebook.com/Ophtworld

FILE IS ONLY FOR CLASS STUDENTS (DO NOT SHARE)



- In Diabetes Insipidus, there is change in ---->Decrease urine osmolarity
- First line of defense against microbes is ---->Skin
- weight loss with enlarged supraclavicular lymph nodes.3cm radio opaque shadow bilaterally on Xray. Diagnosis---->Metastasis carcinoma
- fibers connect midbrain to the cerebellum ---->Superior cerebellar peduncle
- On X-ray, right border of heart is made by ---->SVC
- Tunica vaginalis is remnant of ---->Processes vaginalis
- cervical lymphadenopathy. granulomata on histology . For definite diagnosis of TB -- -->Demonstration of AFB
- A diagnosed case of Oat Cell Ca in lung presented with facial swelling, pedal edema, hyperpigmentation and hypertension. Cause is ---->ACTH
- In Granulopoiesis, the first cell to appear having granules is---->Promyelocyte
- H3.Which hormone inhibit the action of gastric acid secretion---->Secretin
- H4.Linea aspera of femur joins upward and medially to---->Intertrochanteric line
- lis.Type of collagen in Periodontal ligament---->Type 1
- abscess after tooth extraction in diabetic . The characteristic feature of actinomycetes is---->Granuloma with abscess
- Difference between Cortisol and GH is---->Increased during stress surgery
- Typhoid is diagnosed in 1st week by test ---->Blood culture
- In Fanconi syndrome, decrease ATP at the PCT is linked with---->Glycosuria
- Sparing of the lateral part of the thenar eminence with conspicuous wasting of other small muscles of the hand suggests a lesion of---->Ulnar
- 12 weeks amenorrhea, increased frequency and burning of micturition along with high grade fever. Diagnosis is---->UTI
- 2yrs child with fever, diarrhea for 2 days and pallor. Labs showHb is 5.6, MCV107, MCHC Inc. Investigation of choice is---->Serum B12 assay
- In which organ blood is regulated early by sympathetic system and then by local metabolites---->Skin
- hypoglycemic drug intake, a 50 yr male complains of metallic taste in mouth and diarrhea. drug prescribed---->Metformin
- test is done to diagnose hemophilia ---->Factor 8 assay
- Histopathological feature of malignancy is ---->Pleomorphism
- The primary oocytes complete their first meiotic division ---->Before ovulation
- Levels of Ca and Phosphate are mainly regulated by ---->PTH



- ✓ Now you can join us Online for MD/MS & Fcps Preparation
- ✓ Complete course in 2months including Past paper discussion
- ✓ Join from anywhere using mobile/laptop using internet
- ✓ 100% feasible with job and 100% time adjustment for students
- ✓ www.fcpsworld.com or Contact 03129684658
- ✓ Hostel Facility is also available (for those who want to join physical classes)

Www.Fcpsworld.com (Institute for Fcps & Md/Ms)

www.facebook.com/FcpsWorld

www.facebook.com/GynaeObsWorld

www.facebook.com/Ophtworld

FILE IS ONLY FOR CLASS STUDENTS (DO NOT SHARE)



- Congenital diaphragmatic hernia is due to---->Incomplete pleuroperitoneal membrane
- Pudendal nerve block is given in ---->Ischial spine
- Toxoplasmosis is a---->Parasite
- A child suddenly died while playing. On autopsy, coronary artery aneurysm was seen. Diagnosis is ---->Kawasaki disease
- rigors and chills, hypotension, loss consciousness and died after transfusion. Cause --->ABO incompatibility
- endocrinal disorder pt has Na 150, K 3.0, pH 7.46. It hormone ---->Aldosterone
- Lymph from medial side of breast drains into ---->Internal thoracic node
- Lesion of pyramid at medulla causes loss of ---->Motor function
- Platelet aggregation is caused by ---->Thromboxane A2
- 46XX with ambiguous genitalia. Diagnosis ---->Congenital adrenal hyperplasia
- occurs in severe diarrhea ---->Hyponatremia
- Primary dehydration change in ECF is ---->Hypertonic
- The most probable cause of edema in liver cirrhosis is due to deficiency of---->Albumin
- A pt presented with a knife injury to C5 and C6. Most likely muscle damaged will be--->Infraspinatus
- The roof of anterior horn of lateral ventricle is formed by---->Body of corpus callosum
- Characteristics sign of penicillin allergy is---->Bronchospasm
- A child died of severe pneumonia. At autopsy, the lung showed Warthin-fikelandenberg cell with many nuclei. Causative organism is---->Measles virus
- An asthmatic female had her hysterectomy done. Which post-op analgesic is preferred for her---->Paracetamol
- A 80-year-old smoker with weight loss presents with dysphagia to solid. Mechanism of dysphagia is---->Decrease peristalsis
- In Statistics, the term universe is synonymous with ---->Population
- The major blood supply of interventricular septum is by ---->Anterior interventricular artery
- Most appropriate regarding antibody produced by tuberculous tubercle is---->Cell bound
- In Hirsch sprung disease, there is complete absence of ganglion cells, these ganglia receive fibres from which segment of spine---->S2S3S4
- Prominent function of metastasis is---->Invasion of basement membrane



- ✓ Now you can join us Online for MD/MS & Fcps Preparation
- ✓ Complete course in 2months including Past paper discussion
- ✓ Join from anywhere using mobile/laptop using internet
- ✓ 100% feasible with job and 100% time adjustment for students
- ✓ www.fcpsworld.com or Contact 03129684658
- ✓ Hostel Facility is also available (for those who want to join physical classes)



Www.Fcpsworld.com (Institute for Fcps & Md/Ms)

www.facebook.com/FcpsWorld

www.facebook.com/GynaeObsWorld

www.facebook.com/Ophtworld

FILE IS ONLY FOR CLASS STUDENTS (DO NOT SHARE)

- Most common mode of genetic diseases inheritance is---->Multifactorial
- Regarding Genital branch of genitofemoral nerve---->Passes through deep inguinal ring
- The mechanism of increase heart rate is---->Decrease firing from baroreceptors
- Pyruvate generated by glycolysis must enter the mitochondria to be oxidized---->
- Therapeutic and toxic side effect of Loop diuretics is---->Low blood volume
- PT normal 14, increase BT 6 min, increase APTT 60, normal platelet count and bleeding history. Diagnosis---->Intrinsic pathway
- Organism which produces fluorescent pigments and is resistant to Q-iactam antibiotics---->Pseudomonas
- Tall QRS complex in lead II on ECG shows ---->Hypertrophied ventricle
- The four pillar of Medical Ethics---->Autonomy, Beneficence, justice and non-maleficence
- important regarding dead space---->Conditioning of inhaled air
- Factor related to MAC (Monitored Anesthesia Care) anaesthesia---->Coefficient of gas blood
- A pt with No motor or sensory loss, no reflex change. Lesion in---->Rubrospinal tract
- Regarding Pacinian corpuscles---->Rapidly adapting pressure receptor
- Inspiratory ramp signals are produced from dorsal respiratory neurons, their rate increases in response to impulses from---->Pneumotoxic center
- Joint present between vertebrae is---->symphysis
- Bronchial asthma affects---->medium size bronchioles
- Median episiotomy risk of---->external anal sphincter damage
- Spinal cord is suspended into dura matter by---->denticulate ligament
- >70years diabetic. Treatment for diabetes---->tolbutamide
- Plastic factory worker risk of---->urinary bladder ca
- Diabetic with rbs 600 mg/dl. Result in ---->increase urine volume
- Regarding warmth receptors---->long receptive field
- Boy with bleeding of 1.5l. Skin is cold and clammy. The initial response is---->vasoconstriction
- During oophorectomy, ureter is damaged at ---->pelvic brim
- Fracture of neck of fibula. nerve damage ---->femoral
- Boy used to eat mud, passed a 8- inch-long worm through his nose. Organism ---->ascaris
- Raynauds phenomena seen in ---->peripheral vascular disease



- ✓ Now you can join us Online for MD/MS & Fcps Preparation
- ✓ Complete course in 2months including Past paper discussion
- ✓ Join from anywhere using mobile/laptop using internet
- ✓ 100% feasible with job and 100% time adjustment for students
- ✓ www.fcpsworld.com or Contact 03129684658
- ✓ Hostel Facility is also available (for those who want to join physical classes)



Www.Fcpsworld.com (Institute for Fcps & Md/Ms)

www.facebook.com/FcpsWorld

www.facebook.com/GynaeObsWorld

www.facebook.com/Ophtworld

FILE IS ONLY FOR CLASS STUDENTS (DO NOT SHARE)

- Sudden withdrawal of glucocorticoid is not done due to---->adrenal cortical suppression
- Lateral forearm injury after which he is unable to extend and abduct thumb but the sensations are intact lesion in ----> radial nerve
- Boy had a fall on outstretched hand. He can't abduct till 30 degrees after which abduction is smooth. Lesion is in---->supraspinatus
- Apoptosis occurs---->activation of caspases
- Cranial nerves arise from the pons ---->cn 5,6,7,8
- Medial plantar arch of foot is maintained by---->plantar calcaneonavicular
- Best example of psychological stress is ---->economic viability
- Most important criteria for diagnosis of malignancy ---->metastasis
- Virus cause cancer by---->proto oncogene
- Barium meal, feather shaped on left side of abdomen.---->jejunum
- Vit a given to children of a certain population. This type of prevention is known as ---->specific protection
- Most common primary bone tumor in 20s is---->osteosarcoma
- Cells have telomerase activity ---->germ cells
- In cardiac failure, edema is due to---->increased hydrostatic pressure
- Skeletal and smooth muscle found in ---->middle 1/3 esophagus
- First line of defense in lungs is by----> alveolar macrophages
- Papillary tumor risk factor---->radiation in childhood
- Test of intravascular hemolysis is ---->decreased haptoglobin
- In surfactant deficiency, what happens ---->decrease lung compliance
- Buffer in renal tubules is---->phosphate
- a nerve is injured in neck region and there is weakness in raising arm above the head. The nerve injured is---->long thoracic nerve
- Parasympathetic system causes ---->salivation
- Nsaid safe in lactating mother---->ibuprofen
- In myocardial infarction, type of shock is seen ---->cardiogenic shock
- Costodiaphragmatic recess lies ---->costal and diaphragmatic part of parietal pleura
- Supplied by muscarinic cholinergic via post ganglionic sympathetic fibers ---->sweat glands
- Regarding mode, which is true---->it is the most repeated value
- Most common inherited bleeding disorder ---->von willebrand
- Cells responsible for innate immunity are activated most commonly by---->carbohydrate sequences in bacterial cell walls



- ✓ Now you can join us Online for MD/MS & Fcps Preparation
- ✓ Complete course in 2 months including Past paper discussion
- ✓ Join from anywhere using mobile/laptop using internet
- ✓ 100% feasible with job and 100% time adjustment for students
- ✓ www.fcpsworld.com or Contact 03129684658
- ✓ Hostel Facility is also available (for those who want to join physical classes)



Www.Fcpsworld.com (Institute for Fcps & Md/Ms)

www.facebook.com/FcpsWorld

www.facebook.com/GynaeObsWorld

www.facebook.com/Ophtworld

FILE IS ONLY FOR CLASS STUDENTS (DO NOT SHARE)

- Girl has a nodule upper chest for many yrs and has not changed in size. Dark red non tender, raised nodule with smooth surface. diagnosis is----->hemangioma
- Progressive dysphagia only to solid food is characteristic of ----->esophageal
- During esophagectomy which artery is mobilized for the supply of stomach----->right gastroepiploic artery
- Type of neuron in spinal ganglia----->pseudo unipolar
- Embryonal tumor marker for hcc is ----->afp
- Portal vein ascends to liver with----->lesser omentum
- Sensation of lower teeth and chin ----->alveolar nerve mandibular nerve
- Child with bleeding, bt and aptt are abnormal, rest labs are normal. Cause----->von willebrand disease
- Pulse oximeter give error in----->methemoglobinemia
- Superior radioulnar joint is----->pivotal joint
- Maximum flow pressure in coronary vessel occurs at ----->beginning of diastole
- Staging depends on----->lymph vascular invasion
- Pr interval on ecg denotes----->av nodal delay
- Chest pain cause is ----->myocardium
- Malignant malaria is caused by---->plasmodium falciparum
- Conduction of one sensation modality in sensory nerve fibers at a time is called----->labeled line principle
- Chronic smoker develops a non-healing ulcer in mouth with bleed cause is----->scv
- Plateau in cardiac action potential is caused by ----->ca++
- Pre-op h2 blockers given to -----> decrease volume & acidity of gastric content
- Pinpoint pupil and ptosis. Diagnosis is----->horners syndrome
- Portal vein formed by union of superior mesenteric vein and splenic vein at----->behind neck of pancreas
- Barretts esophagus increases the risk ----->adenocarcinoma
- Epithelium modification in small intestine----->microvilli
- Tumor suppressor gene----->p53
- Relation of pituitary----->laterally to cavernous sinus
- Esophageal atresia characteristic first sign is----->regurgitation with first feed
- Necrosis in brain ischemia ----->liquefactive
- How to prevent infection in icu ----->excessive hand wash after patient examine
- Copd patient from 9 months with ph 7.37(normal) pco2 49, hco3 29. Diagnosis ----->compensated respiratory acidosis



- ✓ Now you can join us Online for MD/MS & Fcps Preparation
- ✓ Complete course in 2months including Past paper discussion
- ✓ Join from anywhere using mobile/laptop using internet
- ✓ 100% feasible with job and 100% time adjustment for students
- ✓ www.fcpsworld.com or Contact 03129684658
- ✓ Hostel Facility is also available (for those who want to join physical classes)



Www.Fcpsworld.com (Institute for Fcps & Md/Ms)

www.facebook.com/FcpsWorld

www.facebook.com/GynaeObsWorld

www.facebook.com/Ophtworld

FILE IS ONLY FOR CLASS STUDENTS (DO NOT SHARE)

- Brodie's abscess occurs in---->pyogenic osteomyelitis
- Old patient after abdominal surgery develops abdominal distention. Pale & bp low with tachycardia.---->hypovolemic shock
- Structure related anterior to hilum of rt kidney---->second part of duodenum
- Signs of food poisoning due to clostridium botulinum is---->flaccid paralysis of respiratory muscles
- Boy with severe conjunctivitis, edema of lips and oral mucosa and cervical lymphadenopathy and aneurysm. Diagnosis---->kawasaki
- Principal body defense cells against tumors---->nk cells
- Lower limit of subarachnoid space extension into---->coccygeal segment
- Alveolar ventilation---->(tidal volume - dead space) x breaths min
- Galactosemia is caused due to---->galactose 1 phosphate uridylyltransferase
- Capillary occlusion, low hb, dystrophic morphology. Cause---->sickle cell anemia
- Index to test renal functioning in esrd---->creatinine clearance
- Pth not affected by---->osteoporosis
- Conducting pathway of heart is present in ---->sub endocardium
- Vitamin A supplementation in children of certain age is a form---->specific protection
- Volume of air in lung after maximum inspiration---->inspiratory capacity
- Multiple myeloma question. Lytic lesions and backache. Investigation of choice is ---->immune electrophoresis
- Flickering movements ---->lesion in globe palidus
- Hyperflexion of neck. Ligament damaged is ---->ligamentum nuchae
- Unable to perform lateral movement of rt eye ---->cavernous sinus infection
- A laborer while working got his right thumb lacerated accidentally. His 1st web space is infected. Lymphatic drainage will be to---->infraclavicular nodes
- In 40% bum pt, low grade voltage action potential is due to---->hyponatremia
- Structure most affected by pus in adductor canal ---->femoral vein
- Ghon complex appears in---->tb
- Post surgery of uterine fibroid. Develops colicky, right lumbar pain and oliguria and difficulty in micturition within 24 hours of surgery. Structure is likely ligated---->ureter
- Artery injured in snuff box---->radial artery
- Feature of pe---->clinically silent
- Action of bicarbonate in salicylate poisoning ---->inc excretion through kidneys
- Scenario epigastric pain, taking antacids, diagnosed as gastric lymphoma. Cause is---->h pylori



- ✓ Now you can join us Online for MD/MS & Fcps Preparation
- ✓ Complete course in 2 months including Past paper discussion
- ✓ Join from anywhere using mobile/laptop using internet
- ✓ 100% feasible with job and 100% time adjustment for students
- ✓ www.fcpsworld.com or Contact 03129684658
- ✓ Hostel Facility is also available (for those who want to join physical classes)



Www.Fcpsworld.com (Institute for Fcps & Md/Ms)

www.facebook.com/FcpsWorld

www.facebook.com/GynaeObsWorld

www.facebook.com/Ophtworld

FILE IS ONLY FOR CLASS STUDENTS (DO NOT SHARE)

- Fall while cycling, presented to er 3 days later with complaints of anuria. Lesion is in----->urethra
- Ige receptors are present on----->mast cell
- Neck of humerus fracture, loss of abduction and proximal upper arm lateral side sensation.----->axillary nerve damage
- Extreme left shift of oxygen dissociation curve occurs in----->co poisoning
- Terminal ileum of small bowel was removed due to malignancy. Most common complication will be----->increase in water content of feces
- New born is diagnosed to have inclusion conjunctivitis because the mother had a vaginal infection. Possible cause is----->chlamydia
- At cubital fossa which nerve is most likely to be injured during blood sampling----->median nerve
- Study on smoking as risk factor for development of lung cancer. 500 smokers with disease and 500 healthy matched nonsmokers were evaluated.type of study is----->cohort
- A sexually active man with pain and burning micturition, no penile ulcers. On investigation gonorrhea negative, wbc 50. Cause of std is ----->chlamydia
- Blood group antigen-----> glycoproteins
- Question of athlete injury during running and develops acute leg pain. Next day his ankle is swollen and he can stand though it is painful. Most likely cause is ----->plantaris damage
- Myasthenia gravis treatment ----->anticholinesterase
- Helps in wound healing----->microfilaments
- Sprained ankle resulting from excessive eversion.structure is damaged----->deltoid ligament
- Blood transfusion. After which he started complaining of dark color urine. Cause is----->hemolytic reaction
- Hypovolemia. Isoflurane will not be given due to ----->it is a potent vasodilator
- Energy in excess of resting during contraction is called----->initial heat
- Site for Ip is----->above I5
- 11 days post thyroidectomy, patientpresents muscle spasm and paresthesia. Cause----->high po4, low ca and hypocalcemic tetany
- In pyogenic abscess, enzymes are released by----->neutrophils
- In metabolic acidosis, renal compensation done by ----->inc. Glutamine secretion



- ✓ Now you can join us Online for MD/MS & Fcps Preparation
- ✓ Complete course in 2months including Past paper discussion
- ✓ Join from anywhere using mobile/laptop using internet
- ✓ 100% feasible with job and 100% time adjustment for students
- ✓ www.fcpsworld.com or Contact 03129684658
- ✓ Hostel Facility is also available (for those who want to join physical classes)



Www.Fcpsworld.com (Institute for Fcps & Md/Ms)

www.facebook.com/FcpsWorld

www.facebook.com/GynaeObsWorld

www.facebook.com/Ophtworld

FILE IS ONLY FOR CLASS STUDENTS (DO NOT SHARE)

- Child with splenomegaly and family hx of anemia. peripheral smear showed mcv 60, mch 18, hb 5. Best test---->hb electrophoresis
- In chronic copd case, normal in arterial blood ---->h+ ion
- 10 minutes of transfusion develops heavy chest pain, dyspnea, becomes critical and dies on the 3rd day cause is---->abo incompatibility
- molecule best helps in transient adhesion of wbc to endothelium---->selectin d inhibin
- Muscle shortening in response to stretch is ---->predominantly flexors
- Regarding left coronary artery---->supplies bundle of his
- Abgs shows ph 7.27, pco2 60, hco3 26. Diagnosis ---->respiratory acidosis
- Prostate drains mainly into---->popliteal nodes
- Man in an intermediate host in---->hydatid disease
- Nasopharyngeal ca caused by---->ebv
- High grade fever and vomiting. O/e kerning sign +ve. Drug to given is---->penicillin g. (cephalosporin was not in option)
- Vit e deficiency causes---->hemolytic anemia
- Mammary gland ---->15 to 20 lactiferous ducts
- Function of baroreceptor in blood pressure is---->increase arterial pressure
- artery passes in the floor of sub occipital triangle ---->vertebral artery
- A woman develops dvt after laparotomy.---->stasis + hypercoagulable state
- Artery damage in snuff box ---->radial artery
- Right lung &---->azygous in direct relation
- Tumor marker for ovarian ca---->ca 125
- Right upper quadrant pain, leukocytosis, and eosinophilia. Diagnosis ---->amoebic abscess
- Loss sensory sensations on the lateral palmar surface of the hand and unable to flex index finger. Lesion is in ---->median nerve
- Blood loss for 30 mins, with no change in atrial pressure volume reduction will occur in which compartment---->
- During difficult delivery, which of the muscle is likely to get paralyzed ---->levator ani
- Moa of allopurinol---->xanthine oxidase inhibitor
- Lymphatic drainage of ca ant. 2/3rd of tongue---->submandibular lymph nodes
- Neurovascular bundle is located in ---->lower border of upper rib
- Dna virus causing atypical lymphocytes ---->infectious mononucleosis
- Blood supply of middle esophagus is by---->descending thoracic aorta
- Thick mucoid sputum jelly like---->klebsiellas



- ✓ Now you can join us Online for MD/MS & Fcps Preparation
- ✓ Complete course in 2months including Past paper discussion
- ✓ Join from anywhere using mobile/laptop using internet
- ✓ 100% feasible with job and 100% time adjustment for students
- ✓ www.fcpsworld.com or Contact 03129684658
- ✓ Hostel Facility is also available (for those who want to join physical classes)



Www.Fcpsworld.com (Institute for Fcps & Md/Ms)

www.facebook.com/FcpsWorld

www.facebook.com/GynaeObsWorld

www.facebook.com/Ophtworld

FILE IS ONLY FOR CLASS STUDENTS (DO NOT SHARE)

- Function of geniohyoid is---->elevate hyoid or depress mandible
- Left lobe of lower thyroid surgery, nerve likely to be damaged is ---->recurrent laryngeal
- Neuroectoderm derivative---->ciliary epithelium
- Nerve supply of masseter muscle is ---->mandibular branch of trigeminal
- Common cause of blindness worldwide is---->chlamydia
- Most common feature of autoimmune disease is ---->arthritis
- In brain major blood vessels are found is ---->subarachnoid space
- Posterior 1/3 of interventricular septum is supplied by---->rca
- Megaloblastic hypochromic picture and hyper segmented neutrophils.treatment ---->folate
- Protein digesting enzyme exapatent---->lysozyme
- Dicrotic notch is seen in---->aortic closure
- Organism ofrheumatic mitral stenosis after tooth extraction.---->strep viridans
- Post operative wound of foul smelling, dark colour exudate. Organism is---->bacteroides fragilis
- Child weighing 10kgs, height 169cm presented with bowing of legs. Cause is ---->deficiency of vit d
- Patient suffering from dysphagia, dysarthria, analgesia thermoanaesthesia on ipsilateral side of face and ipsilateral horner syndrome.---->posterior inferior cerebellar artery
- Cholangiocarcinoma caused by---->clonorchis sinensis
- Hemolytic anemia question, diagnosis by---->coombs test
- Loss of flexion at elbow and supination. Nerve damaged is---->musculocutaneous
- Numbness of medial arm and atrophy of small muscles of hand.---->cervical rib
- Patienthas pain in parotid region, which is aggravated by chewing. The nerve most likely involved---->auriculotemporal
- Soap bubble appearance on x-ray ---->giant cell tumour
- In iron deficiency, the anemia produced is ---->microcytic and hypochromic
- Most common site of fracture of rib is---->angle
- Moa of local anesthetic---->block na+ channel
- Platelet aggregation inhibited by---->prostacyclin
- Ectoderm and endoderm meet at caudal end forming---->cloacal membrane
- Neurovascular bundle in chest wall lies between---->internal and innermost layers
- Role of prostaglandin in git ---->decrease h+ secretion
- Organ utilizes 70- 80% of O2 of at rest ---->heart
- Neurotransmitter of outflow basal ganglia is---->gaba



- ✓ Now you can join us Online for MD/MS & Fcps Preparation
- ✓ Complete course in 2months including Past paper discussion
- ✓ Join from anywhere using mobile/laptop using internet
- ✓ 100% feasible with job and 100% time adjustment for students
- ✓ www.fcpsworld.com or Contact 03129684658
- ✓ Hostel Facility is also available (for those who want to join physical classes)



Www.Fcpsworld.com (Institute for Fcps & Md/Ms)

www.facebook.com/FcpsWorld

www.facebook.com/GynaeObsWorld

www.facebook.com/Ophtworld

FILE IS ONLY FOR CLASS STUDENTS (DO NOT SHARE)

- Nucleus ambiguous contains---->cn 9,10,11
- Long term complication of estrogen use---->endometrial ca
- Muscle is derived from 3rd pharyngeal arch---->stylopharyngeus
- Most abundant immunoglobulins in adults is ---->igg
- Nerve to be injured in submandibular surgery----> marginal mandibular branch of facial
- Metabolic alkalosis caused by---->crf
- Greenish foul smelling vaginal discharge. On microscopy motile trophozoites are seen.-->trichomonas vaginalis
- Chemotaxis is caused by---->c5a
- Third ventricle---->posteriorly related to subthalamus
- Increase in stroke volume with unchanged peripheral resistance and capacitance result in---->increase in pulse pressure
- Inc. V/q ratio in---->dead space
- Polychromasia in erythropoiesis is due to ---->hb ribosomes
- Lymphatic drainage of labia majora is---->superficial inguinal nodes
- During tracheostomy, risk of damage causing excessive bleed---->anterior jugular vein
- Dose of drug is decided on ---->potency
- Grafts between genetically identical twins---->are not rejected even without immunosuppression
- Post intervention infarction ---->small limited area of ventricular myocardium damaged
- Karyotype in turner syndrome ---->45 xo
- Cause of multiple fractures in adults/old ---->osteoporosis
- Researcher divided her patient in to 2 groups and 2 antibiotics namely amoxicillin and ciprofloxacin were selected for each group without letting anyone know the real name of drug except patient---->single blind study
- Ckd patient, drug should be avoided ---->gentamycin
- Splenic vessels are present in---->lienorenal ligament
- Vibrio cholera causes diarrhea is---->increase chloride secretion from secretory cells of intestine
- Fever and abdominal pain with raised mcv and low hb.diagnostic test ---->serum b12
- Muscle extending from femur having role in stability of knee joint---->vastus lateralis (quadricps)
- Injury in the posterior triangle of neck damages which structure ---->spinal part of accessory nerve
- Sq. Cell bladder carcinoma cause---->schistosoma hematobium



- ✓ Now you can join us Online for MD/MS & Fcps Preparation
- ✓ Complete course in 2months including Past paper discussion
- ✓ Join from anywhere using mobile/laptop using internet
- ✓ 100% feasible with job and 100% time adjustment for students
- ✓ www.fcpsworld.com or Contact 03129684658
- ✓ Hostel Facility is also available (for those who want to join physical classes)



Www.Fcpsworld.com (Institute for Fcps & Md/Ms)

www.facebook.com/FcpsWorld

www.facebook.com/GynaeObsWorld

www.facebook.com/Ophtworld

FILE IS ONLY FOR CLASS STUDENTS (DO NOT SHARE)

- Hyperemesis (features of alkalosis). Which abnormality will occur ----->hypokalemia
- Appendicitis pain mediated by----->bradykinin and prostaglandins
- In juxtamedullary site, solutes added by ----->counter current multiplier
- Hypertrophy and hyperplasia are seen in ----->uterus in pregnancy
- Frc is sum of----->expiratory reserve volume + residual volume
- Child with recurrent infection and eczematous rashes presents to you with bloody diarrhea and normal iga levels. Cause----->wiskott-aldrich syndrome
- Peripheral vasodilation and hypotension occurs in which of these----->hypovolemic shock
- Haploid number of chromosome with haploid dna present in ----->spermatids
- Patient cant move sole of foot medially. Which group of muscle are involved----->tibialis anterior and tibialis
- Cells have a single membrane bounded with lamellar vesicles and granules ----->mast cells
- Scnerio presented with inability to extend his metacarpopharyngeal joint of finger & cant abduct and extend the thumb but sensations are intact. Most likely injury to has occurred to----->radial nerve
- Oral anticoagulant is monitored ----->pt
- Early sign of reversible cell injury is----->er swelling
- Denatured protein is degraded by ----->proteasome
- Nerve passing through petrous of temporal bone is ----->facial nerve
- Aspirin toxicity should be treated with ----->bicarbonate
- Greatest blood flow per 100 grams to which organ----->kidney
- Characteristics microscopic feature of parietal cells of the stomach---àcopious eosinophilic cytoplasm and a central nucleus
- Damaged during superior thyroid artery ligation ----->external laryngeal
- Injury above sacral spinal segment causes----->neurogenic bladder
- Scnerio of pale, weakness with low mcv and eggs in stool. Diagnosis----->ancylostoma duodenale
- Old man with resting tremors. Lesion in ----->substantia nigra
- Baby dont cry in bottle milk but on breast milk.cause ----->cleft soft palate
- Cause of metabolic acidosis ----->diabetes
- In tmj dislocation, dislocated condyloid of mandible----->anteriorly to anterior tubercle
- In typhoid the bacteria resides in ----->payers patches
- Glucocorticoid does not decrease which cells----->neutrophil



- ✓ Now you can join us Online for MD/MS & Fcps Preparation
- ✓ Complete course in 2months including Past paper discussion
- ✓ Join from anywhere using mobile/laptop using internet
- ✓ 100% feasible with job and 100% time adjustment for students
- ✓ www.fcpsworld.com or Contact 03129684658
- ✓ Hostel Facility is also available (for those who want to join physical classes)



Www.Fcpsworld.com (Institute for Fcps & Md/Ms)

www.facebook.com/FcpsWorld

www.facebook.com/GynaeObsWorld

www.facebook.com/Ophtworld

FILE IS ONLY FOR CLASS STUDENTS (DO NOT SHARE)

- During submandibular gland surgery, the nerve most likely to get damaged during skin incision is---->marginal branch of facial nerve
- Common complication of estrogen therapy is---->thromboembolism
- Vertebra in newborn ---->c shaped
- Girl cant hear low frequency sounds. Type of deafness is---->sensorineural deafness
- Female with petechiae, easy bruising, no family history and causative factor. Diagnosis--->itp
- Complete depolarization of ventricles on ecg is shown on---->st segment
- After a blunt trauma to eye with lower orbit fracture. O/e crackling sound on palpation.->subcutaneous emphysema
- Pain in epigastrium due to gastric ulcer is carried by---->greater splanchnic nerves
- Sensation of rectal distention is carried by ---->parasympathetic
- Vertebrae are joined to the adjacent laminae by ---->ligamentum flavum
- Cell response to action potential is ---->high amplitude with high stimulus
- Washed rbc's are beneficial in---->prevent hypersensitivity
- In fanconi syndrome, decrease atp at pct linked with---->
- Appropriate test for hypothyroid ---->tsh
- Lymph flow decreased in---->hemorrhage
- Respiratory dna virus---->adeno
- Raw undercooked meat there is increased chance of ingesting eggs---->tapeworm
- Question of vit k defi & jaundicetest ---->prothrombin increase
- Most common squamous cell carcinoma ---->bowens disease
- Transfusion. After 20 mins develops dyspnea and fever. Reaction---->type 2
- Hemiballismus result when damage occurs to area of the brain---->subthalamic nucleus
- Lymphatic drainage of gians penis and corpora is---->deep inguinal
- Slow growing thyroid tumor ---->papillary
- Presented with bone pain and paraesthesia in lower limbs. Serum calcium 2.29 mmol/l (2.10 - 2.65); inorganic phosphate 0.91 mmol/l (0.8 -1.9); alkaline phosphatase 391 lu/ml (120 - 365) and serum pth level 5.5 mmol/l (1.5 - 6.0). Diagnosis---->pseudo hyperparathyroidism
- Investigation shows mcv increased, hyper segmented neutrophils on smear. Most likely diagnosis is---->pernicious anemia
- Huntington disease in mother and father is present.chances in offspring ---->0.5
- Lady with 3 children and normal reproductive cycle, has less chance of pregnancy as compared to 33 yr old female, reason is ---->inhibition of gnrh



- ✓ Now you can join us Online for MD/MS & Fcps Preparation
- ✓ Complete course in 2months including Past paper discussion
- ✓ Join from anywhere using mobile/laptop using internet
- ✓ 100% feasible with job and 100% time adjustment for students
- ✓ www.fcpsworld.com or Contact 03129684658
- ✓ Hostel Facility is also available (for those who want to join physical classes)



Www.Fcpsworld.com (Institute for Fcps & Md/Ms)

www.facebook.com/FcpsWorld

www.facebook.com/GynaeObsWorld

www.facebook.com/Ophtworld

FILE IS ONLY FOR CLASS STUDENTS (DO NOT SHARE)

- Corneal opacities side effect---->chloroquine
- High affinity for receptors ---->free tri-iodothyronine
- Phrenic nerve---->irritation causes pain to shoulder
- Rathkes pouch is derived from---->stomodeum
- Effect of thoracic vagotomy---->decreased acid secretion
- Structure immediately medial to femoral hernia is---->lacunar ligament
- Squamous epithelium in the lower end of cervix is ---->dysplasia
- Embryonic tumor in childhood---->ewing sarcoma
- In dehydration, water is mostly absorbed from ---->pct
- Nerve supply of platysma---->facial nerve
- In pregnancy, uterine fibroid results in---->red degeneration
- Rca damage, which part of heart will be affected ---->av node
- Occurs in defecation reflex---->relaxation of internal anal sphincter and contraction of ext. Sphincter
- Dic is caused by---->endotoxin shock
- Fracture of neck of femur occurred common delayed complication ---->avascular necrosis
- In inferior wall ml which artery is likely to be blocked---->right marginal
- A tumor in the infratemporal fossa invades the middle cranial fossa, bone involve---->greater wing of sphenoid
- Sle initial most sensitive test is ---->ana
- Ligamentum arteriosum joins---->left pulmonary artery to arch of aorta
- Superior mesenteric and inferior mesenteric artery anastomose on---->marginal
- Diagnosis of polyarteritis nodosa vasculitis---->fibrinoid necrosis in arterioles
- Side effect of chlorpromazine---->dystonia
- Bronchial asthma---->fev/fvc ration < 65 %
- Main support of uterus is by---->transverse cervical
- Ketamine will cause myocardial depression if the patient has taken---->propranolol
- Most common carcinoma of diaphysis is ---->ewing sarcoma
- Stain is specific for amyloid ---->congo red
- Superior rectal artery ist branch of ---->inferior mesenteric artery
- Patient wound sutured. Substance in new vessel formation ---->pdgf
- The undifferentiated germ cells found in the basal compartment of seminiferous tubules are called---->type a spermatogonia



- ✓ Now you can join us Online for MD/MS & Fcps Preparation
- ✓ Complete course in 2months including Past paper discussion
- ✓ Join from anywhere using mobile/laptop using internet
- ✓ 100% feasible with job and 100% time adjustment for students
- ✓ www.fcpsworld.com or Contact 03129684658
- ✓ Hostel Facility is also available (for those who want to join physical classes)



Www.Fcpsworld.com (Institute for Fcps & Md/Ms)

www.facebook.com/FcpsWorld

www.facebook.com/GynaeObsWorld

www.facebook.com/Ophtworld

FILE IS ONLY FOR CLASS STUDENTS (DO NOT SHARE)

- Primary center of ossification at epiphysis of long bone at birth is ---->lower end of femur
- Greenish discharge post op surgical wound. Organism is----->pseudomonas
- Patient comes to ER with complains of heart sinking. Ecg shows low t wave. ----->hypokalemia
- Amyloidosis mostly affect ----->kidney
- Ligamentum teres ----->left umbilical vein remnant
- Calories in 100g cereals----->350-400
- loss of ankle jerk nerve compressed is----->s1 nerve root
- Protein proton gradient is in ----->mitochondria
- Hb begin to appear in----->intermediate normoblast
- Loss of taste sensation----->superior salivary nucleus
- Ckd patient having mcv 86fl, mch normal with low hb . ----->normochromic normocytic
- Artery behind the sternum----->int. Thoracic artery
- Treatment of cryptococcus neoformans meningitis----->amphotericin b
- Adrenal medulla innervated by----->greater thoracic splanic
- Inpeanut most likely to be lodged in ----->rt lower bronchus
- Bone removed surgically is heal by----->periosteum
- Deviation of tongue on protrusion, lesion is in----->hypoglossal nucleus
- Scnerio of of low hb, mature looking lymphocytes wbc 65×10^9 and general lymphadenopathy. Diagnosis ----->cli
- Alcohol detoxification----->peroxisome
- In cns, cell with multiple cytoplasmic process is ----->protoplasmic astrocytes

Cram Statements Inshllah 70 % paper will come from this file. DO not skip this file...



- ✓ Now you can join us Online for MD/MS & Fcps Preparation
- ✓ Complete course in 2months including Past paper discussion
- ✓ Join from anywhere using mobile/laptop using internet
- ✓ 100% feasible with job and 100% time adjustment for students
- ✓ www.fcpsworld.com or Contact 03129684658
- ✓ Hostel Facility is also available (for those who want to join physical classes)



Www.Fcpsworld.com (Institute for Fcps & Md/Ms)

www.facebook.com/FcpsWorld

www.facebook.com/GynaeObsWorld

www.facebook.com/Ophtworld

FILE IS ONLY FOR CLASS STUDENTS (DO NOT SHARE)

Whatsapp 03129684658 to join whatsapp group of your specialty



- ✓ Now you can join us Online for MD/MS & Fcps Preparation
- ✓ Complete course in 2months including Past paper discussion
- ✓ Join from anywhere using mobile/laptop using internet
- ✓ 100% feasible with job and 100% time adjustment for students
- ✓ www.fcpsworld.com or Contact 03129684658
- ✓ Hostel Facility is also available (for those who want to join physical classes)



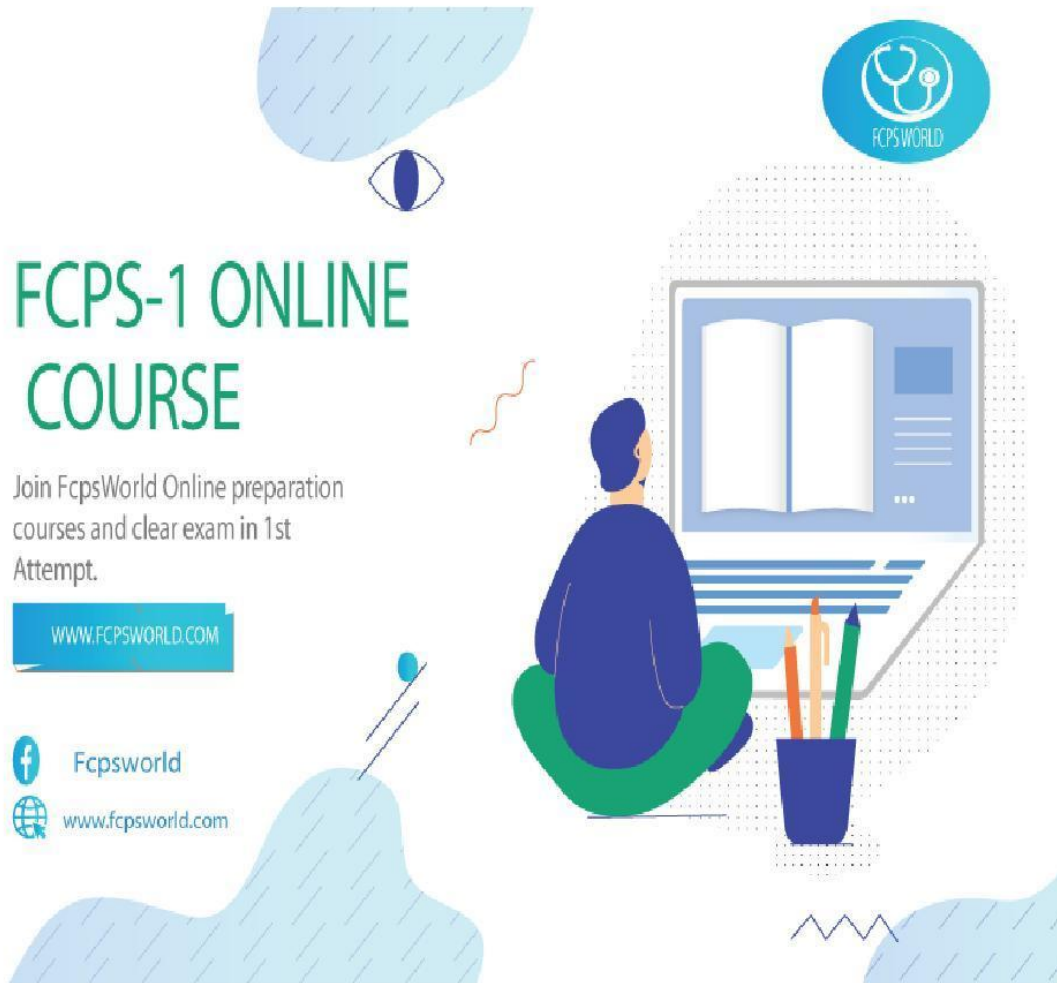Www.Fcpsworld.com (Institute for Fcps & Md/Ms)

www.facebook.com/FcpsWorld

www.facebook.com/GynaeObsWorld

www.facebook.com/Ophtworld

FILE IS ONLY FOR CLASS STUDENTS (DO NOT SHARE)



FCPS-1 ONLINE COURSE

Join FcpsWorld Online preparation courses and clear exam in 1st Attempt.

WWW.FCPSWORLD.COM



Fcpsworld



www.fcpsworld.com



- ✓ Now you can join us Online for MD/MS & Fcps Preparation
- ✓ Complete course in 2months including Past paper discussion
- ✓ Join from anywhere using mobile/laptop using internet
- ✓ 100% feasible with job and 100% time adjustment for students
- ✓ www.fcpsworld.com or Contact 03129684658
- ✓ Hostel Facility is also available (for those who want to join physical classes)



Www.Fcpsworld.com (Institute for Fcps & Md/Ms)

www.facebook.com/FcpsWorld

www.facebook.com/GynaeObsWorld

www.facebook.com/Ophtworld

FILE IS ONLY FOR CLASS STUDENTS (DO NOT SHARE)



GoldStandard

FCPS

- ✓ Feb 2020 papers (recent updated)
- ✓ Authentic most repeated papers.
- ✓ MCQs with explanation and reference.
- ✓ 1 liner for rapid revision. **(Cram them)**
- ✓ Mcqs with explanation and Ref.
- ✓ Clear FCPS-1 in 1st Attempt (Dont miss chance)

✓ Free Cash on Delivery **Order at 03100220370**



- ✓ Now you can join us Online for MD/MS & Fcps Preparation
- ✓ Complete course in 2months including Past paper discussion
- ✓ Join from anywhere using mobile/laptop using internet
- ✓ 100% feasible with job and 100% time adjustment for students
- ✓ www.fcpsworld.com or Contact 03129684658
- ✓ Hostel Facility is also available (for those who want to join physical classes)