

Clear FCPS-1, Md/Ms & PMDC Steps in 1st Attempt. Join FcpsWorld Online Classes & Live lectures.  
(Study Anywhere, Anytime) Join Now!  
[www.fcpsworld.com](http://www.fcpsworld.com)

[www.FcpsWorld.com](http://www.FcpsWorld.com)

# Radiology (Evening)

## Feb 19, 2019



Entire Course will be completed in 2 Months

Online Live lectures via Video Portal

Daily test session (test will be discussed on portal too)

Follow our complete guideline for Fcps-1 & MD/Ms

Get Hands on Leaked pool from CPSP (30,000+) mcqs

Limited seats available

Don't miss the chance

Visit [www.fcpsworld.com](http://www.fcpsworld.com) or contact 03129684658

For More Details Facebook Page: [www.facebook.com/fcpsworld](https://www.facebook.com/fcpsworld)

Join Fcpsworld Online Lectures and Clear exam in 1st Attempt [www.fcpsworld.com](http://www.fcpsworld.com)

Contact# +923129684658

Full Statement CORRECT ANSWERS WITH EXPLANATION Is only for Students Taking Online Classes.

Clear FCPS-1, Md/Ms & PMDC Steps in 1st Attempt. Join FcpsWorld Online Classes & Live lectures.  
(Study Anywhere, Anytime) Join Now!

[www.fcpsworld.com](http://www.fcpsworld.com)

Full Statement CORRECT ANSWERS WITH EXPLANATION Is only for Students  
Taking Online Classes.

## Radiology (19<sup>th</sup> Feb Evening) 1<sup>st</sup> release

[www.fcpsworld.com](http://www.fcpsworld.com)

Facebook page: [facebook.com/fcpsworld](https://facebook.com/fcpsworld)

↑ energy linear acceleration used in- {=X-ray

An absolute contraindication of MRI is - {=Pacemaker#

Contrast used in CT - {=Iodine

In which of the following form of imaging, Harmonic Imaging is related -  
{=Sonography

Ileocecal tuberculosis presents with all except - {=Longitudinal ulcers are more  
common#

For More Details Facebook Page: [www.facebook.com/fcpsworld](https://www.facebook.com/fcpsworld)

Join Fcpsworld Online Lectures and Clear exam in 1st Attempt [www.fcpsworld.com](http://www.fcpsworld.com)

Contact# +923129684658

Full Statement CORRECT ANSWERS WITH EXPLANATION Is only for Students Taking Online Classes.

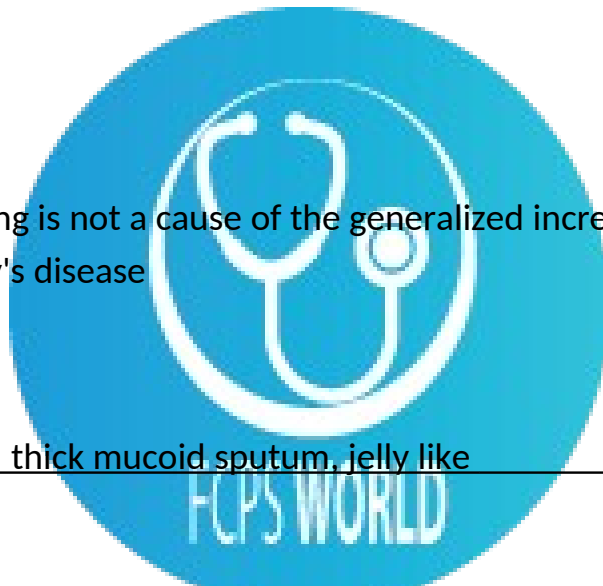
Clear FCPS-1, Md/Ms & PMDC Steps in 1st Attempt. Join FcpsWorld Online Classes & Live lectures.  
(Study Anywhere, Anytime) Join Now!  
[www.fcpsworld.com](http://www.fcpsworld.com)

Investigation of choice in diffuse esophageal spasm is {=Manometry

Colon cut off sign seen in - {=Acute pancreatitis

Millary shadow on chest X-ray is seen in  
TB

Which of the following is not a cause of the generalized increase in bone density  
in adults? {=Caffey's disease



Diabetic patient with thick mucoid sputum, jelly like  
**klebsiella**

- *Streptococcus pneumoniae*: Rust-colored sputum
- *Pseudomonas*, *Haemophilus*, and pneumococcal species: May produce green sputum
- *Klebsiella* species pneumonia: Red currant-jelly sputum
- Anaerobic infections: Often produce foul-smelling or bad-tasting sputum

For More Details Facebook Page: [www.facebook.com/fcpsworld](https://www.facebook.com/fcpsworld)

Join Fcpsworld Online Lectures and Clear exam in 1st Attempt [www.fcpsworld.com](http://www.fcpsworld.com)

Contact# +923129684658

Full Statement CORRECT ANSWERS WITH EXPLANATION Is only for Students Taking Online Classes.

Clear FCPS-1, Md/Ms & PMDC Steps in 1st Attempt. Join FcpsWorld Online Classes & Live lectures.  
(Study Anywhere, Anytime) Join Now!  
[www.fcpsworld.com](http://www.fcpsworld.com)

Neuroectoderm derivative

Ciliary epithelium

Glans and corpora lymph drainage

deep inguinal ring

SMA and IMA anastomose at

marginal artery

Athelete felt pain while running, swollen ankle but can stand.

Plantaris injury

Adductor Canal Pus will damage

femoral vein

Muscle from femur having role in stability of knee joint

Rectus femoris

Lateral movement of Rt eye affected

Cavernous sinus infection

Superior thyroid artery ligation, nerve damaged

For More Details Facebook Page: [www.facebook.com/fcpsworld](https://www.facebook.com/fcpsworld)

Join Fcpsworld Online Lectures and Clear exam in 1st Attempt [www.fcpsworld.com](http://www.fcpsworld.com)

Contact# +923129684658

Full Statement CORRECT ANSWERS WITH EXPLANATION Is only for Students Taking Online Classes.



Clear FCPS-1, Md/Ms & PMDC Steps in 1st Attempt. Join FcpsWorld Online Classes & Live lectures.  
(Study Anywhere, Anytime) Join Now!  
[www.fcpsworld.com](http://www.fcpsworld.com)

external laryngeal

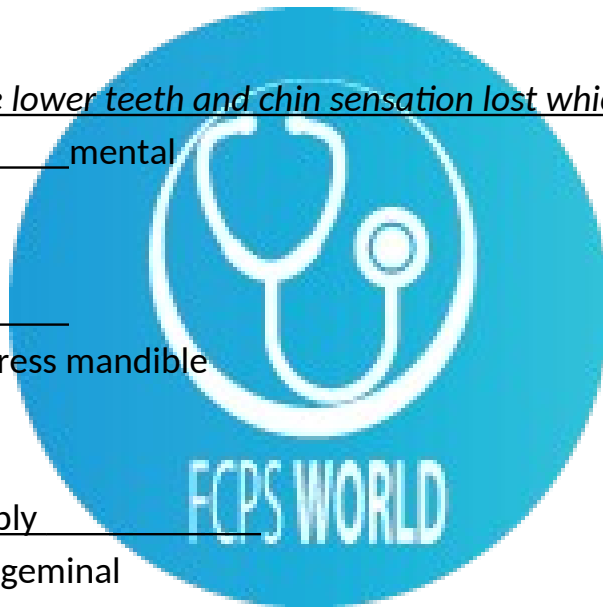
Calories in 100g cereals

350-375

Lower thyroid pole of left lobe surgery, nerve likely damage

recurrent laryngeal

Damage to mandible lower teeth and chin sensation lost which nerve compromised



Geniohyoid

Elevate hyoid or depress mandible

Masseter nerve supply

mandibular br. of trigeminal

Renal functioning in ESRD checked by

Creatinine clearance

Psychological stress example

economic viability

For More Details Facebook Page: [www.facebook.com/fcpsworld](https://www.facebook.com/fcpsworld)

Join Fcpsworld Online Lectures and Clear exam in 1st Attempt [www.fcpsworld.com](http://www.fcpsworld.com)

Contact# +923129684658

Full Statement CORRECT ANSWERS WITH EXPLANATION Is only for Students Taking Online Classes.

) nerve injured in submandibular surgery \_\_\_\_\_  
marginal mandibular br. of facial

Sociology is br. of \_\_\_\_\_  
behav. Science

Prostate drains into \_\_\_\_\_  
internal iliac nodes

Flexion and supination lost, nerve damaged \_\_\_\_\_  
musculocutaneous

index finger flexion lost and lateral palm sensation lost, nerve damaged \_\_\_\_\_  
\_\_\_\_\_  
median

Ca tongue on ant. 2/3rd and on Left lateral side, will drain first to \_\_\_\_\_  
\_\_\_\_\_

Lady with pallor and weakness, low MCV, taste changes, eggs in stool \_\_\_\_\_


anylostoma duodenale

For More Details Facebook Page: [www.facebook.com/fcpsworld](https://www.facebook.com/fcpsworld)

Join Fcpsworld Online Lectures and Clear exam in 1st Attempt [www.fcpsworld.com](http://www.fcpsworld.com)

Contact# +923129684658

Full Statement CORRECT ANSWERS WITH EXPLANATION Is only for Students Taking Online Classes.



Clear FCPS-1, Md/Ms & PMDC Steps in 1st Attempt. Join FcpsWorld Online Classes & Live lectures.  
(Study Anywhere, Anytime) Join Now!  
[www.fcpsworld.com](http://www.fcpsworld.com)

A light hookworm infection causes abdominal pain, loss of appetite, and geophagy. Heavy infection causes severe protein deficiency or iron-deficiency anemia. Protein deficiency may lead to dry skin, edema, and abdominal extension from edema (potbelly), while iron-deficiency anemia might result in mental dullness and heart failure. Women who are pregnant and infected should be aware that this parasite is able to infect the fetus and can cause complications such as low birth weight, maternal anemia, and infant mortality.[5]

pain in appendicitis is caused by \_\_\_\_\_

Bradykinin and prostaglandins causes contraction of non-vascular smooth muscle in the bronchus and gut, increases vascular permeability and is also involved in the mechanism of pain

Transfusion reaction within 15 minutes, causing dyspnea and fever

type1

Transfusion reaction within 10 minutes heavy chest , dyspnea, critical. died on 3rd day

ABO incompatibility

ABO incompatibility is one of the diseases which can cause jaundice. ABO incompatibility happens when a mother's blood type is O, and her baby's blood type is A or B. The mother's immune system may react and make antibodies against her baby's red blood cells.

Old man with pallor and jaundice, blood transfusion given, complained of dark colour urine afterward \_\_\_\_\_

hemolytic reaction

For More Details Facebook Page: [www.facebook.com/fcpsworld](https://www.facebook.com/fcpsworld)

Join Fcpsworld Online Lectures and Clear exam in 1st Attempt [www.fcpsworld.com](http://www.fcpsworld.com)

Contact# +923129684658

Full Statement CORRECT ANSWERS WITH EXPLANATION Is only for Students Taking Online Classes.

Clear FCPS-1, Md/Ms & PMDC Steps in 1st Attempt. Join FcpsWorld Online Classes & Live lectures.  
(Study Anywhere, Anytime) Join Now!  
[www.fcpsworld.com](http://www.fcpsworld.com)

A hemolytic transfusion reaction is a serious complication that can occur after a blood transfusion. The reaction occurs when the red blood cells that were given during the transfusion are destroyed by the person's immune system. There are other types of allergic transfusion reactions that do not cause hemolysis

### Medial rotation of foot lost

tibialis anterior and tibialis post. muscle weakness.  
tibialis anterior muscles responsible for dorsiflexing and inverting the foot. tibialis posterior is key muscle and tendon for stabilization, the tibialis posterior also contracts to produce inversion and assists in the plantar flexion of the foot at the ankle.

### carcinoma of ant 2/3 lateral of tongue will drain into submandibular LN

The afferents of the submandibular glands drain the medial canthus, the cheek, the side of the nose, the upper lip, the lateral part of the lower lip, the gums, and the anterior part of the margin of the tongue.

### Washed RBCs for

to prevent hypersensitive reaction

Washed red blood cells are red blood cells which have had most of the plasma, platelets and white blood cells removed and replaced with saline or another type of preservation solution

### ligamentum arteriosum extends

left pulm artery to arch of aorta

For More Details Facebook Page: [www.facebook.com/fcpsworld](https://www.facebook.com/fcpsworld)

Join Fcpsworld Online Lectures and Clear exam in 1st Attempt [www.fcpsworld.com](http://www.fcpsworld.com)

Contact# +923129684658

Full Statement CORRECT ANSWERS WITH EXPLANATION Is only for Students Taking Online Classes.



Clear FCPS-1, Md/Ms & PMDC Steps in 1st Attempt. Join FcpsWorld Online Classes & Live lectures.  
(Study Anywhere, Anytime) Join Now!  
[www.fcpsworld.com](http://www.fcpsworld.com)

The ligamentum arteriosum is a small ligament that is the remnant of the ductus arteriosus formed within three weeks after birth. At the superior end, the ligamentum attaches to the aorta—at the final part of the aortic arch (the isthmus of aorta) or the first part of the descending aorta.[1] On the other, inferior end, the ligamentum is attached to the top of the left pulmonary artery

Hyperflexion of neck, ligament damaged

ligamentum nuchae

The ligamentum nuchae is a large median ligament composed of tendons and fascia located between the posterior muscles of the neck. It covers the spines of C1 to C6 vertebrae. It is a superior and posterior extension of the supraspinous ligament.

Cut at anatomical snuff box, profuse bleeding, artery damage

radial

Spinal ganglia sensory neuron type

pseudounipolar

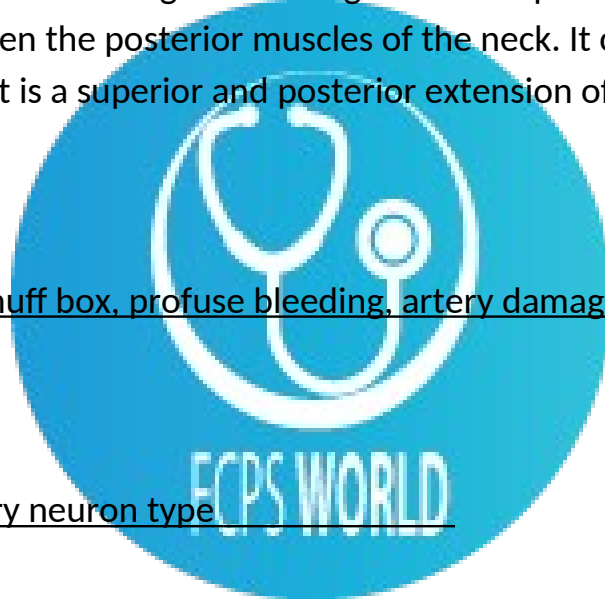
In the dorsal root ganglia: The soma (cell body) of each pseudounipolar neuron is located within a dorsal root ganglion. In the sensory ganglia of cranial nerves Pseudounipolar neurons are also found in the sensory ganglia of cranial nerves V, VII, IX and X, all mixed-cranial nerves. The vestibulocochlear nerve, has the bipolar neuron type in both the spiral ganglion as well as Scarpa's ganglion.

For More Details Facebook Page: [www.facebook.com/fcpsworld](https://www.facebook.com/fcpsworld)

Join Fcpsworld Online Lectures and Clear exam in 1st Attempt [www.fcpsworld.com](http://www.fcpsworld.com)

Contact# +923129684658

Full Statement CORRECT ANSWERS WITH EXPLANATION Is only for Students Taking Online Classes.



Lateral forearm injury, unable to extend and abduct thumb but sensations intact

deep branch of radial

The deep branch of the radial nerve winds to the back of the forearm around the lateral side of the radius between the two planes of fibers of the Supinator, and is prolonged downward between the superficial and deep layers of muscles, to the middle of the forearm. The deep branch provides motor function to the muscles in the posterior compartment of the forearm, which is mostly the extensor muscles of the hand.

Aspirin toxicity, what to give

bicarbs

asprin The principal toxic manifestations of respiratory alkalosis and metabolic acidosis

obstetrician reluctant for median episiotomy due to risk

Ext.anal sphincter damage

The median episiotomy incision is made in the perineal body from the midline of the hymenal ring through the connective tissue that unites the bulbocavernosus muscle, the superficial transverse perineal muscles, and the perineal membrane (urogenital diaphragm).

Epithelium modification in small intestine

microvilli

Diabetic with pinpoint pupil and ptosis on right side

Horners syndrome

For More Details Facebook Page: [www.facebook.com/fcpsworld](https://www.facebook.com/fcpsworld)

Join Fcpsworld Online Lectures and Clear exam in 1st Attempt [www.fcpsworld.com](http://www.fcpsworld.com)

Contact# +923129684658

Full Statement CORRECT ANSWERS WITH EXPLANATION Is only for Students Taking Online Classes.

Clear FCPS-1, Md/Ms & PMDC Steps in 1st Attempt. Join FcpsWorld Online Classes & Live lectures.  
(Study Anywhere, Anytime) Join Now!  
[www.fcpsworld.com](http://www.fcpsworld.com)

Horner syndrome is a relatively rare disorder characterized by a constricted pupil (miosis), drooping of the upper eyelid (ptosis), absence of sweating of the face (anhidrosis), and sinking of the eyeball into the bony cavity that protects the eye (enophthalmos). These are the four classic signs of the disorder.

Ant. relation of hilum of Rt kidney

Second part of duodenum

True about right lung

Azygous in direct relation

Hamiballismus is seen in lesion of

subthalamic nucleus

Ballismus or ballism (called hemiballismus or hemiballism in its unilateral form) is a very rare movement disorder. It is a type of chorea caused in most cases by a decrease in activity of the subthalamic nucleus of the basal ganglia, resulting in the appearance of flailing, ballistic, undesired movements of the limbs.[1]

Resp. DNA virus

adeno v

Adenovirus causes only mild respiratory, ocular, and enteric diseases to human.

Nucleus ambiguus contain

9,10,11

This nucleus gives rise to the branchial efferent motor fibers of the vagus nerve (CN X) terminating in the laryngeal, pharyngeal muscles, and musculus

For More Details Facebook Page: [www.facebook.com/fcpsworld](https://www.facebook.com/fcpsworld)

Join Fcpsworld Online Lectures and Clear exam in 1st Attempt [www.fcpsworld.com](http://www.fcpsworld.com)

Contact# +923129684658

Full Statement CORRECT ANSWERS WITH EXPLANATION Is only for Students Taking Online Classes.

Clear FCPS-1, Md/Ms & PMDC Steps in 1st Attempt. Join FcpsWorld Online Classes & Live lectures.  
(Study Anywhere, Anytime) Join Now!  
[www.fcpsworld.com](http://www.fcpsworld.com)

uvulae[citation needed]; as well as to the efferent motor fibers of the glossopharyngeal nerve (CN IX) terminating in the stylopharyngeus muscle.

Deviation of tongue on protrusion, damage to \_\_\_\_\_

hypoglossal N

The hypoglossal nerve is the twelfth cranial nerve, and innervates all the extrinsic and intrinsic muscles of the tongue, except for the palatoglossus which is innervated by the vagus nerve.

Portal vein Ascend to liver in \_\_\_\_\_

lesser omentum

Type 2 DM in elderly (NIDDM), what to give \_\_\_\_\_

Tolbutamide

metformin cause weight loss

Greenish vaginal discharge, trophozoit seen \_\_\_\_\_

Trichomonas vaginalis

green characteristic

Behind sternum vertically seen \_\_\_\_\_

Int. thoracic artery

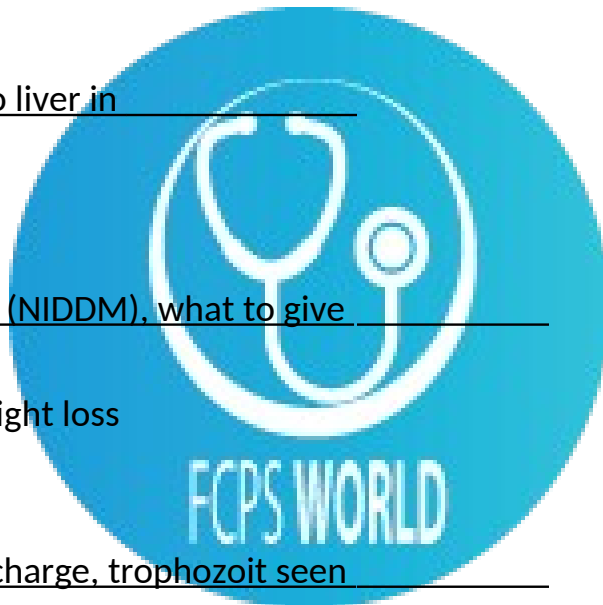
internal thoracic artery (ITA), previously known as the internal mammary artery (a name still common among surgeons[citation needed]), is an artery that supplies the anterior chest wall and the breasts. It is a paired artery, with one running

For More Details Facebook Page: [www.facebook.com/fcpsworld](https://www.facebook.com/fcpsworld)

Join Fcpsworld Online Lectures and Clear exam in 1st Attempt [www.fcpsworld.com](http://www.fcpsworld.com)

Contact# +923129684658

Full Statement CORRECT ANSWERS WITH EXPLANATION Is only for Students Taking Online Classes.



Clear FCPS-1, Md/Ms & PMDC Steps in 1st Attempt. Join FcpsWorld Online Classes & Live lectures.  
(Study Anywhere, Anytime) Join Now!  
[www.fcpsworld.com](http://www.fcpsworld.com)

along each side of the sternum, to continue after its bifurcation as the superior epigastric and musculophrenic arteries.

NOF (intracapsular) in elder, most likely will be seen

Avascular necrosis

Slow growing thyroid tumor

Papillary

Papillary thyroid cancer or papillary thyroid carcinoma[1] is the most common type of thyroid cancer is often well-differentiated, slow-growing, and localized, although it can metastasize.

in new born what will be present

C shaped vertebral column

When baby is first born, his spine will have a convex curve in the shape of the letter C. This spinal alignment is called the primary curve and develops in utero. Your newborn does not yet have the muscle strength to hold up his head and needs to be carried carefully with his head and neck fully supported

Adneocarcinoma related to

barret esophagus

The incidence of esophageal adenocarcinoma has increased substantially in the Western world in recent years.

CKD patient having MCV 86fl , anemia seen

normochromic normocytic

For More Details Facebook Page: [www.facebook.com/fcpsworld](https://www.facebook.com/fcpsworld)

Join Fcpsworld Online Lectures and Clear exam in 1st Attempt [www.fcpsworld.com](http://www.fcpsworld.com)

Contact# +923129684658

Full Statement CORRECT ANSWERS WITH EXPLANATION Is only for Students Taking Online Classes.

### Ghon complex

TB

Ghon's complex is a lesion seen in the lung that is caused by tuberculosis. The lesions consist of a calcified focus of infection and an associated lymph node.

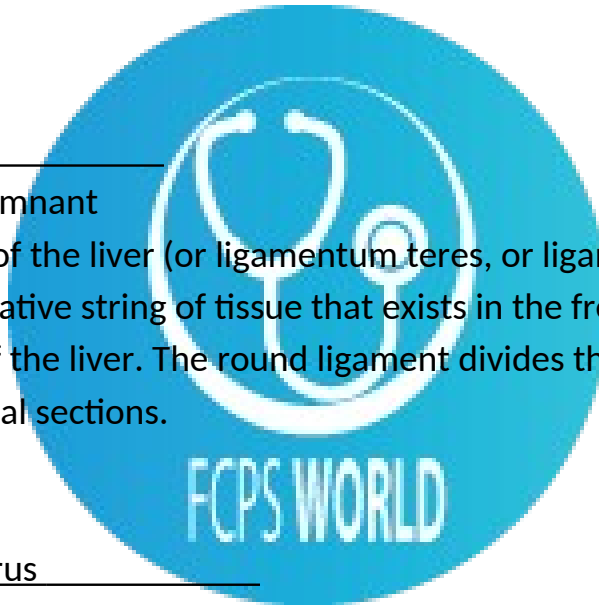
### Hypertrophy and hyperplasia concomitantly seen in

Uterus in pregnancy

### Ligamentum teres

Left umbilical vein remnant

The round ligament of the liver (or ligamentum teres, or ligamentum teres hepatis) is a degenerative string of tissue that exists in the free edge of the falciform ligament of the liver. The round ligament divides the left part of the liver into medial and lateral sections.



### Main Support of uterus

Transverse cervical ligament

is a major ligament of the uterus. It is located at the base of the broad ligament of the uterus. ... Additionally, it carries the uterine arteries to provide the primary blood supply to the uterus.

### 9 month old japanese boy having aneurysm

kawasaki

Kawasaki disease, also known as mucocutaneous lymph node syndrome, is a disease in which blood vessels throughout the body become inflamed.

For More Details Facebook Page: [www.facebook.com/fcpsworld](https://www.facebook.com/fcpsworld)

Join Fcpsworld Online Lectures and Clear exam in 1st Attempt [www.fcpsworld.com](http://www.fcpsworld.com)

Contact# +923129684658

Full Statement CORRECT ANSWERS WITH EXPLANATION Is only for Students Taking Online Classes.

Telomerase seen in

Germ cells

Telomerase is a reverse transcriptase which is used as a template when it elongates telomeres. Telomerase is active in normal stem cells and most cancer cells, but is normally absent from, or at very low levels in, most somatic cells.

Chest pain not related to respiration

myocardium

Alcohol detoxification

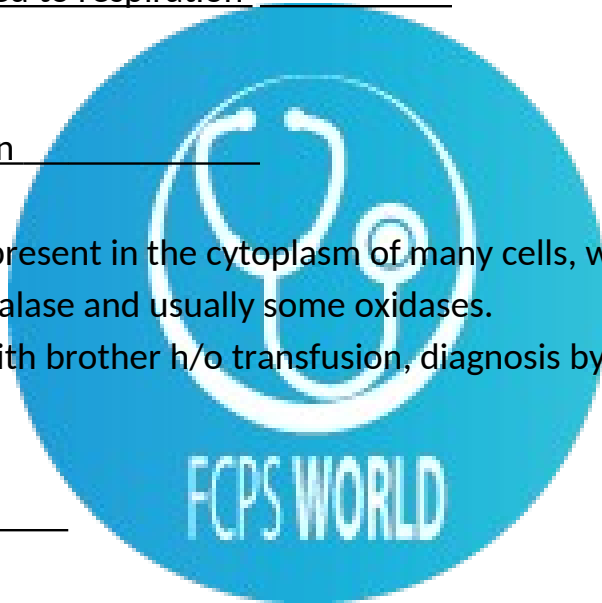
peroxisomes

1. a small organelle present in the cytoplasm of many cells, which contains the reducing enzyme catalase and usually some oxidases.

microcytic anemia with brother h/o transfusion, diagnosis by

HB electrophoresis

thalassemia?



Inc. V/Q ratio in

dead space

Alveolar dead space is sum of the volumes of those alveoli which have little or no blood flowing through their adjacent pulmonary capillaries, i.e., alveoli that are ventilated but not perfused, and where, as a result, no gas exchange can occur.

For More Details Facebook Page: [www.facebook.com/fcpsworld](https://www.facebook.com/fcpsworld)

Join Fcpsworld Online Lectures and Clear exam in 1st Attempt [www.fcpsworld.com](http://www.fcpsworld.com)

Contact# +923129684658

Full Statement CORRECT ANSWERS WITH EXPLANATION Is only for Students Taking Online Classes.

Clear FCPS-1, Md/Ms & PMDC Steps in 1st Attempt. Join FcpsWorld Online Classes & Live lectures.  
(Study Anywhere, Anytime) Join Now!  
[www.fcpsworld.com](http://www.fcpsworld.com)

Lytic lesions and backache are common features of multiple myeloma. Which is best test for diagnosis

Protein electrophoresis

Before C. section H2 blockers given to

decrease volume and acid

Local anesthesia

block NA channel

MCV inc., hypersegmented neutrophils

pernicious anemia

Pernicious anemia is a decrease in red blood cells that occurs when the intestines cannot properly absorb vitamin B12.

MAO of V. cholera

V. cholerae pathogenicity genes code for proteins directly or indirectly involved in the virulence of the bacteria. During infection, V. cholerae secretes cholera toxin, a protein that causes profuse, watery diarrhea (known as "rice-water stool"). Colonization of the small intestine also requires the toxin coregulated pilus (TCP), a thin, flexible, filamentous appendage on the surface of bacterial cells. V. cholerae can cause syndromes ranging from asymptomatic to cholera gravis

Patyasma supply

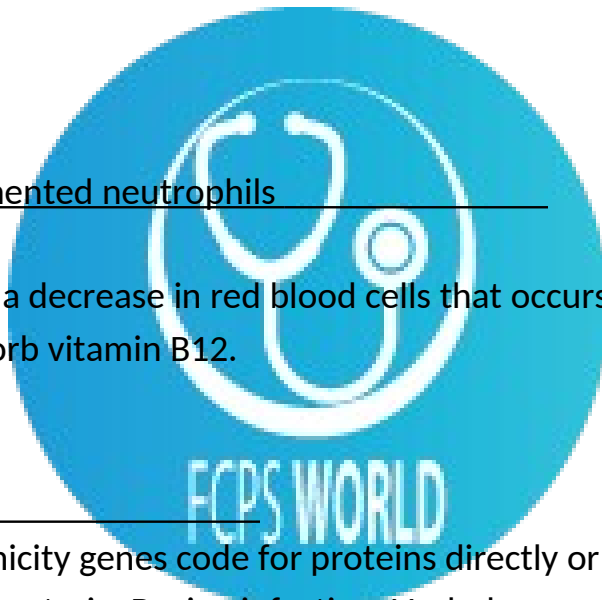
facial N

For More Details Facebook Page: [www.facebook.com/fcpsworld](https://www.facebook.com/fcpsworld)

Join Fcpsworld Online Lectures and Clear exam in 1st Attempt [www.fcpsworld.com](http://www.fcpsworld.com)

Contact# +923129684658

Full Statement CORRECT ANSWERS WITH EXPLANATION Is only for Students Taking Online Classes.





most common primary bone tumor in second decade

osteosarcoma

Osteosarcoma is a type of cancer that produces immature bone. It is the most common type of cancer that arises in bones, and it is usually found at the end of long bones, often around the knee. Most people diagnosed with osteosarcoma are under the age of 25, and it is thought to occur more often in males than females.


Max. inspiration + normal expiration

Insp. Capacity

Shoulder tip is supplied by  
phrenic nerve

Above L4 is given

Above L4



On barium meal, feather shaped on left side of abdomen

Jejunum

Left coronary artery

supplies Bundle of HIS

For More Details Facebook Page: [www.facebook.com/fcpsworld](https://www.facebook.com/fcpsworld)

Join Fcpsworld Online Lectures and Clear exam in 1st Attempt [www.fcpsworld.com](http://www.fcpsworld.com)

Contact# +923129684658

Full Statement CORRECT ANSWERS WITH EXPLANATION Is only for Students Taking Online Classes.

Clear FCPS-1, Md/Ms & PMDC Steps in 1st Attempt. Join FcpsWorld Online Classes & Live lectures.  
(Study Anywhere, Anytime) Join Now!  
[www.fcpsworld.com](http://www.fcpsworld.com)

Defecation reflex

relaxation of internal anal sphincter

Superior radioulnar joint

pivot

Old patient had surgery, now pale, abdomen distended, low BP

hypovolumic shock

Galactosemia occurs due to deficiency of

Galactose 1 phosphate uridylyltransferase  
responsible for converting ingested galactose to glucose

Early sign of reversible cell injury

ER swelling

Feature of auto immune disease

Arthritis

Allopurinol

Xanthine oxidase inhibitor

Oral anticoagulant, monitoring by

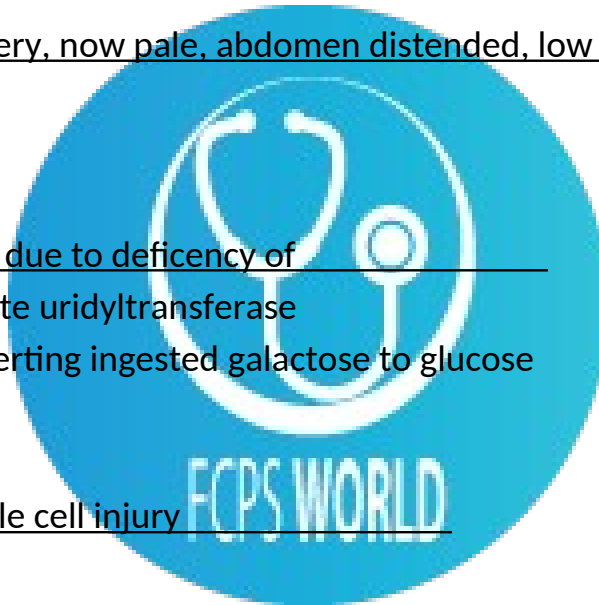
PT

For More Details Facebook Page: [www.facebook.com/fcpsworld](https://www.facebook.com/fcpsworld)

Join Fcpsworld Online Lectures and Clear exam in 1st Attempt [www.fcpsworld.com](http://www.fcpsworld.com)

Contact# +923129684658

Full Statement CORRECT ANSWERS WITH EXPLANATION Is only for Students Taking Online Classes.



Clear FCPS-1, Md/Ms & PMDC Steps in 1st Attempt. Join FcpsWorld Online Classes & Live lectures.  
(Study Anywhere, Anytime) Join Now!  
[www.fcpsworld.com](http://www.fcpsworld.com)

parasite in Raw undercooked meat

Tapeworm

Most abundant Immunoglobulins in adults

IgG

Plastic factory worker, exposed to hydrocarbons is prone to

broncogenic CA

Energy in excess of resting during contraction

Shortening heat

Shortening heat is defined as the difference in twitch heat between these two modes of contractions at a given afterload.

Relation of pituitary

Lateral cavernous sinus

For More Details Facebook Page: [www.facebook.com/fcpsworld](https://www.facebook.com/fcpsworld)

Join Fcpsworld Online Lectures and Clear exam in 1st Attempt [www.fcpsworld.com](http://www.fcpsworld.com)

Contact# +923129684658

Full Statement CORRECT ANSWERS WITH EXPLANATION Is only for Students Taking Online Classes.

